

Case Report

Primary intra osseous venous malformation of nasal bone: A rare case report

Ajit Kumar Pati, Bibhuti Bhusan Nayak, Arun Kumar Choudhury, Debesh Kumar Rout

Department of Plastic Surgery, S.C.B. Medical College, Cuttack, Odisha, India

Address for correspondence: Dr. Ajit Kumar Pati, Department of Plastic Surgery, S.C.B. Medical College, Cuttack, Odisha, India.

E-mail: dr_ajitpati@yahoo.com

ABSTRACT

Primary intra osseous venous malformation with involvement of nasal bone is a rare phenomenon. Nasal bone intraosseous venous malformation on a back ground of port wine stain of face has not been reported in the available literature. We report the very rare case of intraosseous venous malformation of left nasal bone developing on a background of port wine stain of face, its diagnosis, pathology, management and review of literature.

KEY WORDS

Intraosseous venous malformation; nasal bone; port wine stain; sun burst appearance

INTRODUCTION

Intraosseous vascular malformation are uncommon, constituting <1% of all osseous tumors. The most frequent sites are the calvaria and the vertebral column. Involvement of the facial bones is rare, and occurs most commonly in the maxilla, mandible, and nasal bones.^[1] So far only 26 nasal bone vascular malformations have been described in the literature,^[2] however not a single case of intraosseous venous malformation in the background of port wine stain of face is available in the reported literature.

CASE REPORT

A 14-year-old girl presented with a port wine patch on the left side of face mainly over the lateral side of nose and nasolabial fold and malar area which was present

since birth and was gradually increasing in size as the child grew. In the last 3 months period, she complained of appearance of a globular swelling on left lateral side of nose which rapidly increased in size resulting in bulky appearance of upper part of nose and slight deviation of nose to right side. Simultaneously two warty growths appeared on left ala and cheek which gradually increased in size [Figure 1]. There was no history of trauma to the area. There were no complain of pain or tenderness, or respiratory difficulty. Examination revealed a globular swelling of size 7 cm × 5 cm, with smooth surface, bony hard consistency, nonpulsatile, noncompressible, no palpable thrill or audible bruit, no fluctuation, not increasing in size with coughing, without local rise of temperature, with an area of port wine stain on the left side of nose and nasolabial fold area overlying the swelling.

CT scan showed an avidly enhancing soft tissue density lesion with bone density within it with “sun burst appearance” from left nasal bone [Figure 2].

The lesion was approached through an incision along the nasolabial fold slightly extending over the dorsum of nose.

Access this article online	
Quick Response Code:	Website: www.ijps.org
	DOI: 10.4103/0970-0358.146631

A well circumscribed bony growth was found within the left nasal bone. The swelling was gently dissected of the nasal bone which had a vascular stalk attached to the nasal mucosa which was ligated. Then the lesion could be completely enucleated and had a honeycomb appearance [Figure 3]. Rest of the nearby bony growths was chisselled out and hemostasis achieved with electrocautery. Wound was closed with subcuticular suturing and pressure dressing applied.

Histopathology revealed large vascular spaces with endothelial lining giving the impression of venous channels, with scattered osteocytes surrounding the spaces [Figure 4]. The postoperative course was uneventful, and there was no evidence of recurrence at 3 months follow-up [Figure 5].

DISCUSSION

Primary intraosseous vascular malformation are rare, benign, slow-growing vascular neoplasms accounting

for only 0.7% of all primary bone tumors.^[3] 50% are found in the vertebra or skull. When they arise within the calvaria, they are normally confined to the frontal or parietal bones. These lesions are usually solitary and occur more frequently in females than males. They are typically found in adults, although persons of any age may be affected. They are classified as benign, but rarely may be locally aggressive. The intraosseous location of venous malformations is notable in comparison with hemangiomas, which do not occur within osseous structures, as was previously thought.^[4] Lesions previously described as “intraosseous hemangiomas” are now pathologically known by their lack of GLUT1 to be venous malformations.^[5]

Intraosseus vascular malformation of the nasal bone are extremely rare. In a series of 45 patients with vascular malformation of bone, Sherman and Wilner found one involving the nasal bone.^[6,7] Osborn reviewed over 50 patients with nasal haemangiomas over a 11 years period and none involved the nasal bone.^[6,8] The first report was written by Nievert and Bitchick and review of the subject was undertaken by Bridger.^[6,9,10] Intraosseus venous malformation of the nasal bone

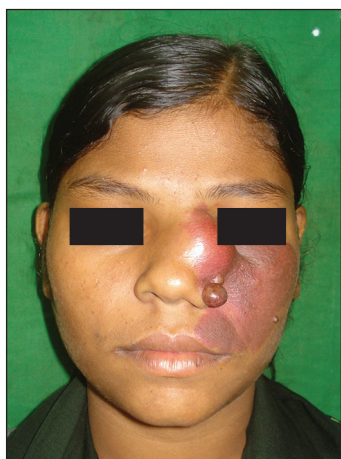

Figure 1: Frontal view of the patient

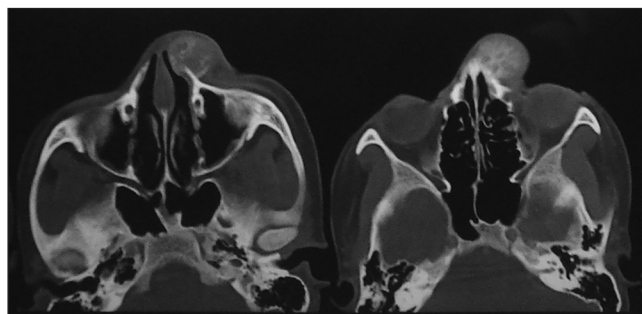


Figure 2: Computed tomography scan showing “sun burst appearance”

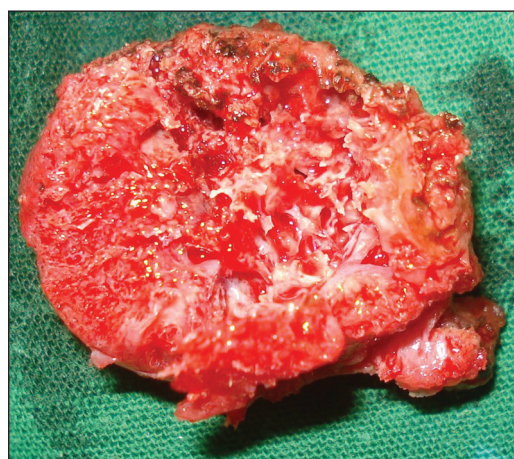


Figure 3: Honey comb nature of bone

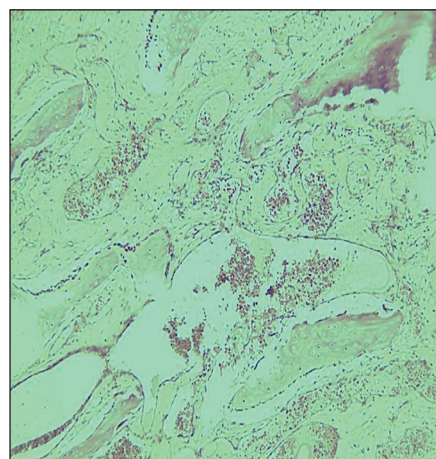


Figure 4: Histopathology showing cavernous spaces surrounded by osteocytes (H and E, ×40)

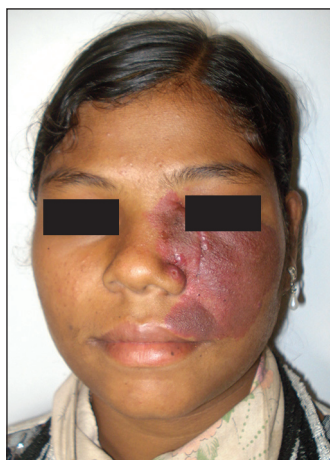

Figure 5: Postoperative view

characteristically presents as a slowly enlarging mass at the root of the nose and usually reaches a maximum size of 2 cm at time of diagnosis.^[6,11] However, this patient had a lesion measuring 7 cm in the largest dimension. Usually they are unilateral and are asymptomatic, affecting young and middle age group. In contrast to soft tissue venous malformation, which are most common in children, osseous venous malformation are more common in older populations.^[2,11] The most common sites for nasal venous malformation are the nasal septum (65%), lateral wall (18%), and vestibule (16%).^[11] In this case, the lesion was arising from the lateral wall.

The aetiology of intraosseous venous malformation is unclear. Local trauma and menopause are proposed causes although not proven.^[12] It shows increased vascularity in the tumor area.

Histological sub types

According to Madge *et al.*, the most common periorbital vascular malformation are the cavernous type (80%), followed by the capillary (17%) and mixed varieties (3%).^[13]

Histologically demonstrates hamartomatous vascular tissue within endothelium, but may also contain fat, smooth muscle, fibrous tissue, and thrombus.

Radiographic features

Plain film

Plain radiographs are usually first line and may be sufficient in vertebra or calvarial lesions. Findings include: Prominent trabecular pattern, sclerotic vertebra with vertical trabeculae: Corduroy sign, lytic calvarial lesions

with spoke-wheel appearance, irregular and lytic in long bones, with a honeycomb appearance.

Computed tomography

Computed tomography is considered the most useful imaging technique because of its excellent characterization of trabecular and cortical detail. The CT appearance is variable, and in the calvaria most commonly shows a characteristic sharply marginated expansile lesion with intact inner and outer tables and a sunburst pattern of radiating trabeculae. "Soap bubble" and "honeycomb" configurations may also occur.^[1]

Magnetic resonance imaging

Signal intensity is somewhat variable, depending largely on the amount of fat content.

T1: High is more common (fat rich), intermediate to low signal intensity is seen in fat poor haemangiomas, T2: High, T1 C + Gd: Enhancement is often present.

Magnetic resonance imaging is the ideal modality to demonstrates many mass-effect complications, such as neural impingement and extraosseous extension.

Bone scan

Usually normal but may show increased or decreased uptake.

Treatment

Treatment modalities include surgery, radiotherapy, sclerotherapy, and embolization. Complete surgical excision is mainstay of treatment and also plays a role in definite diagnosis. Although radiotherapy is a good treatment choice for hemangiomas, long-term side effects, such as malignancy, region growth impairment, and scarring, make it an unfavorable treatment modality. Therefore, radiotherapy is only used for unresectable lesions. Transarterial embolization and sclerotherapy can be used but these are palliative procedures.

SUMMARY

Intranasal venous malformation because of its unusual site and masked presentation makes the differential diagnosis difficult. When a bony hard, well-shaped mass was seen in the nasal cavity, the possibility of intraosseous venous malformation must be remembered.

REFERENCES

1. Moore SL, Chun JK, Mitre SA, Som PM. Intraosseous hemangioma of the zygoma: CT and MR findings. *AJNR Am J Neuroradiol* 2001;22:1383-5.
2. Zins JE, Türegün MC, Hosn W, Bauer TW. Reconstruction of intraosseous hemangiomas of the midface using split calvarial bone grafts. *Plast Reconstr Surg* 2006;117:948-53.
3. Takeda K, Takenaka Y, Hashimoto M. Intraosseous hemangioma of the inferior turbinate. *Case Rep Med* 2010;2010:409429.
4. Greene AK, Rogers GF, Mulliken JB. Intraosseous "hemangiomas" are malformations and not tumors. *Plast Reconstr Surg* 2007;119:1949-50.
5. Bruder E, Perez-Atayde AR, Jundt G, Alomari AI, Rischewski J, Fishman SJ, et al. Vascular lesions of bone in children, adolescents, and young adults. A clinicopathologic reappraisal and application of the ISSVA classification. *Virchows Arch* 2009;454:161-79.
6. Ashoor A, Baker YA. Intraosseous haemangioma of the nasal bone. *Bahrain Med Bull* 2002;24:32-3.
7. Sherman RS, Wilner D. The roentgen diagnosis of hemangioma of bone. *Am J Roentgenol Radium Ther Nucl Med* 1961;86:1146-59.
8. Osborn DA. Haemangiomas of the nose. *J Laryngol Otol* 1959;73:174-9.
9. Bridger MW. Haemangioma of the nasal bones. *J Laryngol Otol* 1976;90:191-200.
10. Nievert H, Bitchick EB. Primary haemangioma of the nasal bone. *Arch Otolaryngol* 1936;24:495-501.
11. McAllister RM, Ruttly GN, Hancock K, Sanders R. Cavernous haemangioma of the nasal bones. *J Laryngol Otol* 1992;106:264-7.
12. Caylakli F, Cagici AC, Hürkan C, Bal N, Kizilkiliç O, Kiroglu F. Cavernous hemangioma of the middle turbinate: A case report. *Ear Nose Throat J* 2008;87:391-3.
13. Madge SN, Simon S, Abidin Z, Ghabrial R, Davis G, McNab A, et al. Primary orbital intraosseous hemangioma. *Ophthal Plast Reconstr Surg* 2009;25:37-41.

How to cite this article: Pati AK, Nayak BB, Choudhury AK, Rout DK. Primary intra osseous venous malformation of nasal bone: A rare case report. *Indian J Plast Surg* 2014;47:423-6.

Source of Support: Nil, **Conflict of Interest:** None declared.

Announcement

iPad App



Indian Journal of Plastic Surgery (IJPS) launches a dynamic app which optimizes the best in digital technology to enhance a print-like reading experience with multimedia links, videos and more.

- View abstracts, read full text, browse and get engaged in multimedia
- Complete content of each issue enhanced with iPad functionality
- Customized functions like search within an article and across the downloaded issues; highlight text and mark article as favorite
- Receive new issue notifications; convenient notification when a new issue is available

How to launch the app?

- Use the QR code
- Visit the App Store on your iPad and search for IJPS
- Download it from <https://itunes.apple.com/in/app/indian-journal-plastic-surgery/id726088047>

