

Original Article

Options for the nasal repair of non-syndromic unilateral Tessier no. 2 and 3 facial clefts

Srinivas Gosla Reddy¹, Rajgopal R. Reddy¹, Joachim Obwegeser², Maurice Y. Mommaerts³

¹GSR Institute of Craniofacial Surgery, Hyderabad, Telangana, India, ²Children Hospital Zurich, University Zurich, Zurich, Switzerland, ³Bruges Cleft and Craniofacial Centre, GH St. Jan, Bruges, Belgium

Address for correspondence: Dr. Srinivas Gosla Reddy, GSR Institute of Craniofacial Surgery, 17-1-383/55, Vinaynagar Colony, I.S. Sadan, Saidabad, Hyderabad - 500 059, Andhra Pradesh, India. E-mail: gosla@craniofacialinstitute.org

ABSTRACT

Background: Non-syndromic Tessier no. 2 and 3 facial clefts primarily affect the nasal complex. The anatomy of such clefts is such that the ala of the nose has a cleft. Repairing the ala presents some challenges to the surgeon, especially to correct the shape and missing tissue. Various techniques have been considered to repair these cleft defects. **Aim:** We present two surgical options to repair such facial clefts. **Materials and Methods:** A nasal dorsum rotational flap was used to treat patients with Tessier no. 2 clefts. This is a local flap that uses tissue from the dorsal surface of the nose. The advantage of this flap design is that it helps move the displaced ala of a Tessier no. 2 cleft into its normal position. A forehead-eyelid-nasal transposition flap design was used to treat patients with Tessier no. 3 clefts. This flap design includes three prongs that are rotated downward. A forehead flap is rotated into the area above the eyelid, the flap from above the eyelid is rotated to infra-orbital area and the flap from the infraorbital area that includes the free nasal ala of the cleft is rotated into place. **Results and Conclusions:** These two flap designs show good results and can be used to augment the treatment options for repairing Tessier no. 2 and 3 facial clefts.

KEY WORDS

Facial clefts; Tessier clefts; Tessier no. 2 cleft; Tessier no. 3 cleft

INTRODUCTION

A facial cleft is the result of a partially or totally missing fusion of the embryonal craniofacial tissue. The severity of the deformity can range from slight skin excavation and hair loss to wry mouth, skewed eyes and the absence of nose and face, seriously impairing the patient's appearance and function.^[1]

Facial clefts are usually found along the lines of fusion of the different embryonic processes responsible for the development of the face during the first 8 weeks of embryonic life.^[2]

The incidence of these craniofacial malformations is higher in cleft lip, alveolus and palate patients (31: 1000 facial clefts/cleft lip and palate) than in people without cleft lip, alveolus and palate.^[2] Facial clefts have been classified according to pathology, aetiology, pathomorphology, topographic anatomy and at the time of development.^[1,3] Tessier's anatomically based classification is, presently, almost universally used by craniofacial surgeons.^[4] Tessier no. 2 and 3 facial clefts are lateral nasal clefts that are located at the junction between the products of the median and lateral nasal processes.^[1]

Access this article online	
Quick Response Code: 	Website: www.ijps.org
	DOI: 10.4103/0970-0358.146588

MATERIALS AND METHODS

Nasal dorsum rotational flaps (NDRF) were used to treat six patients with Tessier no. 2 facial clefts. Forehead-eyelid-nasal transposition flaps (FENTF) were used to treat three patients with Tessier no. 3 facial clefts. These incision designs were followed only on patients that had isolated non-syndromic unilateral Tessier no. 2 and 3 facial clefts. These incision designs were used only to correct the nasal defects. All other bony defects were planned and/or corrected at a later stage. All the surgeries were performed between August 1, 2008 and December 31, 2011. Each patient was photographed and reviewed 2 years post-operatively. At the time of the 2-year review the patient was recalled for definitive rhinoplasty at the age of 16 years.

Open rhinoplasty approach was done for both techniques to locate congenitally deformed anatomical landmarks, especially the cartilaginous framework of the nose.

Nasal dorsum rotational flaps were laterally based rotation flaps [Figure 1a]. This flap design was in the shape of a parallelogram. The flap had three free edges. The medial edge was located on the lateral wall of the nose, the superior edge was located in the subciliary region and the inferior edge was immediately superior to the superior border of the lower lateral cartilage. The medial incision was superficial and dissection done subcutaneously up to the nasomaxillary suture area. Deep dissection was continued lateral to the nasomaxillary suture area to mobilize the flap [Figure 1b]. Open rhinoplasty was done to open the anterior nasal area. This process exposed the alar cartilages. The lateral crus of the affected alar cartilage were dissected away from the nasal mucosa. The nasal mucosal lining was stretched and attached anteriorly to close the cleft. The lateral crus of the affected alar cartilage was repositioned anteriorly in such a way that it became contiguous with the medial crus of the lower lateral cartilage [Figure 1c]. The pedicled skin flap was then used to cover the entire structure of upper and lower lateral cartilages [Figure 1d].

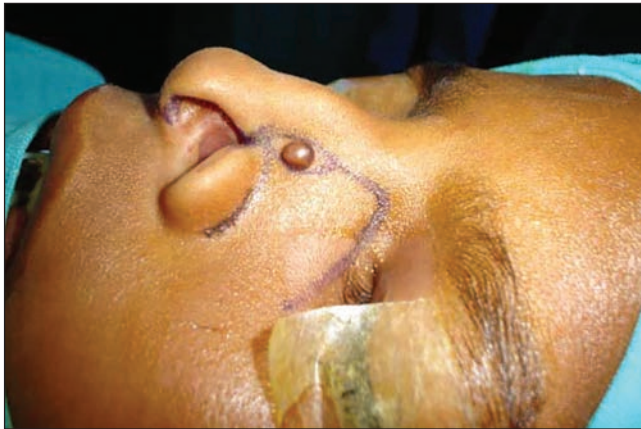

Figure 1a: Marking for the nasal dorsum rotational flaps for correction of Tessier no. 2 facial cleft showing its parallelogram shape and three free edges

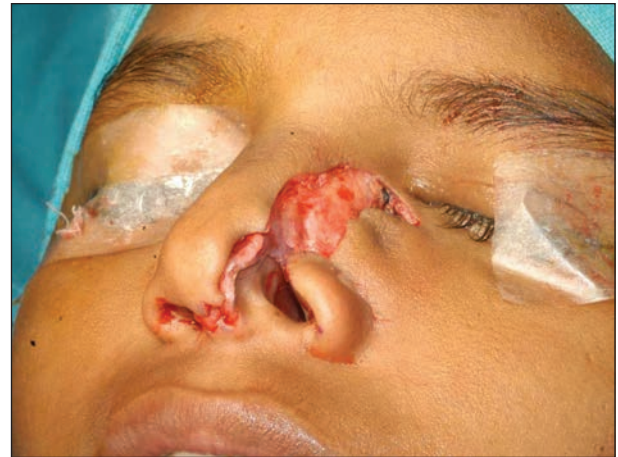

Figure 1b: Superficial and deep dissection and open rhinoplasty of the Nasal dorsum rotational flaps for correction of Tessier no. 2 facial cleft

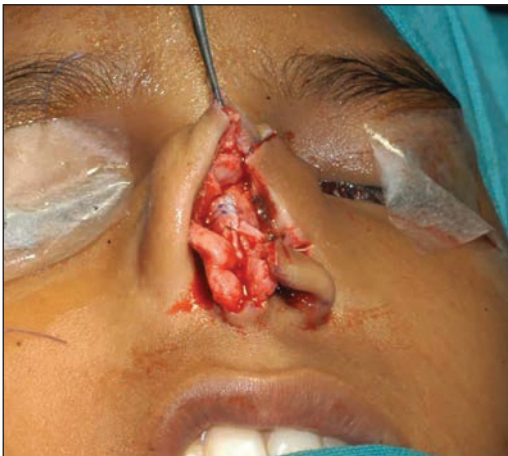

Figure 1c: Alar reconstruction using the nasal dorsum rotational flaps for correction of Tessier no. 2 facial cleft

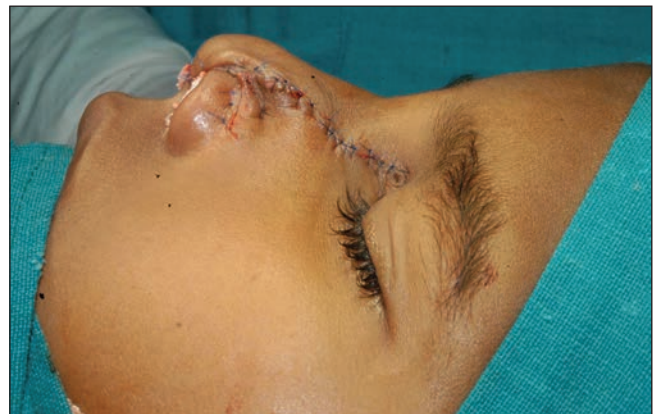

Figure 1d: Closure of the nasal dorsum rotational flaps for correction of Tessier no. 2 facial cleft

The FENTF used here was a variant of the nasal dorsum sliding flap [Figure 2a]. This technique involved the use of a frontal, inter-eyebrow sliding skin flap, with a pedicle consisting of the remaining tissue of the nasal bridge. In addition to performing an open rhinoplasty, two triangular flaps were raised. Their apices were located on the forehead and inferior to the medial brow. In addition, a subciliary incision was given. The alar cartilaginous complex was rotated downwards to bring it to the normal position. These apices of the previously raised flaps were rotated so that the forehead flap was transposed downwards into the eye brow area; the eye brow flap was rotated into the area inferior to the medial canthus [Figure 2b]. The forehead area was repaired by primary closure [Figure 2c]. This technique had the advantage of being performed as a one-stage procedure and produced less scarring when compared to multiple stage operations.

RESULTS

Of the six patients that underwent NDRF for treatment of Tessier no. 2 facial clefts, four were male and two were female. Three of these patients were operated at the age of 5 and one each at the ages of 6, 8 and 11. Of the three patients operated for Tessier no. 3 facial clefts with the FENTF, two were male, and one was female. Two of these patients were operated at the age of 2 years, and one was operated at the age of 5.

The results of the nasal dorsum rotation flap showed good healing over the lateral surface of the nose and in the subciliary region. However, the scar over the alar cartilage was suboptimal. The symmetry between the two nostrils, though not ideal, was acceptable [Figure 3a-c].

The results of the FENTF showed good healing. The symmetry between the nostrils also seemed to be acceptable, though not ideal. The main drawback found in this incision design was the superior lift of the eyebrow on the affected side that was caused by an attempt to close the donor site of the forehead component of the flap [Figure 4a-c].

DISCUSSION

Paul Tessier studied facial clefts, and his 1976 clinical classification has become the standard international nomenclature.^[3]

Tessier no. 2 clefts are located laterally to the midline Tessier No. 0 clefts without being paranasal. The cleft

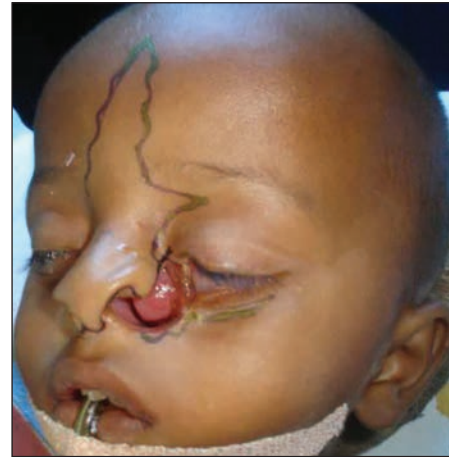

Figure 2a: Marking for the forehead-eyelid-nasal transposition flaps for correction of Tessier no. 3 facial cleft showing the two limbs over the forehead and inferior to medial brow

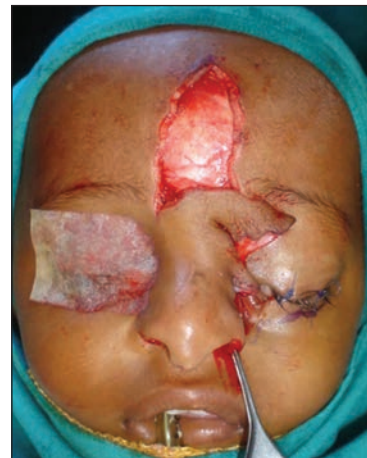

Figure 2b: Rotation of the forehead flap into the medial brow and the medial brow flap into the subciliary area using the forehead-eyelid-nasal transposition flaps for correction of Tessier no. 3 facial cleft

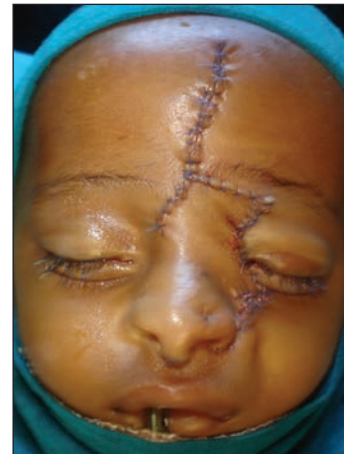

Figure 2c: Closure of the forehead-eyelid-nasal transposition flaps for correction of Tessier no. 3 facial cleft

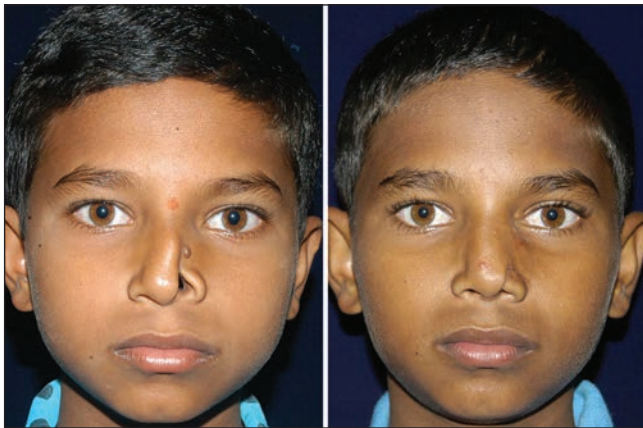


Figure 3a: Pre- and post-operative frontal view photographs of the NDF for correction of Tessier no. 2 facial cleft

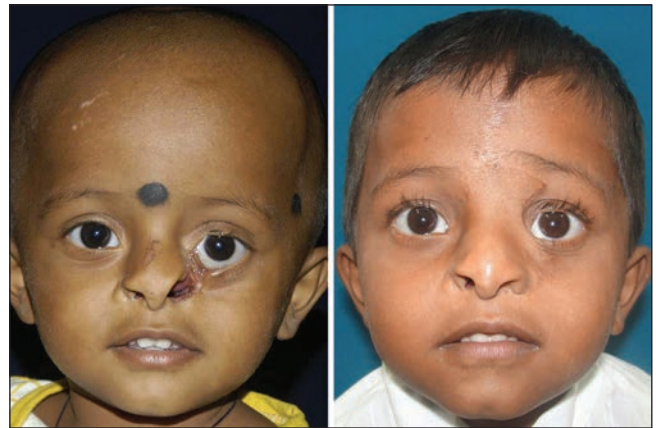

Figure 4a: Pre- and post-operative frontal view photographs of the forehead-eyelid-nasal transposition flaps for Tessier no. 3 facial cleft

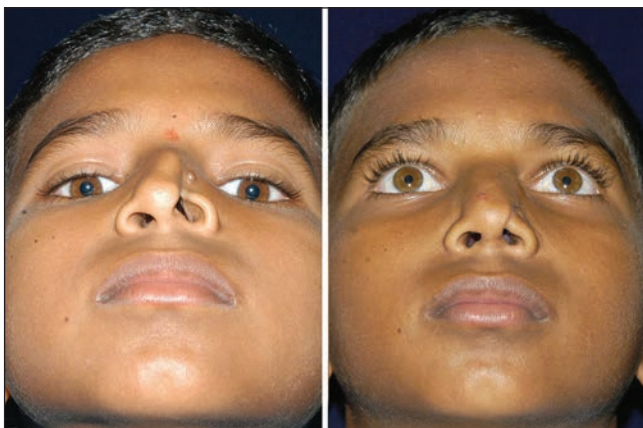

Figure 3b: Pre- and post-operative worms eye view photographs of the NDF for correction of Tessier no. 2 facial cleft

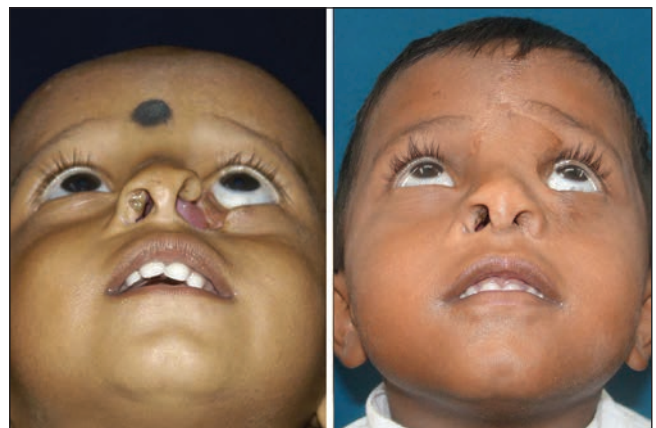

Figure 4b: Pre- and post-operative worms eye view photographs of the forehead-eyelid-nasal transposition flaps for Tessier no. 3 facial cleft



Figure 3c: Pre- and post-operative profile view photographs of the NDF for correction of Tessier no. 2 facial cleft

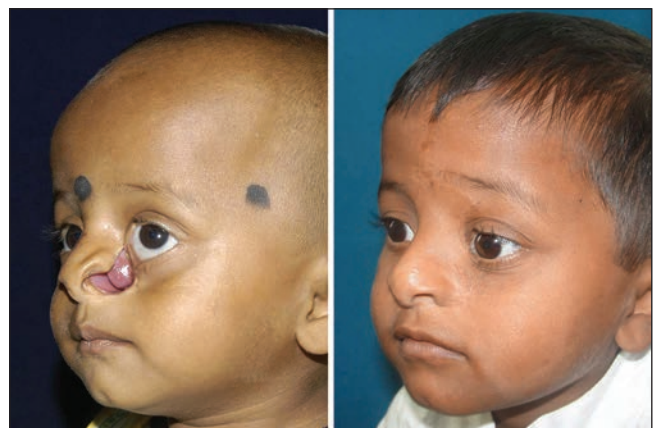

Figure 4c: Pre- and post-operative profile view photographs of the forehead-eyelid-nasal transposition flaps for Tessier no. 3 facial cleft

crosses the nasal ala between the tail of the alar cartilage and the alar base, and the tip is disfigured as in an unusual type of cleft lip.^[3] The most distinguishing characteristic of the Tessier no. 2 facial cleft is the deformity in the middle third of the nostril rim. On the affected side, the lateral part of the nose is flattened, and the nasal bridge

is broad. Skeletal involvement in Tessier no. 2 facial clefts comprises of dysplasia of the alveolus from the socket of the lateral incisor to the pyriform aperture. A notch is often seen near the junction of the nasal bone with the frontal process of the maxilla. Internally, the dysplasia crosses the lateral mass of the ethmoid.^[3,5]

Tessier no. 3 facial clefts are medial orbito-maxillary clefts, characterised by the inferior displacement of the medial canthus, superior displacement of the alar base, cleft lip, alveolus and palate, coloboma of the lower eyelid, nasolacrimal abnormalities, disruption of the medial wall of the antrum, a cleft in the medial wall of the orbit and teleorbitism.^[6] These paranasal clefts pass through the lacrimal portion of the lower eyelid, descended obliquely through the lacrimal groove and proceeded around the alar base into the nasolabial groove. The frontal process of the maxilla is frequently absent, as is the medial wall of the maxillary sinus.^[3] Encephaloceles could be occasionally associated with Tessier no. 3 facial clefts.^[7]

Clefts with minimal nasal tissue deficiency of the nose, such as the Tessier no. 2 and 3 facial clefts became more evident due to distortion with growth.^[2] The management of patients with such facial clefts was a challenge, given their rarity and the lack of standard guidelines.

Depending on the degree of malformation, a staged procedure has been considered the treatment of choice.^[7-9] However, various surgical protocols have been described in the literature, and the choice of treatment is not standardized. The Australian Craniofacial Unit Treatment Protocol, Which is one of the most widely accepted protocols to manage facial clefts, has suggested early repair of the soft tissue defects and prevention of exposure keratitis.^[8] The protocol also advises that definite bone grafting of the orbital floor; Orthognathic surgery and rhinoplasty should be done after completion of growth. This protocol also propounded the role of tissue expansion in the cheek to accommodate bone grafts. There were different types of flaps that could be used to repair these lateral defects of the nose depending on size, shape, and site of defects.^[8]

We found it easier to repair the nasal cleft at a younger age because of the ease of tissue movement. Concurring with the Australian Craniofacial Unit Treatment Protocol we treated the nasal complex to achieve symmetry as the first stage of the treatment protocol in our patients. All underlying bony defects that needed to be corrected with bone grafts, hypertelorism correction etc. were left to be done at a later stage.

The main surgical goal in treating patients with Tessier no. 2 and 3 clefts is nasal symmetry, which can rarely be achieved.^[2]

Tessier had pointed out that the immediate results of surgery are often less than satisfactory, not only as a result of the technique applied but also due to the lack of development of the facial structures. Major nasal reconstruction made with several local flaps can achieve acceptable results. However, even minimal tissue deficiency in the nose becomes more evident with the growth, and adjustments must be made either primarily or secondarily to correct these deficiencies.^[2]

In our study, the post-operative nasal symmetry was not ideal. The reason for the lack of nasal symmetry post-operatively in nasal clefts such as Tessier no. 2 and 3 clefts is the distortion of the anatomy of the alar cartilages. Since the alar cartilages are either hypoplastic or malposed, replacing or reorienting them is extremely challenging for the surgeon. In the patients that we operated with the two incision designs the nasal symmetry was adequate but not ideal.

Several authors have proposed techniques to repair the Tessier no. 2 facial cleft. Bilen and Barlets *et al.* repaired an alar cleft with a laterally based rotational flap that caused an asymmetry between the nostrils. To obtain the symmetry of the nostrils they added a z-plasty and repaired the defect with a full thickness composite graft obtained from the contralateral helix.^[10] Rashid *et al.* brought down the upturned ala as a laterally based mucochondral cutaneous alar flap with a back cut extending just above the alar groove to a point that allowed horizontal repositioning. If notching was evident they also added an alar rim z-plasty to correct the notch defect.^[11] Jinka *et al.* repaired nasal cleft with a posteriorly based rotation flap that comprised of the full thickness of the ala.^[12]

We used the NDRF design to correct Tessier no. 2 clefts. We found that this flap improved alar symmetry but decreased the nostril area. The main problem with this technique was the notch in the affected ala that required multiple procedures to correct. Similar results were obtained by Monasterio *et al.* who suggested the need for multiple refining procedures and claimed that severe clefts extending along the whole length can be corrected by rotation of longer nasal flaps alone or in combination with forehead flaps.^[2]

Several authors have described the treatment of Tessier no. 3 clefts.^[16,17] Madaree *et al.* (1992) employed a technique with five local flaps with two pairs utilizing the “z” plasty principle to obtain the lengthening and the fifth being a turnover flap for additional nasal lining. A full thickness

flap of the alar rim was rotated down, thereby equalizing the external nares. The medially based turnover flap was used to fill the gap.^[13] Monasterio *et al.* (1992) used a local transposition flap to correct the skin shortening between the medial canthus and the eye.^[2] A medial flap was rotated to elevate the dystopic canthus and cheek flaps were advanced to close the gap and to lengthen the nose.

The FENTF technique involves the use of a mediofrontal, inter-eyebrow sliding flap with its superior point in VY, and with a pedicle consisting of the remaining tissue of the nasal bridge.^[16] We used it to treat Tessier no. 3 clefts. There was a marked improvement in both the alar and nostril symmetry. We found that the rotation achieved by the flap reduced the need for revision surgery. However, scarring over the forehead was a region of concern.

We have seen the progress of these flaps 2 years post-operatively. There is a need to study the growth patterns of the nose in relation to the scars in these patients, preferably until adulthood, to definitively comment on the aesthetic outcomes of these two flap designs.

Though more thorough studies need to be performed to prove the efficacy of these two flaps, we have been able to demonstrate that Nasal Dorsum Rotation Flaps were a viable option for treating the nasal defects of Tessier no. 2 facial clefts. Similarly, FENTF were a viable option to treat the nasal defects of Tessier no. 3 facial clefts.

REFERENCES

1. Zhou YQ, Ji J, Mu XZ, Zhang RH, Wei M, Yu ZY. Diagnosis and classification of congenital craniofacial cleft deformities. *J Craniofac Surg* 2006;17:198-201.

2. Ortiz Monasterio F, Fuente del Campo A, Dimopoulos A. Nasal clefts. *Ann Plast Surg* 1987;18:377-97.
3. Tessier P. Anatomical classification facial, cranio-facial and latero-facial clefts. *J Maxillofac Surg* 1976;4:69-92.
4. Fearon JA. Rare craniofacial clefts: A surgical classification. *J Craniofac Surg* 2008;19:110-2.
5. Ozek C, Gundogan H, Bilkay U, Cankayali R, Guner U, Gurler T, *et al.* Rare craniofacial anomaly: Tessier no 2 cleft. *J Craniofac Surg* 2001;12:355-61.
6. Wenbin Z, Hanjiang W, Xiaoli C, Zhonglin L. Tessier 3 cleft with clinical anophthalmia: Two case reports and a review of the literature. *Cleft Palate Craniofac J* 2007;44:102-5.
7. Schweckendiek W. Nasal abnormalities in facial clefts. *J Maxillofac Surg* 1976;4:141-9.
8. Kawamoto HK, David DJ. Rare craniofacial clefts. In: McCarthy JC, editor. *Plastic surgery*. Vol. 4. Philadelphia: W. B. Saunders; 1990. p. 2922-73.
9. Mishra RK, Purwar R. Formatting the surgical management of Tessier cleft types 3 and 4. *Indian J Plast Surg* 2009;42 Suppl:S174-83.
10. Bilen BT, Kiliç H. A congenital isolated alar cleft. *J Craniofac Surg* 2006;17:602-4.
11. Rashid M, Islam MZ, Tamimy MS, Haq EU, Aman S, Aslam A. Rotation-transposition correction of nasal deformity in Tessier number 1 and 2 clefts. *Cleft Palate Craniofac J* 2009;46:674-80.
12. Jinka JR, Chekuri H, Annavarapu G. Isolated cleft of the ala nasi: A report of seven cases. *Indian J Plast Surg* 2012;45:512-5.
13. Madaree A, Morris WM, McGibbon IC. A method of repairing the no 3 facial cleft. *Br J Plast Surg* 1992;45:44-6.
14. Ortega J, Flor E. Incomplete naso-ocular cleft. Case report. *Plast Reconstr Surg* 1969;43:630-6.
15. Fazio MJ, Zitelli JA. The single stage nasolabial flap. *Oper Tech Plast Reconstr Surg* 1998;5:50-8.
16. Dupuis A, Hainsdorf F. Treatment of nasal saddle-back deformities using a median naso-frontal five-point star flap. *Rev Stomatol Chir Maxillofac* 1983;84:289-93.

How to cite this article: Reddy SG, Reddy RR, Obwegeser J, Mommaerts MY. Options for the nasal repair of non-syndromic unilateral Tessier no. 2 and 3 facial clefts. *Indian J Plast Surg* 2014;47:340-5.

Source of Support: Nil, **Conflict of Interest:** None declared.