

Letters to Editor

Turquoise iatrogenic tattoo of seborrheic keratoses following wide local excision: A novel phenomenon

Sir,

Following excision biopsy of a suspicious pigmented lesion on his lower back, an octogenarian male underwent wide local excision and sentinel lymph node biopsy. The initial lesion measured 1.2-cm-wide and 1-mm-tall. It was a nodular melanoma of 3.2 mm Breslow thickness with a Clark level of 4. There was no lymphovascular invasion. There were ulceration and a mitotic rate of 38/10 hpf. At our multi-disciplinary meeting, it was decided a further 3 cm margin wide local excision of the scar was recommended with a sentinel lymph node biopsy. The resulting pathology was a complete excision of the scar which showed no further residual malignant melanoma cells and no metastatic cells in the lymph nodes biopsied in his left axilla. This was confirmed by negative Melan A staining [Figure 1].

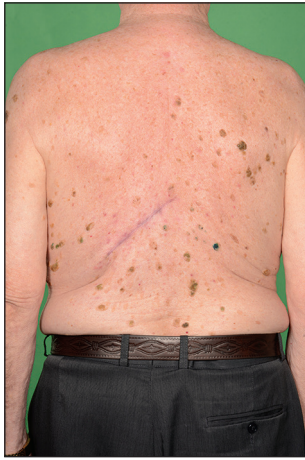

Figure 1: Photograph of back demonstrating relation of scar and seborrheic keratoses

As part of the sentinel lymph node biopsy, 4 ml of methylene blue dye was injected subdermally with a blue hypodermic needle over the centre of the scar to be excised. This was performed just after the patient had been anaesthetised and left to work for 15 min before the scar was excised. The scar was excised in the relaxed skin tension line, and primary wound closure achieved. At the time of surgery, there was no spill of the blue dye that may have caused the adjacent staining, and it was noted that the seborrheic keratosis adjacent to the wound was not blue. During 3 months follow-up in the outpatient clinic, it was noted that several bright blue lesions had appeared around the scar site. These were clinically diagnosed as seborrheic keratoses and this lesion had been present prior to the excision of the melanoma, hence, ruling out a satellite lesion. In his recent 6 months follow-up, the blue seborrheic keratosis mentioned was still present and had not changed.

Wide local excision and sentinel lymph node biopsy is a procedure that is commonly performed in the treatment of malignant melanoma.^[1,2] It is well known that transient staining of the skin occurs in the early post-operative period and patients are warned that their urine will be blue. There are no previous reports in the literature that benign skin lesions adjacent to the operative site can be dyed from methylene blue injection. This phenomenon requires further investigation to ensure it does not represent any sequelae of the underlying disease process.

The patient was told that the bright blue lesions were likely iatrogenic in origin, and did not elect to undergo any further management or investigation.^[3] He was not

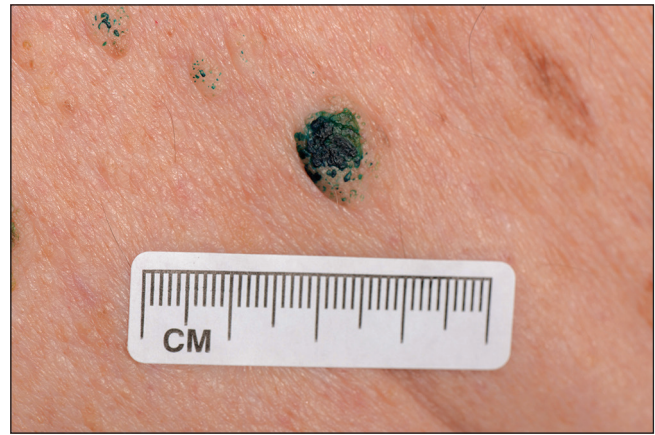


Figure 2: Photograph demonstrating the surface blue dye 3 months post-sentinel node biopsy

concerned by the cosmetic appearance and declined to consider their removal for a definitive histological diagnosis [Figure 2].

Seborrheic keratoses are benign overgrowth of epidermal keratinocytes, which are of unknown aetiology. Perhaps, due to their rate of turnover and uptake of the dye from lymph, the blue pigment has remained even at 3 months post-operatively. The dye from the scar site has most likely been taken up by the seborrheic keratosis via lymphatic channels. Of note, black stained radio-nucleotide tracer active sentinel lymph nodes secondary to cutaneous tattooing have been described which further demonstrate the flow of lymph from the skin to nearby lymph nodes.^[4] Methylene blue does come with side effects and these should be made known to the patient. Side-effects such as staining of the skin and discolouration of the urine are common. Rarer side-effects include haemolytic anaemia in G6PD deficient individuals, dizziness and abdominal pain.

We found that this is a newly reported phenomenon of methylene blue dye administration. Patients should be consented for “tattoo” sequelae (temporary or permanent) in the use of methylene blue dye. Patients with any new colour changes to a lesion should be offered excision biopsy for histological diagnosis.

**David John Laurie Pennell,
Charles Yuen Yung Loh,
Thanassi Athanassopoulos¹, Michaela Davis**

¹Plastic Surgery Department, Aberdeen Royal Infirmary,
Plastic Surgery Department, Ninewells Hospital, Dundee,
Scotland, UK

Address for correspondence:
Dr. Charles Yuen Yung Loh,
Aberdeen Royal Infirmary, Scotland, UK.
E-mail: chloh_yy@hotmail.com

REFERENCES

1. Bishop JA, Corrie PG, Evans J, Gore ME, Hall PN, Kirkham N, *et al.* UK guidelines for the management of cutaneous melanoma. *Br J Plast Surg* 2002;55:46-54.
2. Miller AJ, Mihm MC Jr. Melanoma. *N Engl J Med* 2006;355:51-65.
3. Brown SJ, Lawrence CM. The management of skin malignancy: To what extent should we rely on clinical diagnosis? *Br J Dermatol* 2006;155:100-3.
4. Yang AS, Creagh TA. Black sentinel lymph node and 'scary stickers'. *J Plast Reconstr Aesthet Surg* 2013;66:558-60.

Access this article online	
Quick Response Code: 	Website: www.ijps.org
	DOI: 10.4103/0970-0358.138984