

Original Article

Role of tongue flap in palatal fistula repair: A series of 41 cases

Ravi Kumar Mahajan, Rahul Chhajlani¹, Harish C. Ghildiyal

Department of Plastic, Reconstructive, Maxillofacial and Cosmetic Surgery, Amandeep Hospital, Amritsar, Punjab,

¹Department of Maxillofacial and Oral Surgery, Index Institute of Dental Sciences, Indore, Madhya Pradesh, India

Address for correspondence: Dr. Rahul Chhajlani, Consultant Maxillofacial and Cleft Surgeon, Dr. Chhajlani's — Dentistry, Cosmetic n Plastic Surgery and Child Care Clinic, Ganga — Jamuna Appartments, Near Nath Mandir, South Tukoganj, Indore - 452 001, Madhya Pradesh, India. E-mail: chhajlani_rahul@yahoo.co.in

ABSTRACT

Introduction: Despite the improved techniques of repair of cleft palate, fistula occurrence is still a possibility either due to an error in the surgical technique or due to the poor tissue quality of the patient. Though commonly the fistula closure is established by use of local flaps but at times the site and the size of the fistula make use of local flaps for its repair a remote possibility. The use of tongue flaps because of the central position in the floor of the mouth, mobility and the diversity of positioning the flaps make it a method of choice for closure of anterior palatal fistulae than any other tissues. The aim of this study was to analyse the utility of tongue flap in anterior palatal fistula repair. **Materials and Methods:** We had 41 patients admitted to our hospital during the period 2006-2012 for repair of palatal fistula and were enrolled into the study. In the entire 41 cases, fistula was placed anteriorly. The size of the fistulae varied from 2 cm × 1.5 cm to 5.5 cm × 3 cm. The flaps were divided after 3-week and final inset of the flap was done. **Observation and Result:** None of the patients developed flap necrosis, in one case there was the dehiscence of the flap, which was reinset and in one patient there was bleeding. None of our patients developed functional deformity of the tongue. Speech was improved in 75% cases. **Conclusion:** Leaving apart its only drawback of two-staged procedure and transient patient discomfort, tongue flap remains the flap of choice for managing very difficult and challenging anterior palatal fistulae.

KEY WORDS

Anteriorly based tongue flap; anterior palatal fistula; cleft palate repair; cleft lip repair; hyper nasality; speech

INTRODUCTION

Anterior palatal fistula or oronasal fistula is the most common complication of cleft palate repair, the incidence ranging from 4% to 35%.^[1-3]

Palatal fistulae can be classified according to their size as small (<2 mm in diameter), medium (2-5 mm) and large (>5 mm).^[4] The common symptoms include hypernasality of speech due to nasal escape of air and leakage of fluid

Access this article online

Quick Response Code:



Website:

www.ijps.org

DOI:

10.4103/0970-0358.138950

and food into the nasal cavity leading to poor oral hygiene and foul smell.

The various treatment options available are - local tissue flaps, revision palatoplasty, regional flaps-such as buccal mucosal flaps, pharyngeal flaps, tongue flaps (anteriorly or posteriorly based), microvascular free tissue transfer (radial forearm flap) and lastly prosthetic rehabilitation.^[5-8]

The aim and objective of this study were to analyse the utility of tongue flap in anterior palatal fistula repair.

MATERIAL AND METHODS

The analysis of 41 previously operated cases of cleft lip and palate with residual anterior palatal fistula, which reported to our centre between the period of 2006-2012, were done. Out of which outside operated were 32 and 9 were from those operated at our hospital. The following parameters were taken into the consideration — taste sensation, swallowing reflex, functional deformity of the tongue, cessation of regurgitation of foods/fluids from nose. Speech evaluation was done subjectively.

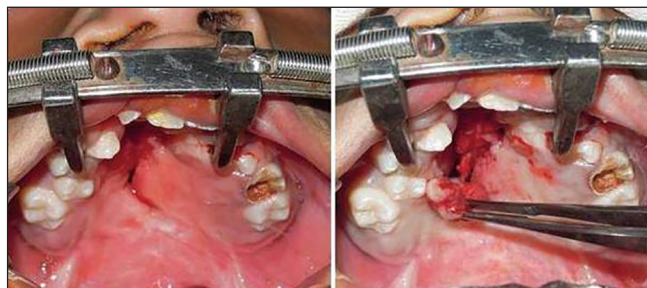


Figure 1: Preoperative intraoral view of the anterior palatal fistula and after paring of the cleft edges

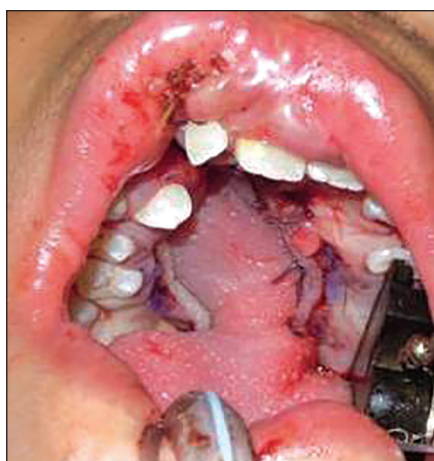

Figure 3: Tongue flap in situ providing the oral lining

Those patients having a collapsed maxillary arch were first subjected to orthodontic arch expansion. The nasal lining was repaired with turn-over flaps from the fistula edges [Figures 1 and 2] and the tongue flaps provided oral lining [Figure 3]. Length of flap was adjusted long enough to fill anteroposterior dimensions of fistula as measured with the help of a pattern and an additional 1 cm to allow smooth turning of flap, but not exceeding beyond the circumvallate papillae [Figure 4]. The width of the flap varied according to the fistula size but did not exceed more than 2/3rd the tongue width [Figure 5]. Flaps were raised in a fashion that up to 5-7 mm thickness of the muscle depth was taken in all cases to protect the underlying submucosal plexus. Donor site closure was done primarily with chromic catgut; care was taken not to close it too tight near the pedicle so as not to hamper the vascularity of the flap [Figure 6]. Proper edge to edge approximation of the flap margins to the mucoperiosteal margins was done [Figure 7]. The tongue flaps were

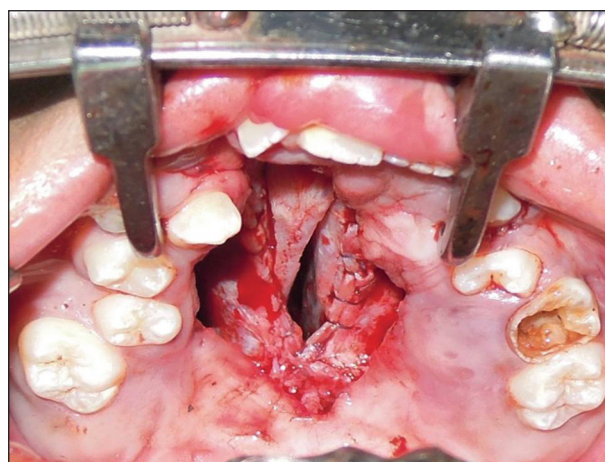


Figure 2: After the repair of the nasal lining by local turn down flaps

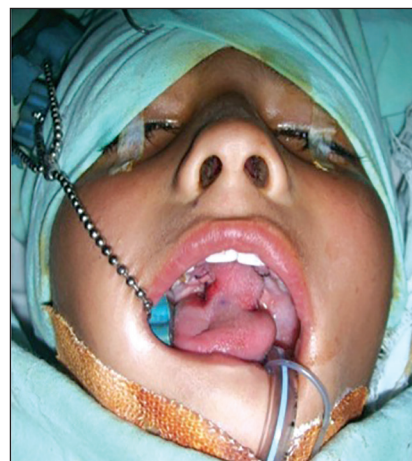

Figure 4: Base of flap lies beneath the posterior border of fistula when tongue is in neutral position facilitated by the extra 1 cm. length of flap than the AP dimension of the fistula

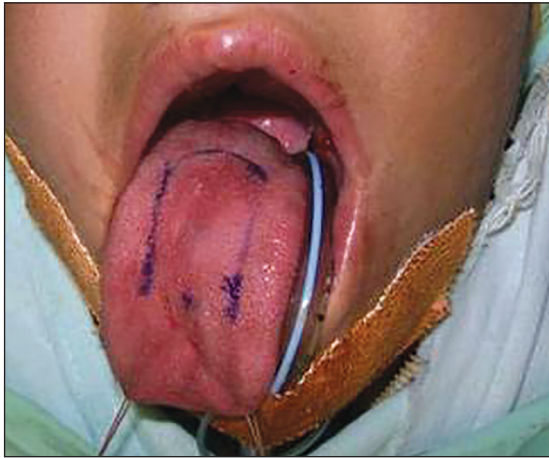

Figure 5: Tongue flap design, not exceeding beyond circumvallate papillae

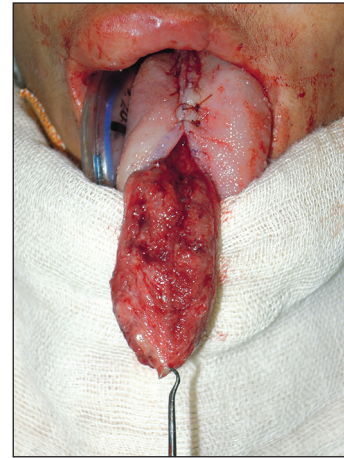


Figure 6: Primary closure of donor site maintaining the vascularity of the flap pedicle, Width of flap — up to 2/3rd width of tongue, depth of flap incorporating 5-7 mm thickness of the muscle

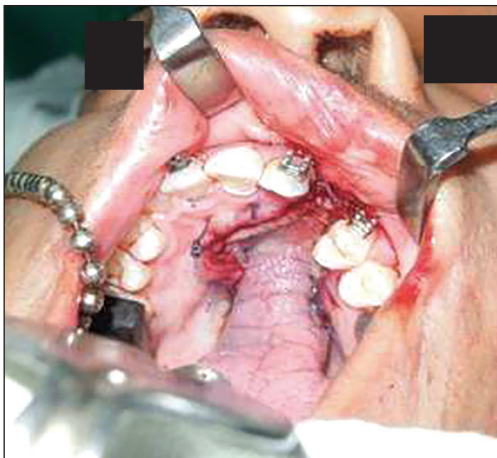

Figure 7: Good edge to edge approximation of tongue flap to the mucoperiosteal margins using mattress sutures

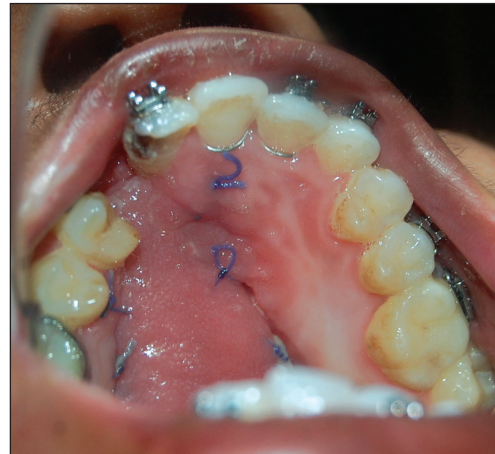

Figure 8: Tongue flap after detachment and inset after the necessary debulking

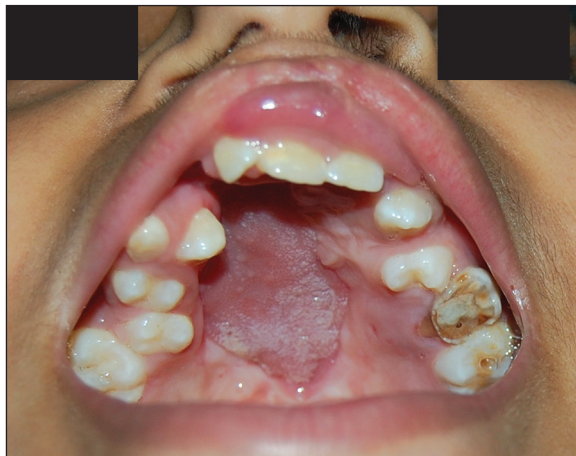

Figure 9: Late postop view of tongue flap. Note that the flap is flush with the palatal tissues

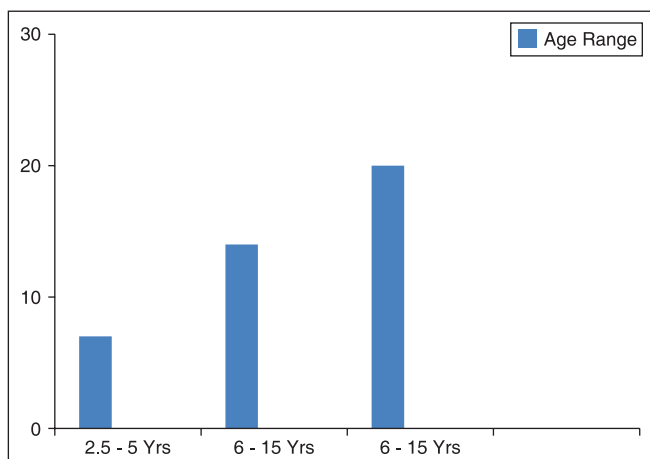
routinely divided after 21 days postoperatively [Figure 8], except in one patient wherein the detachment and inseting had to be done on the 9th postoperative day because of bleeding from one of the edges.

The patients were followed-up for 3 months postoperatively, and all the findings were recorded and analysed [Figure 9].

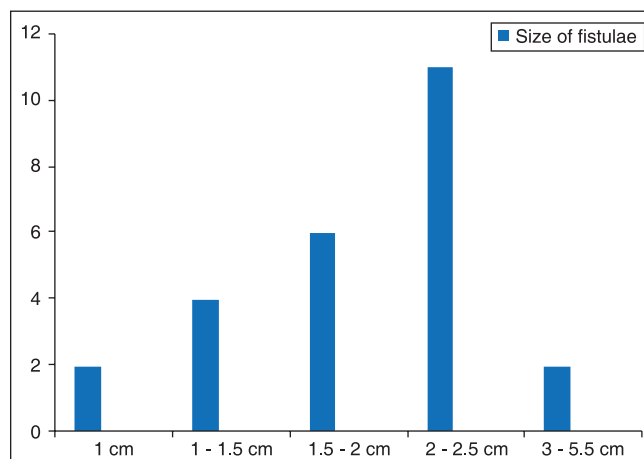
RESULTS AND OBSERVATIONS

The age range was 2.5-26 years [Graph 1]. The males comprised 66% and females 34% of the total cases [Pie Chart 1]. The distribution among the unilateral and bilateral cleft lip and palate cases is as depicted [Pie Chart 2]. The size of the fistula varied from 2 cm × 1.5 cm to 5.5 cm × 3 cm with majority being in the range, 2-2.5 cm [Graph 2].

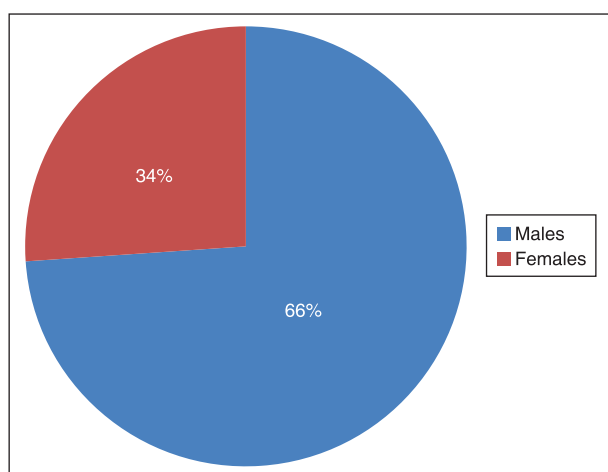
The complications noted were bleeding in one case and flap dehiscence in one case, both the flaps survived with no residual fistula.



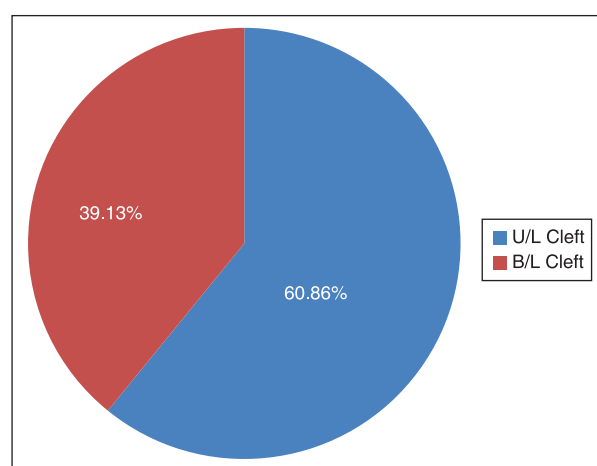
Graph 1: Age range of the patients in whom tongue flap was done



Graph 2: Anterior palatal fistula size range



Pie Chart 1: Sex distribution of the fistulae



Pie Chart 2: Distribution of anterior palatal fistulae among unilateral and bilateral cleft cases

There was difficulty in feeding for the first 2 days. None of the cases had interference with functioning of the tongue [Figure 10]. Taste sensation and swallowing reflex were normal in all the cases. Cessation of regurgitation of food/fluids from nose was 100% and improvement in the nasality of speech was observed in 75% cases.

DISCUSSION

Tongue flap has been a work horse for difficult palatal fistulae with shortage of tissue.^[3] The use of the lingual flap for repair of hard palate fistulae was first reported by Guerrero-Santos and Altamirano.^[6]

The rich vascular supply from the lingual artery and its four branches and the extensive anastomotic network with the contralateral side contributes to the versatility of the tongue flap.^[9,10] Good amount of tissue available from the tongue can be used for effectively closing even large palatal fistulae.

Success rate of the tongue flap has been reported varying from 85% to 95.5%.^[3,11-14] Success depends upon proper flap elevation, tension free nasal layer closure, edge to edge approximation of the flap with palatal tissues and not too tight closure of the donor area near the base of the flap. While raising the flap one should not take more than 5-7 mm. thickness of the muscle in order to avoid a bulky flap which may cause difficulty in swallowing and may also cause articulation problems later.^[15] All our patients had the flap flush with the adjacent palatal tissues, and none of the patients complained of any difficulty due to bulk. Tension free closure of the nasal layer is possible only if nasal layer is widely undermined and raised. In order to have proper apposition of margins mattress sutures are useful. All the sutures should be kept long and tied in the end. The success rate in our series was 100%. Only one patient had flap dehiscence, but reattachment could salvage the flap. None had a residual fistula. All the patients had cessation of nasal

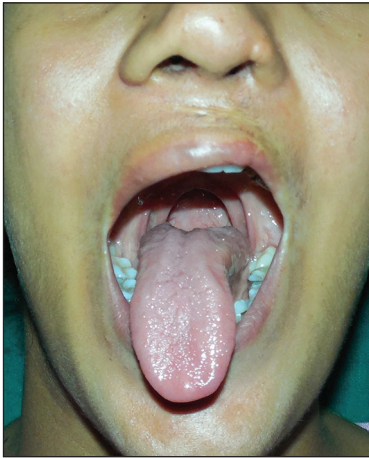

Figure 10: Appearance of the tongue postoperatively. There is no donor site morbidity and no interference with the functioning of tongue

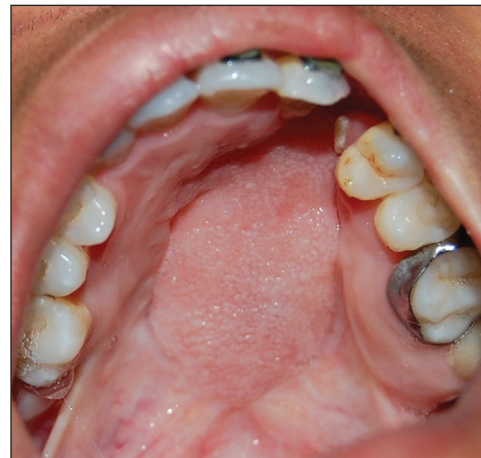

Figure 11: Large Tongue flap used to close the cleft alveolus in addition to the anterior palatal fistula

regurgitation and improvement in the nasality of speech was observed in 75% of the cases.

The tongue flap is safe and well-tolerated by children, and there is no need to put naso-gastric tube for feeding.^[2,11] In our study, 17% population were children below 5 years of age.

In order to restrict tongue movement some authors have recommended mandibulo — maxillary fixation or suture fixation of the tongue.^[16] This was not done in any of our patients and we feel this is not required. Too much of the tongue movement is automatically restricted because of the pain associated with it.

Flap division has been done by various authors varying from 10 to 21 days.^[2-3,17] In our series, we chose to do flap division after a period of 3-week except in one case where we had to do division and inset per force on the 9th postoperative day because of bleeding. We chose 3-week period for two reasons. The patients, usually from far off areas, are generally discharged on the 5th postoperative day and it is convenient for them to come back after a gap of 3-week after surgery. In the case of any marginal necrosis wounds will usually heal well by that time and division can be carried out safely. Since, while doing inseting, one has to do some flap thinning and may have to raise part of the already healed flap, 3-week period makes it safer.

Anaesthesia at the time of flap division can be challenging at times. While child is being anaesthetized, it is always a good idea for the surgeon to be ready to divide the flap immediately under local anaesthesia in case there

is any difficulty in intubation. Though we have always kept ourselves ready, there never has been an occasion when our anaesthesiologist was unable to intubate. This is probably because of the experienced anaesthesiologist being always available for such a case.

Tongue flap doesn't carry any significant donor morbidity [Figure 10]. There is no impairment of speech or movement, and there may only be temporary loss of tongue sensation and taste.^[18] None of our patients complained of any functional deformity of tongue. Taste sensation and swallowing reflex were normal in all cases.

The tongue flap in addition can also be used to close the alveolar fistula along with anterior palatal fistulae [Figure 11].

CONCLUSION

Tongue flap remains the flap of choice for managing anterior palatal fistulae, leaving apart its only drawback of two-staged procedure and transient patient discomfort. Anteriorly based tongue flap is a safe and dependable procedure and gives consistently good results in closure of anterior palatal fistulae.

REFERENCES

1. Cohen SR, Kalinowski J, LaRossa D, Randall P. Cleft palate fistulas: A multivariate statistical analysis of prevalence, etiology, and surgical management. *Plast Reconstr Surg* 1991;87:1041-7.
2. Sadhu P. Oronasal fistula in cleft palate surgery. *Indian J Plast Surg* 2009;42 Suppl:S123-8.
3. Murthy J. Descriptive study of management of palatal fistula in one hundred and ninety-four cleft individuals. *Indian J Plast Surg* 2011;44:41-6.

4. Muzaffar AR, Byrd HS, Rohrich RJ, Johns DF, LeBlanc D, Beran SJ, *et al.* Incidence of cleft palate fistula: An institutional experience with two-stage palatal repair. *Plast Reconstr Surg* 2001;108:1515-8.
5. Mukherji MM. Cheek flap for short palates. *Cleft Palate Craniofac J* 1969;6:415-20.
6. Guerrero-Santos J, Altamirano JT. The use of lingual flaps in repair of fistulas of the hard palate. *Plast Reconstr Surg* 1966;38:123-8.
7. Chen HC, Ganos DL, Coessens BC, Kyutoku S, Noordhoff MS. Free forearm flap for closure of difficult oronasal fistulas in cleft palate patients. *Plast Reconstr Surg* 1992;90:757-62.
8. Schwabegger AH, Hubli E, Rieger M, Gassner R, Schmidt A, Ninkovic M. Role of free-tissue transfer in the treatment of recalcitrant palatal fistulae among patients with cleft palates. *Plast Reconstr Surg* 2004;113:1131-9.
9. Bracka A. The blood supply of dorsal tongue flaps. *Br J Plast Surg* 1981;34:379-84.
10. Hollinshead WH. *Anatomy for Surgeons. The Head and Neck.* Philadelphia: J B Lippincott; 1982.
11. Jackson IT. Use of tongue flaps to resurface lip defects and close palatal fistulae in children. *Plast Reconstr Surg* 1972;49:537-41.
12. Pigott RW, Rieger FW, Moodie AF. Tongue flap repair of cleft palate fistulae. *Br J Plast Surg* 1984;37:285-93.
13. Abdollahi S, Jabbari Moghaddam Y, Radfar R, Raghifar R. Results of difficult large palatal fistula repair by tongue flap. *Rawal Med J* 2008;33:56-8.
14. Bath JS, Singh G, Mander KJ. Closure of palatal fistula with tongue flap. *Indian J Plast Surg* 1990;23:1-5.
15. Kummer AW, Neale HW. Changes in articulation and resonance after tongue flap closure of palatal fistulas: Case reports. *Cleft Palate J* 1989;26:51-5.
16. Steinhauser EW. Experience with dorsal tongue flaps for closure of defects of the hard palate. *J Oral Maxillofac Surg* 1982;40:787-9.
17. Ogle OE. The management of oronasal fistulas in the cleft palate patient. *Oral Maxillofac Surg Clin North Am* 2002;14:553-62.
18. Kim MJ, Lee JH, Choi JY, Kang N, Lee JH, Choi WJ. Two-stage reconstruction of bilateral alveolar cleft using Y-shaped anterior-based tongue flap and iliac bone graft. *Cleft Palate Craniofac J* 2001;38:432-7.

How to cite this article: Mahajan RK, Chhajlani R, Ghildiyal HC. Role of tongue flap in palatal fistula repair: A series of 41 cases. *Indian J Plast Surg* 2014;47:210-5.

Source of Support: Nil, **Conflict of Interest:** None declared.

Available on the iPad



Download for FREE!

IJPS is now available as a free download on your iPad.

Use the QR code or download from Apple App Store.

<https://itunes.apple.com/us/app/indian-journal-plastic-surgery/id726088047?mt=8>