

## Review Article

# Unfavourable results in temporomandibular joint ankylosis surgery

**Mukund Jagannathan, Amarnath V. Munoli**

Department of Plastic and Reconstructive Surgery, Lokmanya Tilak Municipal Medical College and General Hospital, Sion, Mumbai, Maharashtra, India

**Address for correspondence:** Dr. Mukund Jagannathan, Department of Plastic Surgery, Room No. 450, College Building, Lokmanya Tilak Municipal Medical College and General Hospital, Sion, Mumbai - 400 022, Maharashtra, India.  
E-mail: mukund.jagannathan@gmail.com

## ABSTRACT

Temporomandibular joint (TMJ) ankylosis is a debilitating condition usually afflicting children and young adults. Treatment is surgical, i.e., release of the ankylosed joint/s with or without interposition arthroplasty and correction of secondary deformities (mandibular retrusion and asymmetry) This article deals with identifying potential setbacks in TMJ ankylosis surgery and preventing them.

## KEY WORDS

Ankylosis; complications; temporomandibular joint

## INTRODUCTION

Unfavourable results include unexpected adverse events and complications associated with both surgery and results. Basically, there are two broad areas which need to be addressed.

- Issues in primary surgery - these are a consequence of:
  - Incomplete appreciation of the extent of the deformity
  - Anaesthesia related issues
  - Intra and immediate post-operative issues
  - Intermediate and long term issues following primary surgery.
- Issues related to secondary surgery of deformities.

## ISSUES IN PRIMARY SURGERY

### Incomplete appreciation of the extent of the deformity

Unless a complete and detailed analysis of the extent of the ankylosis is made, surgical treatment is likely to be compromised and in some cases, may increase the risk of complications.

A detailed clinical examination must be accompanied by a computed tomography (CT) scan. For many years the teaching was that an orthopantomogram was all that was needed, but there are likely to be several points missed unless a good CT scan is taken.

It is important to realize and identify:

- Whether the ankylosis is unilateral or bilateral
- Extent of the bony fusion, including presence or absence of joint space
- Length of the coronoid process on both sides.

Despite all these, at times it is difficult to say with 100% reliability whether both sides are involved. This will

Access this article online	
Quick Response Code:	Website: www.ijps.org
	DOI: 10.4103/0970-0358.118598

decide the operative sequence and the indication for exposing what appears to be a “normal” joint.

The extent of the bony fusion should be carefully studied. This will be a good indicator of the extent of drilling needed to release the bony block. In severe cases where the visibility and access is limited, knowledge of the medio-lateral extent can be invaluable to prevent injury to the internal maxillary artery [Figure 1].

Length of the coronoid process is also important since this will determine if a coronoidectomy is needed, either unilateral or bilateral.

### Anaesthesia related issues

To forestall disasters, a detailed evaluation by the anaesthesiologist is mandatory. Despite availability of endoscopic assisted intubation, a tracheostomy should always be kept as an emergency standby.

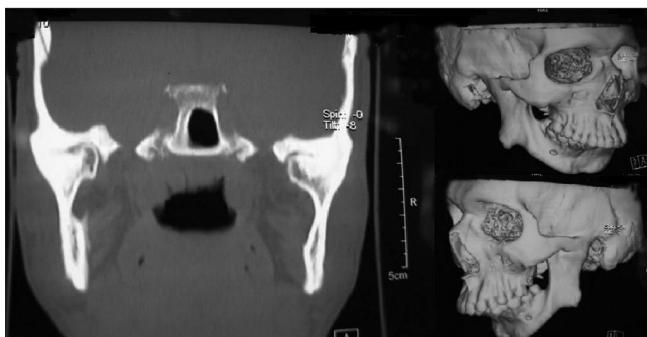### Intra and immediate post-operative issues

Careful attention to A and B will prevent many unfavourable issues related to surgery like:

- Surgical mishaps
- Failure to achieve adequate mouth opening
- Peculiar problems like bradycardia
- Occlusal problems immediate post-operatively.

### Surgical mishaps

TMJ ankylosis surgery requires a sound knowledge of the distorted anatomy of the deformity. Damage to the frontal branch of the facial nerve may occur. In most cases it is due to retraction. By using the subfascial approach of Al Kayat and Bramley<sup>[1]</sup> it is possible to avoid using any sort of retraction till the deep fascia and periosteum is incised. This reduces the chance of traction on the nerve.



**Figure 1:** Coronal section and 3-D tomographic images of bilateral temporomandibular joint ankylosis demonstrating clearly the medio-lateral extent of the bony fusion

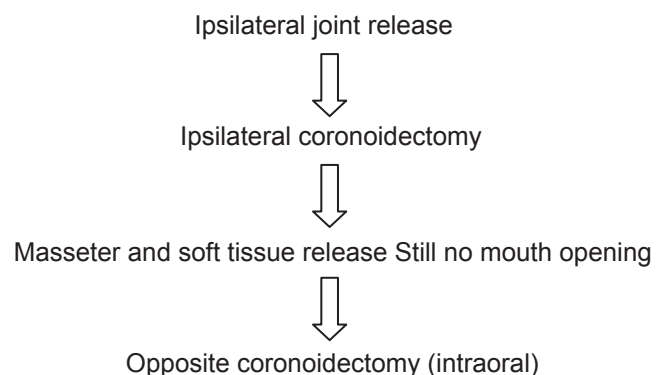
After exposure of the bony block by widely elevating the periosteum over the zygoma it is possible to expose the anterior aspect of the coronoid process. Failure to do this will not allow coronoidectomy through the same incision.

Knowledge of the approximate thickness of the bony block and its location will ensure that the release is performed at the correct level. Deep to the condylar head are two important structures – the pterygoid venous plexus can cause troublesome bleeding without any way to arrest it except by packing and the internal maxillary artery which if damaged can cause torrential bleeding. If the joint is not yet fully released, this can become pretty alarming and difficult to control. Knowing the length of the bony block can allow the surgeon to exercise caution while completing the medial most part of the osteotomy.

After release, while testing for jaw mobility using a jaw stretcher, it is important to use a padded instrument and apply it on the molars. With poor oral hygiene and weak teeth there are high chances of breaking them if these precautions are not observed.

### Failure to achieve mouth opening

Failure to achieve a reasonably good mouth opening is usually related to incomplete release of the affected structures, whether bony or soft tissue. In the absence of overt bilateral joint involvement, a logical sequence should be employed for ensuring the best chance of release and adequate mouth opening. One such sequence would be



In long standing unilateral cases, in our own series, we have an incidence of performing opposite side coronoidectomy in almost 80% of cases. This is also similar to the protocol followed by Kaban *et al.*<sup>[2]</sup>

At this stage, in unilateral ankylosis, adequate mouth opening is achieved. If it is not, further soft tissue release is performed on the apparently unaffected side. A decision has to be taken whether to open the other joint, suspecting fibrous ankylosis. Much would depend on the pattern of passive movement of the released jaw.

#### ***Peculiar problems***

In long standing cases, especially if the mandible is severely retruded, we have noted and reported severe bradycardia on jaw stretching, both under anaesthesia and in the post-operative period.<sup>[3]</sup> This must be kept in mind and stretching performed very slowly in these cases. The exact cause is not known. What is known is that this phenomenon gradually reduces over 10-14 days.

#### ***Occlusal problems***

Usually open bite manifest after bilateral coronoidectomy. This usually adapts after a couple of weeks.

#### **Intermediate and long term issues following primary surgery**

These are usually related to failure of maintenance of adequate mouth opening. Patients need to be motivated to use the jaw stretcher, overcoming the pain barrier. Adequate counselling and judicious use of analgesics will overcome this to a great extent.

- Re-ankylosis may occur. The reasons are varied and include
  - Incomplete or inadequate primary release
  - Re-ossification
  - Inadequate jaw stretching for any reason.

Re-ankylosis, irrespective of the cause, has to be dealt with surgically. This is usually more difficult as compared to the primary surgery, and detailed and meticulous planning and execution are needed.

- Growth alterations of costochondral graft have been reported. Basically the growth of the graft is appositional, i.e., in response to stresses of the downward movement of the maxilla and mandible. It is unpredictable and there may be undergrowth as well as overgrowth.<sup>[4,5]</sup>

#### **ISSUES RELATED TO SECONDARY SURGERY OF DEFORMITIES**

Secondary rehabilitation basically consists of correction

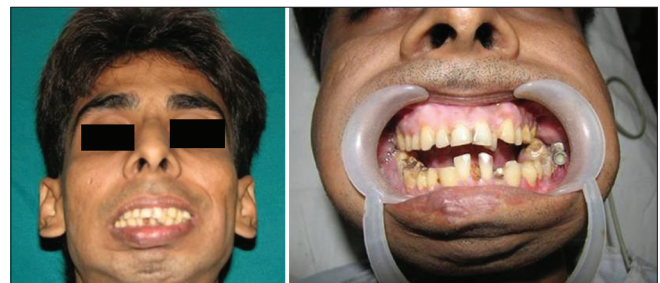of the deviation or retrusion as needed. This is usually performed by bony distraction. Distraction has proved to be a boon in the management of deformities of the jaws, but some facts have to be kept in mind, especially in post-ankylosis release surgery, where the proximal segment is very small and forming a pseudo joint without the formal joint architecture.

- No control of movement of proximal segment (smaller segment)
- Skewed weightage of the two fragments being distracted, especially if a simultaneous double jaw distraction is being done
- Careful calculation of the vector, and planning the movement, prevention of locking because of teeth etc.

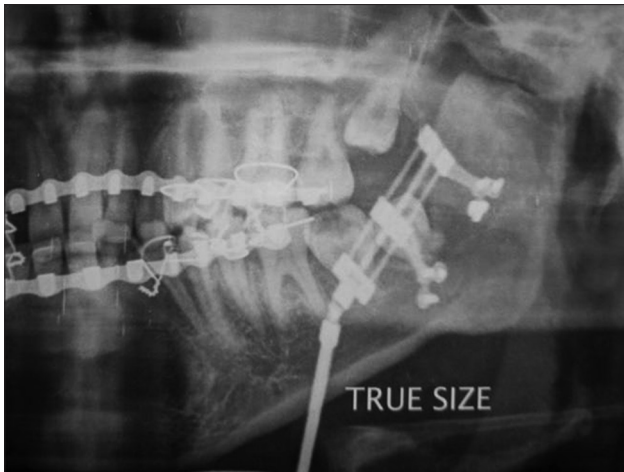
Ideally, considering the dynamics of distraction, it would be very useful in severe cases to perform the distraction prior to release, but this has its own problems, most important being two difficult intubations. The maxillary teeth can also come in the way of distraction.

Vector miscalculation can cause occlusal problems. In early stages, elastics can improve it, but if it is established, it may require corrective surgery [Figure 2].

Considering the relative weights of the greater and the lesser fragments, there is a tendency for the smaller fragment to migrate superiorly rather than the distal fragment moving forward or downward as is desirable. This, apart from not achieving the purpose of distraction, can cause the fragment to impinge on the joint and curtail movement. This problem is shown in the lateral X-ray in this patient who had simultaneous double jaw distraction to correct the occlusal cant can't as well as deviation [Figure 3].



**Figure 2:** Malocclusion following mandibular distraction for retruded mandible in an operated case of temporomandibular joint ankylosis release

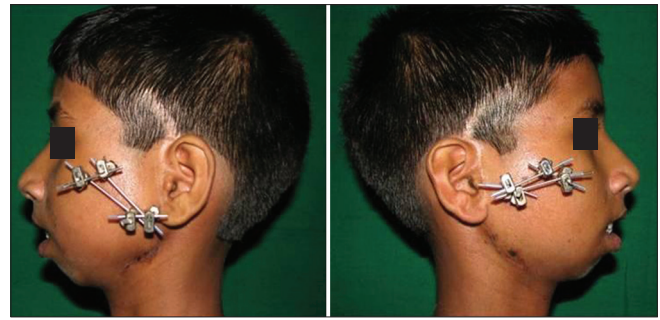

**Figure 3:** Radiograph of mandibular distraction following temporomandibular joint ankylosis release showing superior migration of smaller proximal fragment causing joint compression

A simple box joint type external fixator applied on the proximal fragment(s) can prevent this and improve the efficiency of distraction, as shown in Figure 4.

## SUMMARY

Surgery for TMJ ankylosis is very rewarding but has a plethora of undesirable sequelae and complications. These patients have to be managed on a long term basis. Careful analysis, planning and execution of various surgical manoeuvres, anticipation of problems and their correction will go a long way in successful management of these issues.



**Figure 4:** External fixator applied to prevent superior migration of proximal fragment (the distractor is intra-oral as seen in Figure 3)

## REFERENCES

1. Al-Kayat A, Bramley P. A modified pre-auricular approach to the temporomandibular joint and malar arch. *Br J Oral Surg* 1979;17:91-103.
2. Kaban LB, Perrott DH, Fisher K. A protocol for management of temporomandibular joint ankylosis. *J Oral Maxillofac Surg* 1990;48:1145-51.
3. Jagannathan M, Nayak BB, Dixit V, Wagh M. Bradycardia following temporomandibular joint ankylosis release. *Eur J Plast Surg* 2003;26:324-5.
4. Munro IR, Phillips JH, Griffin G. Growth after construction of the temporomandibular joint in children with hemifacial microsomia. *Cleft Palate J* 1989;26:303-11.
5. Perrott DH, Umeda H, Kaban LB. Costochondral graft construction/reconstruction of the ramus/condyle unit: Long-term follow-up. *Int J Oral Maxillofac Surg* 1994;23:321-8.

**How to cite this article:** Jagannathan M, Munoli AV. Unfavourable results in temporomandibular joint ankylosis surgery. *Indian J Plast Surg* 2013;46:235-8.

**Source of Support:** Nil, **Conflict of Interest:** None declared.

## Announcement

### iPhone App



Download  
**iPhone, iPad  
application**

FREE

A free application to browse and search the journal's content is now available for iPhone/iPad. The application provides "Table of Contents" of the latest issues, which are stored on the device for future offline browsing. Internet connection is required to access the back issues and search facility. The application is Compatible with iPhone, iPod touch, and iPad and Requires iOS 3.1 or later. The application can be downloaded from <http://itunes.apple.com/us/app/medknow-journals/id458064375?ls=1&mt=8>. For suggestions and comments do write back to us.