

## Original Article

# CT angiographic evaluation of perforators in the lower limb and their reconstructive implication

Visweswar Bhattacharya, Neeraj K. Agrawal, Gurab R. Chaudhary, Srivastava Arvind<sup>1</sup>, Siddharth Bhattacharya<sup>2</sup>

Department of Plastic Surgery, <sup>1</sup>Department of Radiology, Institute of Medical Sciences, Banaras Hindu University, Varanasi, Uttar Pradesh, <sup>2</sup>Department of General Surgery, IPGME and SSKM Hospital, Kolkata, West Bengal, India

**Address for correspondence:** Dr. Visweswar Bhattacharya, Department of Plastic Surgery, Institute of Medical Sciences, Banaras Hindu University, Varanasi, Uttar Pradesh, India. E-mail: visweswar1@rediffmail.Com

### ABSTRACT

**Background:** The perforator flaps evolved on the knowledge of the vascular tree from the main vascular trunk up to the subdermal plexus. Therefore, we thought that it's necessary to map the whole vascular arcade by CT angiography. The aim of this study is to evaluate the perforators and the whole vascular tree of the lower limb by peripheral CT angiography with 3D reconstruction and intraoperative evaluation. This study helps in designing flaps of different constituents based on the selected perforators. **Materials and Methods:** Twenty patients having lower limb defects were selected. CT angiography was done using a non-ionic iodinated contrast media injected through the antecubital vein. The lower limbs were imaged using volume rendering CT scan machine. Three dimensional reconstructions were made. The whole arterial tree, along with the perforators, were mapped. Findings of the audio-Doppler were correlated with the CT angiographic observations. Further these evaluations were confirmed by intraoperative findings. **Results:** The three dimensional CT angiographic reconstruction with bone and soft tissue provided advanced knowledge of this vascular network. It delineated the main vessel, the perforators, their caliber, distance from fixed bony landmarks and course up to the subdermal plexus. These findings were confirmed during dissection of the proposed flap. The perforators were mainly musculocutaneous in the proximal leg and septocutaneous distally. **Conclusions:** The vascular details visualized by this technique made advancement over the existing methods namely color Doppler, audio Doppler, two dimensional angiography etc. It improved the understanding of perforator flaps and their successful clinical application.

### KEY WORDS

CT angiography; lower limb; perforator; reconstruction

### INTRODUCTION

Better evaluation technique and understanding of vascularity of the lower limb has led to evolution of various flaps of different constituents. This was possible due to consistent technological advancement delineating the vascular network. The knowledge was applied in designing different types of flaps

Access this article online	
Quick Response Code: 	Website: <a href="http://www.ijps.org">www.ijps.org</a>
	DOI: 10.4103/0970-0358.105959

as well as their mode of transfer. Initially, the identification and localisation of the perforators of the posterior tibial and peroneal vessels by cadaveric dissection and dye studies laid the foundation.<sup>[1]</sup> They were further augmented by colour-Doppler and audio-Doppler findings. Further advancement in the field of radiodiagnosis was in the form of two-dimensional computed tomographic (CT) angiography which provided better visualisation of vessels through sequential sagittal sections. Now with in-depth knowledge of three-dimensional (3D) CT angiographic imaging, the whole vascular tree can be traced from the main vascular trunk to the subdermal plexus. The knowledge of such advanced concept is important for research and clinical applications. It was appreciated that 3D reconstruction after peripheral CT angiography provided most clear delineation of the vascular arcade. Further, the perforators were identified intraoperatively during flap dissection for reconstruction. The findings of all these procedures were correlated.

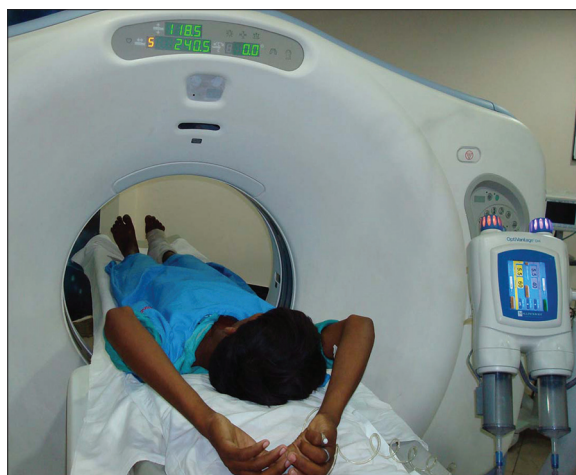## MATERIALS AND METHODS

The study was conducted in the departments of plastic surgery and radiodiagnosis, Institute of Medical Sciences, Banaras Hindu University. Formal permission was received from the ethical committee to conduct this study. Twenty patients having soft tissue defect of various etiologies at different levels of the lower limb were selected, who required soft tissue reconstruction. None of them had any associated systemic disease. Out of them, 14 were males and 6 were females. Their age ranged from 8 to 62 years, with a mean age of 35 years. Majority of the patients had post-traumatic defects except two who had post burn unstable scar.

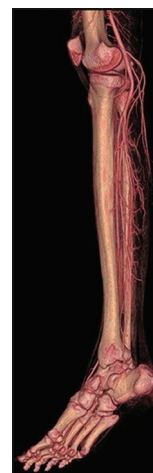
The distribution of defects was as follows:

- Middle one-third of leg: 2
- Lower one-third of leg: 3
- Medial malleolus: 2
- Lateral malleolus: 2
- Dorsum of foot: 6
- Heel defect: 5

The selected patients were enquired about history of any drug allergy. The pulse rate and blood pressure were measured. They were advised to remain in empty stomach 4 h prior to CT angiography. GE lightspeed volume rendering CT scan machine (64-slice) was used [Figure 1]. A non-ionic iodinated contrast medium (Ultravist 370) was used. It was administered in a dose of 1 ml/kg body weight (max. 70 ml) through antecubital vein by double barrel pressure injector at the rate of 3-4 ml/s, followed by saline chase of about 20 ml. CT data acquisition was done 50-60 s from the start of injecting the contrast bolus. The slice thickness was 0.625 mm. Processing of images was done by maximum intensity projection with removal of bony and soft tissue structures and then by volume rendering for visualisation of peripheral vasculature including the perforators with bony and soft tissue background separately. The 3D CT angiographic reconstructions with bone and soft tissue provided advanced knowledge of the whole vascular tree starting from the main vessel, origin of the perforators, their location, direction, number and calibre. When the reconstruction included soft tissue also, the perforators could be traced up to the subdermal plexus. Thus, the details of vascular arcade could be delineated prior to flap dissection. Audio-Doppler was done to locate the perforators,



**Figure 1:** Patient undergoing peripheral CT angiography with volume rendering CT scan machine



**Figure 2:** CT angiography showing the perforators of the posterior tibial artery

which was correlated with the CT angiographic films. The proposed flap for reconstruction was marked. A linear incision was made along one margin of the proposed flap which was close to the main vascular axis based on whose perforators the flap was planned. The flap was elevated in the subfascial plane towards the axis to identify the perforators from proximal to distal areas. The venae comitantes helped in identification of the perforators which were exactly in the same locations as observed by angiography. Lignocaine in normal saline was sprinkled intermittently to relieve the vascular spasm. After 15-20 min following dissection, the pulsation of the perforators could be easily appreciated. No tourniquet was used.

## RESULTS

Prior to CT angiography, the lower limb length was measured from the medial condyle of the tibia to the tip of the medial malleolus. Although the limb length is seen to be smaller on the screen, measurements on the machine give the actual measurement. Attention was paid to the groups of observations for posterior tibial artery and its perforators [Figure 2], so also for peroneal artery and its perforators [Figure 3]. When 3D reconstruction incorporated the bones and vessels, we could visualise the exact location of the perforators, their direction and calibre. Further, when the soft tissue was included, the vascular continuity could be seen up to the subdermal plexus [Figure 4a, b]. On an average, eight perforators with calibre of 1-2 mm or more could be identified both for the posterior tibial and peroneal arteries. On occasions, smaller perforators of less than 1 mm were found within 1 cm of a larger perforator. The location of the perforators was measured from the fixed bony landmarks, e.g. from the tip of the medial and lateral malleoli. It is difficult to memorise the findings of several individual sections and their analysis. Therefore, 3D reconstruction with 360° rotation was done. This allowed instant visualisation of the whole vasculature from popliteal artery up to the foot. This is the most important aspect of 3D CT angiography. After studying the CT angiography, we confirmed the findings intraoperatively during dissection of the proposed flap [Figure 5]. Their locations from fixed bony landmarks were exactly the same. We could appreciate the pulsation in most of the perforators.

## DISCUSSION

The evolution of flaps has come a long way in terms

of tissue constituents and mode of transfer. This advancement could be possible due to better delineation and understanding of the vascular system and its ability

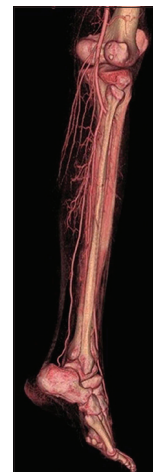

Figure 3: CT angiography showing the perforators of the peroneal artery

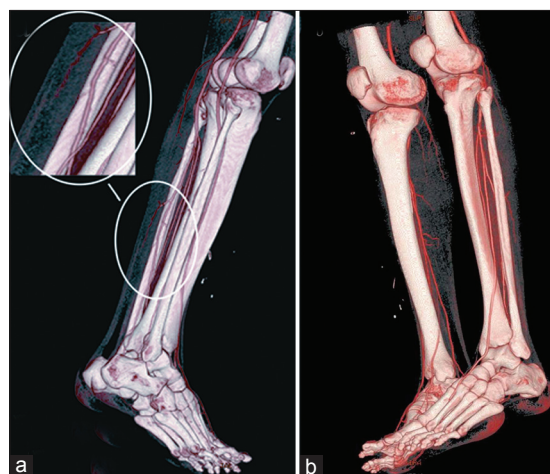


Figure 4: (a, b) Course of the perforators up to the subdermal plexus of the posterior tibial and peroneal arteries. In (a), the inset shows the magnified view of the course of a peroneal perforator

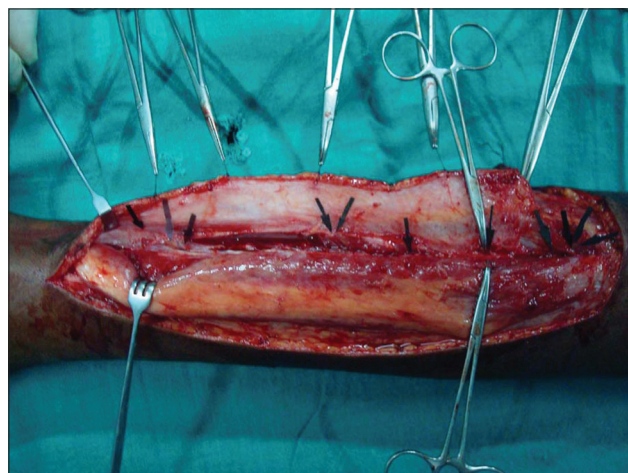


Figure 5: Intraoperative confirmation of location of the perforators



to perfuse a flap. The perforator flap concept was introduced by Kroll and Rosenfield<sup>[2]</sup> in 1988. Nakajima *et al.*<sup>[3]</sup> emphasised the necessity of vascular anatomy superficial to deep fascia. The locoregional perforator flaps are preferred for reconstruction whenever adjacent normal tissue of required dimension is available. The two most important reasons are: (a) it does not sacrifice any major vessel in an already traumatised limb and (b) it does not require microvascular free tissue transfer. However, a free flap from a distant area can also be planned to be anastomosed to a perforator.

The introduction of dynamic multislice 3D CT angiography has revolutionised many surgical specialities,<sup>[4]</sup> but only recently found application in the field of plastic surgery. Such study has been undertaken in the past either in the cadavers or in other parts of the body for harvesting free flaps such as DIEP flap.<sup>[5,6]</sup>

Tang *et al.* (2008) have studied vasculature in two fresh cadavers using Materialise's Interactive Medical Image Control System with lead oxide–gelatin injection for anatomical research. This provided detailed 3D microvasculature of different regions of the body. This knowledge is very useful in designing various flaps including perforator flaps. However, there is scanty literature regarding the 3D CT angiographic evaluation of the vascular network of the lower limb. In this study, we have used peripheral CT angiography and 3D reconstruction in 20 patients in whom we planned perforator-based locoregional flaps for resurfacing the defects. In the 3D reconstruction incorporating the vessels and the bone, we could visualise the whole vascular tree with information regarding the origin of the perforators, their direction, calibre, interperforator distance and also their location from fixed bony landmarks. When we incorporated the vascular tree along with bones and soft tissue, we could visualise the course of the perforators up to the subdermal plexus. By 360° rotation of dynamic 3D CT reconstruction, every detail of the vascular tree could be delineated, which otherwise will be missing in a single slice. This is advancement over the existing two-dimensional sagittal tomography which does not provide the detailed findings required for reconstruction. The other advantages of CT angiography over other techniques are (a) high contrast resolution, (b) elimination of superimposition of images, (c) only the area of interest can be studied in great detail using volume rendering, (d) dynamic imaging of the vascularity during contrast

injection, and (e) use of non-ionic iodinated contrast media helps in better delineation and differentiation of different soft tissue and bony constituents. Further, we compared the findings of the 3D CT angiography with those of the audio-Doppler and intraoperative location of the perforators. The procedure did not hamper the operative technique as one of the proposed lines of incision closer to the vascular trunk was chosen to explore these perforators through the subfascial dissection. The intraoperative findings of perforators during flap dissection confirmed the accuracy of peripheral CT angiography. Based on the perforators, one can design flaps of different tissue constituents, e.g. fasciocutaneous, adipofascial or fascial flap, according to the requirement of the defect. However, the safe dimension of these flaps will be different.<sup>[1]</sup> Thus, we feel that 3D CT angiography with 360° dynamic rotation provides enhanced knowledge over the existing technologies which are useful to design and transfer flaps of different constituents and dimension based on the perforators.

## ACKNOWLEDGMENT

The authors like to acknowledge Dr. Shipra Bhattacharya, PhD (English), for correcting the manuscript.

## REFERENCES

1. Bhattacharya V, Goyal S. A dye study in fresh cadavers to outline retrograde flaps of the lower limb and to examine clinical implications. *Eur J Plast Surg* 2005;28:458-63.
2. Kroll SS, Rosenfield L. Perforator-based flaps for low posterior midline defects. *Plast Reconstr Surg* 1988;81:561-6.
3. Nakajima H, Minabe T, Imanishi N. Three-dimensional analysis and classification of arteries in the skin and subcutaneous adipofascial tissue by computer graphics imaging. *Plast Reconstr Surg* 1998;102:748-60.
4. Nagler RM, Braun J, Daitzman M, Laufer D. Spiral CT angiography: An alternative vascular evaluation technique for head and neck microvascular reconstruction. *Plast Reconstr Surg* 1997;100:1697-702.
5. Masia J, Clavero JA, Larrañaga JR, Alomar X, Pons G, Serret P. Multidetector-row computed tomography in the planning of abdominal perforator flaps. *J Plast Reconstr Aesthet Surg* 2006;59:594-9.
6. Alonso-Burgos A, García-Tutor E, Bastarrika G, Cano D, Martínez-Cuesta A, Pina LJ. Preoperative planning of deep inferior artery epigastric perforator flap reconstruction with multislice-CT angiography: Imaging findings and initial experience. *J Plast Reconstr Aesthet Surg* 2006;59:585-93.

**How to cite this article:** Bhattacharya V, Agrawal NK, Chaudhary GR, Arvind S, Bhattacharya S. CT angiographic evaluation of perforators in the lower limb and their reconstructive implication. *Indian J Plast Surg* 2012;45:494-7.

**Source of Support:** Nil, **Conflict of Interest:** None declared.