

Acute Vertigo in a Patient with Long-Term Organic Solvent Exposure: Importance of a Comprehensive Audio-Vestibular Test Battery

Maxime Maheu¹ François Champoux^{1,2} Adrian Fuente^{1,2}

¹École d'Orthophonie et d'Audiologie, Université de Montréal, Montréal, Québec, Canada

²Centre de Recherche de l'Institut Universitaire de Gériatrie de Montréal, Montréal, Québec, Canada

Address for correspondence Maxime Maheu, Faculté de médecine, École d'orthophonie et d'audiologie, Université de Montréal, Montréal, Québec, Canada H3C 3J7 (e-mail: maxime.maheu@umontreal.ca).

J Am Acad Audiol 2020;31:363–368.

Abstract

Background Ototoxicity induced by organic solvents has been identified in several groups of workers. Little is known, however, about the effects of organic solvents on the vestibular system.

Purpose The aim of the study was to comprehensively assess the vestibular system and auditory functions in a worker exposed to organic solvents.

Research Design Both behavioral and physiological auditory and vestibular evaluations were performed.

Results No auditory-related findings associated with solvent exposure were found. The vestibulo-ocular reflex gain was abnormal for all semicircular canals with significant catch-up saccades, as measured by the video head impulse test. The cervical vestibular evoked myogenic potentials was absent in the right ear and small but replicable in the left ear. Ocular vestibular evoked myogenic potential were bilaterally absent.

Conclusions The results suggest a case of vestibulotoxicity induced by a long history of organic solvent exposure. We suggest that solvent-exposed individuals should be evaluated with a comprehensive battery of auditory and vestibular tests.

Keywords

- ▶ hearing
- ▶ organic solvents
- ▶ VEMP
- ▶ vestibular system
- ▶ vHIT

Introduction

Ototoxicity induced by organic solvents has been identified in several groups of workers (Hsu et al).⁹ Solvent exposure has been associated with both peripheral and central auditory dysfunction (for a complete review, see Fuente and McPherson).⁵ In addition, a number of studies have found a higher prevalence of vestibular dysfunction in occupational populations exposed to solvents. Some of these studies have found an adverse effect of solvent exposure on both vestibular spinal reflex and vestibulo-ocular reflex (VOR) (Zamysłowska-Szmytke and Sliwinska-Kowalska;¹⁶ Zamysłowska-Szmytke et al;¹⁶ Fife et al;⁴ Giorgianni et al).⁶ The test battery used in such studies, however, has been rather limited and inconsistent across studies, further complicating the conclusions that can be

drawn from the composite data. For example, the vestibular spinal reflex has been evaluated using either the cervical vestibular evoked myogenic potentials (cVEMP) or posturography (Zamysłowska-Szmytke and Sliwinska-Kowalska;¹⁶ Zamysłowska-Szmytke et al;¹⁶ Hsu et al;⁹ Giorgianni et al).⁶ The VOR has been explored using either the caloric test, the ocular vestibular evoked myogenic potentials (oVEMP), or the rotary chair (Zamysłowska-Szmytke and Sliwinska-Kowalska;¹⁶ Hsu et al;⁹ Fife et al).⁴ The video head impulse test (vHIT) is a recently developed technique to evaluate the VOR function at high frequencies, as opposed to low and mid frequencies, which are assessed by the caloric and rotary chair techniques, respectively. High frequencies are closer to daily head movements. Therefore, by examining the VOR gain (eye velocity/head velocity) and saccades, the vHIT may provide

useful information about both adaptation and compensation after a vestibular lesion (Macdougall and Curthoys).¹¹ The aim of this case study was to assess auditory and vestibular functions in a worker with a history of long-term organic solvent exposure presenting with a history of acute vertigo.

Methodology

Case Report

A 58-year-old male patient, with profound hearing loss of unknown etiology in the left ear since childhood, who had worked as an industrial painter for the past 35 years was referred to our clinic with complaints of severe unsteadiness and oscillopsia for the past year. He reported exposure to oil-based paints, lacquers, epoxy-based paints, and paint removers without the use of protection (e.g., solvent-resistant gloves and respirator masks). These components contain organic solvents such as xylenes, toluene, and methyl ethyl ketone, among others. Because of the nature of the patient's job, the exposure to organic solvents was rather intermittent. Such exposures occur when the airborne concentrations of solvents drastically increase for several minutes because of specific tasks such as mixing paints with paint thinners or other components or when solvents such as white spirits are used for cleaning purposes. Depending on the ventilation systems available in the workplace, these peak exposures can be more or less severe.

The patient also reported one major intoxication episode with paint removers (severe sudden vertigo episode that lasted several minutes) during the first five years of his career. The symptoms resolved rapidly, and he did not report any long lasting effects. He reported his first episode of sudden severe vertigo (illusion of rotation) in 2016, for which he was hospitalized and received intravenous gravol. At that time, the patient was examined by an ENT doctor and a neurologist, both of whom ruled out major otoneurological disorders confirmed by CT and MRI evaluation (e.g., vestibular schwannoma, Meniere's disease, vestibular neuritis/labyrinthitis, or multiple sclerosis). The acute symptoms of this first episode lasted about four hours, followed by unsteadiness during locomotion and head movements. In 2017, while driving in a car that was transporting paint cans, he had a second episode of severe vertigo, for which he had to stop the car. Later that day, vertigo was still present, and he was then admitted to the hospital. The acute symptoms related to this second episode lasted approximately 36 hours. During these two episodes, the patient did not report aural fullness, fluctuation in hearing, or worsening of tinnitus. Following the hospitalization, he returned to the hospital to have a caloric test (total right ear: 4°/sec; total left ear: 2°/sec) and rotary chair evaluation (reported as absent gain), both of which demonstrated hypofunction of the horizontal canal bilaterally. Since the 2017 episode, he has experienced constant dizziness and oscillopsia, which forced him to stop working for six months. At the time of this evaluation, he was back to work but still presenting limitations when moving the head horizontally and vertically (e.g., while painting a wall) or standing on ladders and presented with extreme fatigue by the end of the day. He also

reported severe difficulties with visual stimulation and in situations in which visual or somatosensory cues are reduced.

Evaluation of Auditory Functions

Tympanometry and acoustic reflexes were evaluated with a Madsen Zodiac 901 middle-ear analyzer. Air- and bone-conduction pure-tone audiometry was carried out with an Interacoustics AC40-2003 clinical audiometer along with ER-3A earphones and a Radioear B-71 bone oscillator. Pure-tone thresholds were compared with the ISO 7029 (ISO).¹⁰ Temporal processing was evaluated with both pitch pattern sequence (Pinheiro)¹⁵ and gaps-in-noise (Musiek et al)¹⁴ tests. Distortion product otoacoustic emissions (DPOAEs) were obtained for the right ear using an Otodynamics ILO-292 USB with ILO v.6 software (Hatfield, UK), connected to an HP Compaq 6730b laptop computer. Values for DPOAEs were the result of subtracting the noise floor from the DPOAE amplitudes. The auditory brainstem response (ABR) was recorded using an Intelligent Hear-ing System (Smart EP model, Miami, FL) connected to an HP ProDesk 600 G2 Mini Desktop computer. AgCl-AgCl electrodes placed on the scalp at the vertex (Cz) and the ipsilateral mastoid (A2) were used. Two trials, each averaging 2,000 responses, were obtained for the right ear using rarefaction click stimuli at 80 dBnHL at a rate of 11.1/sec. The recordings were visually inspected to identify I, III, and V waves. Considering the presence of a profound hearing loss in the left ear along with time restrictions (i.e., all vestibular and auditory tests were carried out within the same session), otoacoustic emissions and ABR were both performed in the right ear only.

Evaluation of Vestibular Functions

The peripheral vestibular evaluation first included the head impulse test (HIMP) and suppression head impulse (SHIMP) in the horizontal plane using vHIT (Eye-seecam, Interacoustics, Middlefart, Denmark). For both of these tests, gain and saccades were analyzed. A VOR gain lower than 0.79 with catch-up saccades was considered abnormal in the horizontal plane (Curthoys et al).¹ Saccades were categorized as either covert (if they occurred during head movement) or overt (if they occurred after head movement). Second, the participant received an evaluation of both the saccule and utricle using cVEMP and oVEMP (Eclipse EP-25/VEMP Interacoustics). The cVEMP and oVEMP results were interpreted according to the presence or absence of a replicable waveform using a 500-Hz tone burst at 95 dBnHL (approximately 125 peSPL) (Hsu et al).⁹

Results and Discussion

Audiological Testing

Otoscopy revealed normal external ear canal and tympanic membrane bilaterally. Type A results for tympanometry were obtained bilaterally, along with the presence of ipsilateral acoustic reflexes in the right ear at expected thresholds (Feeny and Schairer).³ Pure-tone audiometry revealed profound sensorineural hearing loss in the left ear (no behavioral response to the audiometer's output limits). Hearing thresholds in the right

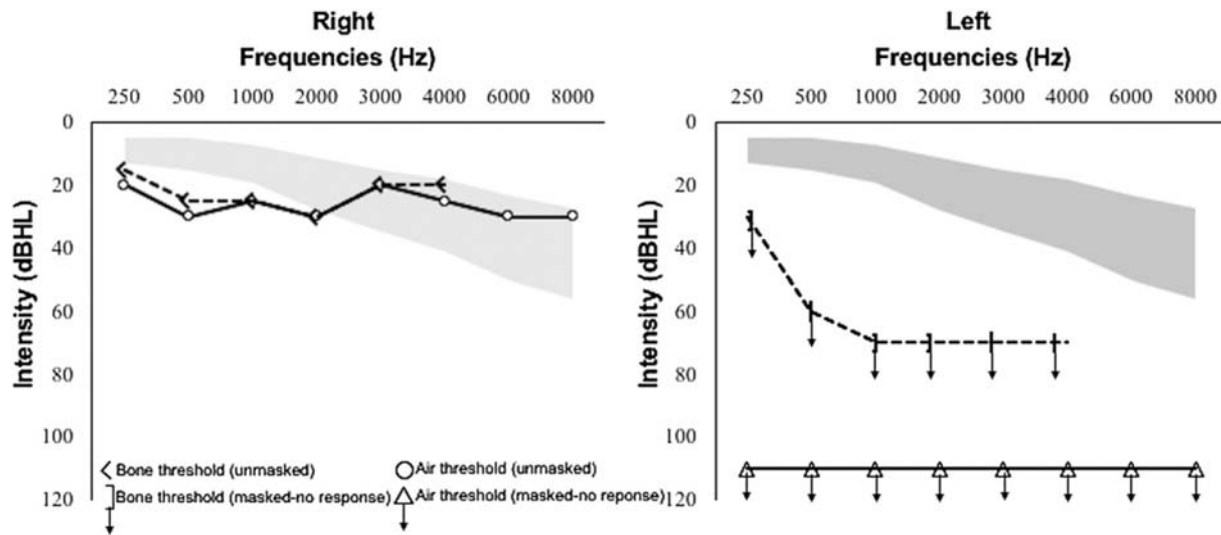


Fig. 1 Hearing thresholds of the participant for the right ear and left ear. The shaded area represents expected hearing thresholds for a 58-year-old male based on ISO 7029 (2017).¹⁰

ear for frequencies between 250 and 2000 Hz were slightly worse than expected according to the patient's age (ISO 7029)¹⁰ (► **Figure 1**). He obtained a 90% score for the pitch pattern sequence and a 5-msec gap detection threshold with 66% of correct responses across all gap durations for the gaps-in-noise. Both scores are within normal ranges (Musiek;¹³ Musiek et al).¹⁴

DPOAE in the right ear indicated the presence of emissions at 1, 1.4, 2, and 4 kHz. ABR with right ear stimulation showed the presence of I, III, and V waves. Absolute and inter-peak latencies for all components were within normal ranges (Hood).⁸

Vestibular and Postural Evaluations

cVEMP responses were absent in the right ear, but a small replicable waveform (► **Figure 2**) of amplitude 31.52 μ V was observed in the left ear. oVEMP responses were absent bilaterally (► **Figure 3**). The VEMP findings of the right ear in this study are in line with previous studies, suggesting that organic solvent exposure adversely affects otolith function (Hsu et al).⁹

HIMP revealed a low VOR gain for both horizontal semi-circular canals in addition to catch-up saccades (► **Figure 4A**). The mean VOR gain for the right and the left horizontal canals were 0.24 and 0.11, respectively. During right HIMP, most catch-up saccades were overt, whereas they were covert for left HIMP. These observations support a compensated VOR in the left ear and an uncompensated VOR in the right ear. It has been suggested that covert saccades may reduce perception of retinal slip and, therefore, may be a great asset for compensation following vestibular lesions (Macdougall and Curthoys;¹¹ Halmagyi et al)⁷ For SHIMP, similar low gains were observed bilaterally, but the catch-up saccades differed. In the right ear, anti-compensatory saccades were present during head movement and saccades following head movements were sparse. For the left ear, however, fewer anti-compensatory saccades were present during head movements and saccades following head movements were grouped and more robust (► **Figure 4B**). This may well support the hypothesis of greater compensation for the left ear than the right ear (Halmagyi et al).⁷

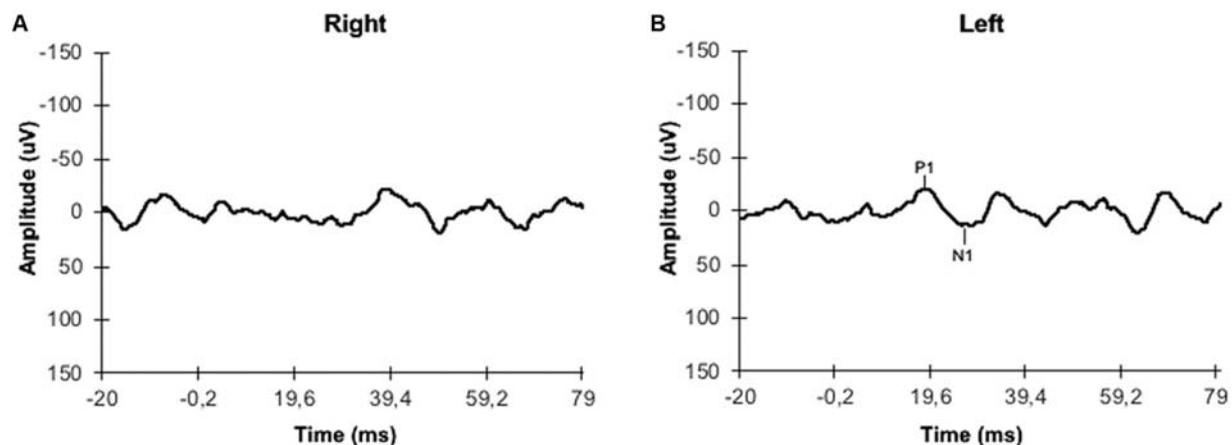


Fig. 2 Representation of the cVEMP average of two consecutive recordings for right and left ear.

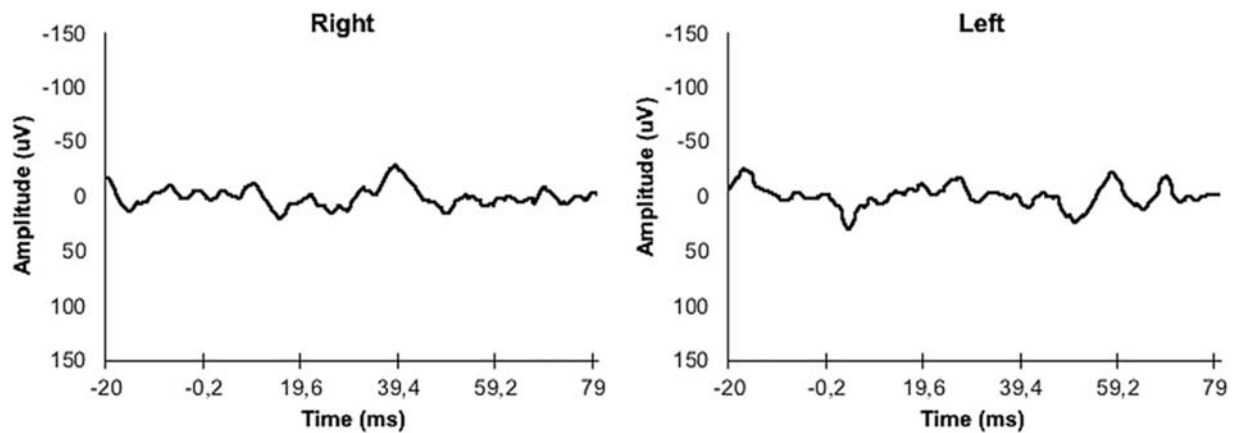


Fig. 3 Representation of the oVEMP average of two consecutive recordings for right and left ear.

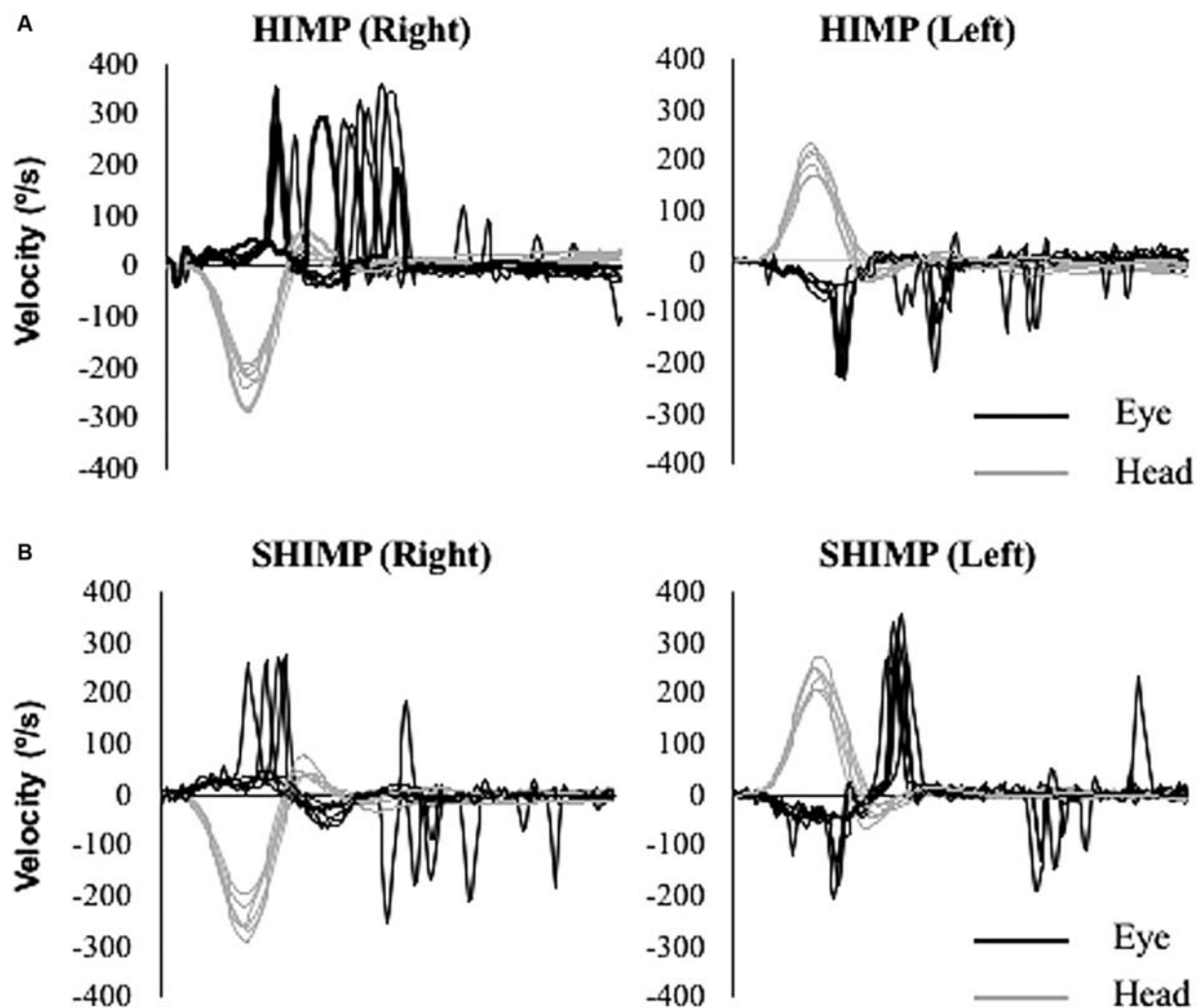


Fig. 4 (A) Representation of HIMP results for right and left horizontal canals. (B) Representation of SHIMP results for right and left horizontal canals.

In summary, he presented with longstanding profound hearing loss in the left ear and slight low-frequency hearing loss in the right ear. The profound hearing loss in the left ear was reported as an acquired hearing loss during childhood and, thus, is not associated with solvent exposure. No signs of central auditory dysfunction were found. Regarding the vestibular function, he seems to have better compensated for the

vestibular lesion in the left ear, which suggests that the onset of the dysfunction occurred earlier in life and, thus, the authors consider this likely unrelated to solvent exposure. It has been previously shown that up to 70% of children with sensorineural hearing loss may present vestibular lesion at one or more vestibular structures in the affected ear (Cushing et al;² Maheu et al).¹² It seems less likely, however, that all structures (all

three semicircular canals and both otolith organs) would be affected since childhood (Cushing et al).² Therefore, in the present case, it is possible that he had previous vestibular hypofunction in the left ear (associated with the acquired childhood sensorineural hearing loss) and that the right vestibular function was degraded by long-term exposure to organic solvents. This hypothesis is reinforced by previous investigations performed during the first episodes of vertigo that ruled out major neuro-otological disorders.

One major limitation in this study is that it was not possible to state with certainty that the left vestibular hypofunction was associated with childhood-onset hearing loss. Indeed, other causes, not related to organic solvent, may explain the sudden onset of vertigo episodes and the bilateral hypofunction (e.g., vestibular neuritis/labyrinthitis and Meniere's disease). However, these causes are less probable because they were ruled out by an ENT and a neurologist when he was hospitalized.

To the best of our knowledge, this is the first report of a patient with acute vestibular symptoms associated with solvent exposure and for whom a comprehensive vestibular and audiological test battery was used. The acute symptoms in cases of chronic solvent exposure are not commonly expected because no vestibular asymmetry is expected. However, in this specific case, the acute presentation of the symptoms may be in line with a long-term history of left vestibular dysfunction. Indeed, the function from the right vestibular end-organs was impeded by solvent exposure, which slowly deteriorated both vestibular organs. This is supported by at least two severe episodes of vertigo experienced by the patient, which could reflect the slow deterioration of the right vestibular function inducing each time a new level of asymmetry. Finally, the fact that other otoneurological disorders were ruled out by an ENT and a neurologist at the time of the hospitalization makes the hypothesis of vestibular toxicity plausible. This case study provides important clinical information about the potential deleterious effect of solvent exposure on the vestibular system.

Abbreviations

ABR	auditory brainstem response
cVEMP	cervical vestibular evoked myogenic potential
DPOAEs	distortion product otoacoustic emissions
oVEMP	ocular vestibular evoked myogenic potential
vHIT	video head impulse test
VOR	vestibulo-ocular reflex

Funding

This research was funded by the Canadian Institutes of Health Research (CIHR).

Authors' Contributions

M.M., F.C., and A.F. designed and performed the experiment. A.F. and M.M. performed data analysis. M.M., F.C., and A.F. wrote the paper. All authors discussed the results and implications and commented on the manuscript at all stages.

References

- 1 Curthoys IS, Macdougall HG, McGarvie LA, Weber KP, Szmulewicz D, Manzari L, Burgess AM, Halmagyi GM. The video head impulse test (vHIT). In: Dans Jacobson G, Shepard N, eds. *Balance Function Assessment and Management*. 2nd ed. San Diego, CA: Plural Publishing; 2016:391–430
- 2 Cushing SL, Gordon KA, Rutka JA, James AL, Papsin BC. Vestibular end-organ dysfunction in children with sensorineural hearing loss and cochlear implants: an expanded cohort and etiologic assessment. *Otol Neurotol* 2013;34:422–428
- 3 Feeney M, Schairer KS. Acoustic stapedius reflex measurements. In: Katz J, ed. *Handbook of Clinical Audiology*. 7th ed. Philadelphia, PA: Lippincott Williams & Wilkins; 2015:165–186
- 4 Fife TD, Robb MJA, Steenerson KK, Saha KC. Bilateral vestibular dysfunction associated with chronic exposure to military jet propellant type-eight jet fuel 2017 *Front Neurol* 16:351
- 5 Fuente A, McPherson B. Organic solvents and hearing loss: the challenge for audiology. *Int J Audiol* 2006;45:367–381
- 6 Giorgianni C, Tanzariello M, De Pasquale D, Brecciaroli R, Spataro G. Equilibrium disorders in workers exposed to mixed solvents. *Int J Occup Saf Ergon* 2018;25:583–586
- 7 Halmagyi GM, Chen L, Macdougall HG, Weber KP, McGarvie LA, Curthoys LS. The video head impulse test. *Front Neurol* 2017;8:258
- 8 Hood LJ. *Clinical Applications of the Auditory Brainstem Response*. San Diego, CA: Singular Publishing Group; 1998
- 9 Hsu PC, Cheng PW, Young YW. Ototoxicity from organic solvents assessed by an inner ear test battery. *J Vestib Res* 2015;25:177–183
- 10 International Organization for Standardization (ISO). *Acoustics—statistical distribution of hearing thresholds related to age and gender*. ISO 7029. Geneva: ISO; 2017
- 11 Macdougall HG, Curthoys IS. Plasticity during vestibular compensation: the role of saccades. *Front Neurol* 2012;28(21):
- 12 Maheu M, Sharp A, Pagée S, Champoux F. Congenital deafness alters sensory weighting for postural control. *Ear Hear* 2017;38:767–770
- 13 Musiek FE. Frequency (pitch) and duration pattern tests. *J Am Acad Audiol* 1994;5:265–268
- 14 Musiek FE, Shinn JB, Jirsa R, Bamiou DE, Baran JA, Zaida E. GIN (Gaps-in-Noise) test performance in subjects with confirmed central auditory nervous system involvement. *Ear Hear* 2005;26:608–618
- 15 Pinheiro M. Tests of central auditory function in children with learning disabilities. In: Keith R, ed. *Central Auditory Dysfunction*. New York, NY: Grune and Stratton; 1977:223–256
- 16 Zamysłowska-Szmytko E, Słowińska-Kowalska M. Vestibular and balance findings in nonsymptomatic workers exposed to styrene and dichloromethane. *Int J Audiol* 2011;50:815–822
- 17 Zamysłowska-Szmytko E, Poltanski P, Słowińska-Kowalska M. Balance system assessment in workers exposed to organic solvent mixture. *J Occup Environ Med* 2011;53:441–447

