

Case Report

Symptoms, Audiometric and Vestibular Laboratory Findings, and Imaging in a Concurrent Superior Canal Dehiscence Syndrome and Vestibular Schwannoma: A Case Report

DOI: 10.3766/jaaa.18076

Doug Garrison*
Laura Barth*
David Kaylie†
Kristal Riska†

Abstract

Background: Dizziness is a common complaint that can arise from multiple systems in the body. Objective vestibular tests are used to understand the underlying function of the vestibular system and whether or not it may be contributing to the dizziness symptoms experienced by the patient. Even when comprehensive case history is consistent with an otologic etiology, audiometric and vestibular tests are ordered to objectively characterize inner ear function to help further refine the differential diagnoses and aid in guiding treatment options. Few reports in the literature describe audiometric and vestibular results in patients with multiple concurrent otologic etiologies.

Purpose: This case provides a description of audiometric, vestibular, and imaging results in a case of concurrent bilateral superior canal dehiscence, right-sided vestibular schwannoma, and right-sided posterior canal benign paroxysmal positional vertigo. The patient's symptoms and laboratory findings are described in detail and, where appropriate, highlight challenges that may arise in interpretation.

Research Design: A case report.

Results: The patient presented for evaluation of dizziness, asymmetric hearing loss, and autophony. Comprehensive audiometric evaluation shows asymmetric sensorineural hearing loss and an air-bone gap at 250 Hz in the right ear. Vestibular evaluation shows right caloric asymmetry along with abnormal cervical vestibular- and ocular vestibular-evoked myogenic potentials, with the left ear showing results consistent with the third-window pathology.

Conclusions: Comprehensive assessment of symptoms and critical thinking while performing testing are necessary when examining multiple concurrent otologic etiologies in a patient. Knowledge of anticipated test results and physiology may help the audiologist to synthesize results and make appropriate clinical recommendations as part of the multidisciplinary team.

Key Words: acoustic neuroma, audiometry, benign paroxysmal positional vertigo, superior semicircular canal dehiscence, vestibular function tests, vestibular schwannoma

Abbreviations: BPPV = benign paroxysmal positional vertigo; CT = computed tomography; cVEMPs = cervical vestibular-evoked myogenic potentials; IAC = internal auditory canal; MRI = magnetic resonance imaging; oVEMPs = ocular vestibular-evoked myogenic potentials; SNHL = sensorineural hearing loss; SSCD = superior semicircular canal dehiscence; VEMPs = vestibular-evoked myogenic potentials; VS = vestibular schwannoma

*Department of Surgery, Division of Head and Neck Surgery and Communication Sciences, Duke University Hospital, Durham, NC; †Department of Surgery, Division of Head and Neck Surgery & Communication Sciences, Duke University School of Medicine, Durham, NC

Corresponding author: Doug Garrison, Department of Surgery, Division of Head and Neck Surgery and Communication Sciences, Duke University Hospital, Durham, NC 27710; Email: doug.garrison@duke.edu

INTRODUCTION

Patients presenting to neurotology clinics for dizziness often have complex symptoms. For these patients, comprehensive vestibular and audiologic assessment provides a cost-effective mechanism to describe inner ear function and to help identify patients who may benefit from diagnostic imaging, which can further refine the differential diagnosis and guide medical management. Herein, we present a unique case report of an individual with complaints of dizziness who suffered from three otologic conditions, each contributing to his dizziness symptoms.

CASE REPORT

A sixty-seven-year-old Caucasian man presented to the Duke Vestibular Disorders Clinic with a chief complaint of dizziness and autophony. His symptoms began at least three years before his consult in our clinic, and he reported a clear increase in the severity of his dizziness over the past three months. He described three types of dizziness: (a) pressure induced, (b) spontaneous vertigo lasting a few minutes, and (c) positional vertigo. Notably, the patient denied a history of Tullio phenomenon. He reported a history of pressure-induced dizziness provoked by coughing and straining, specifically during bowel movement. The patient repeatedly described his dizziness symptoms as if he may “pass out at any time.” He endorsed one episode of possible syncope. While in bed, he was coughing, and when he arose from bed, he spit in a cup and then woke up on the floor. The spontaneous vertigo that he experienced lasted for one to two minutes and was followed by approximately 15 min of mild disequilibrium. These episodes occurred weekly, and there was no discernable trigger. Finally, he reported momentary vertigo when rolling over in bed.

His audiologic history was significant for bilateral hyperacusis that increased three months before his visit. He complained of bilateral, right greater than left tinnitus, aural fullness, and autophony. He reported a history significant for occupational noise exposure in the armed services and law enforcement. The patient denied a history of unilateral noise exposure. The patient reported right-sided hearing loss, identified years ago, but there were no prior audiograms available for review.

The patient endorsed a medical history significant for migraine headache, but denied any association between migraine and dizziness. He reported a history of multiple head injuries. He was taking multiple medications, four of which have dizziness as a possible side effect according to WebMD. Those medications with reported dizziness side effects included methocarbamol, chlorthalidone, sertraline, and prazosin.

Audiologic Assessment

Audiogram confirmed the patient’s reported asymmetric hearing loss (Figure 1). The right ear showed mild sloping to severe sensorineural hearing loss (SNHL) with a 25-dB air-bone gap at 250 Hz. The left ear showed normal sensitivity through 3-kHz sloping to moderately severe SNHL. The patient had poor (52%) word recognition in the right ear using recorded NU-6 word lists presented at 100-dB nHL and excellent (96%) word recognition in the left ear at 80-dB nHL. Impedance measures showed normal equivalent ear canal volume, admittance, and tympanometric width, suggesting normal middle-ear function. Acoustic reflexes were present at a normal sensation level in all test conditions with the exception of no response to right contralateral at 2 kHz with a 105-dB stimulus. Distortion product otoacoustic emissions were entirely absent (1.6–8.0 kHz) from the right ear and present only at 1.6–2.5 kHz on the left, consistent with pure-tone results.

Vestibular Assessment

Vestibular evaluation showed multiple abnormal findings. On videonystagmography, the right Dix–Hallpike showed rightward torsional and upbeat nystagmus with a duration of 10 seconds along with vertiginous symptoms consistent with right posterior canal benign paroxysmal positional vertigo (BPPV). Bithermal water caloric examination showed minimal response from the right ear, resulting in a 62% right caloric weakness according to the formula proposed by Jongkees and Philipszoon (1964) (Figure 2). Ocular motor examination was within normal limits. There was no gaze-evoked or spontaneous nystagmus.

Given the patient’s complaints of strain-induced dizziness, vestibular-evoked myogenic potentials (VEMPs) were completed. Cervical VEMPs (cVEMPs) showed a present response, bilaterally, to 100-dB nHL stimuli. The amplitude asymmetry was 37%, which was within the asymmetry cutoff (43%) for this clinic. The stimulus level was decreased and the cVEMP response threshold was found to be 95-dB nHL in the right ear and 70-dB nHL in the left ear (Figures 3A and B). Ocular VEMPs (oVEMPs) were present and abnormally large in the left ear with a response amplitude of 103 μ V, whereas in the right ear, no response was recorded (Figures 3C and D). Ocular VEMPs were also recorded in response to 4-kHz stimuli in the left ear and measured to be 21 μ V (Figure 3E). During testing, the patient commented that high-intensity sound to the left ear only caused dizziness. The patient scored 74/100 on the Dizziness Handicap Inventory, indicating his

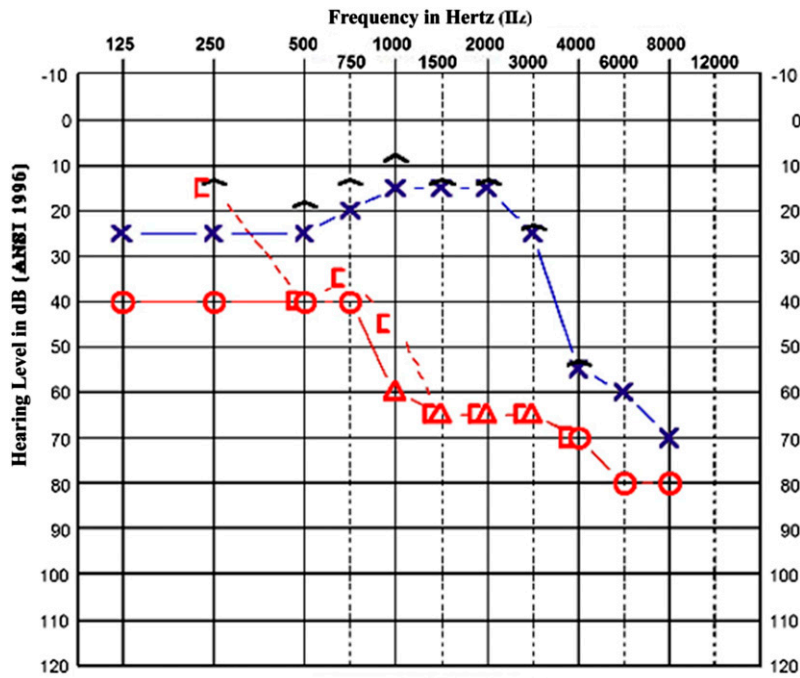


Figure 1. Pure-tone audiometry demonstrated asymmetric hearing loss (right ear poorer than left) with an air-bone gap at 250 Hz in the right ear that is poorly explained by immittance measures. (This figure appears in color in the online version of this article.)

dizziness had a severe negative impact on his daily activities.

within the left internal auditory canal (IAC) were normal without enhancement.

Imaging

The patient underwent both computed tomography (CT) scan and magnetic resonance imaging (MRI) to further elucidate the etiology of the patient’s complaints, given the multiple abnormal test findings. His CT scan showed bilateral superior semicircular canal dehiscence (SSCD) (Figure 4). The radiologist confirmed the presence of a dehiscence, bilaterally, but the size is not documented in the radiology record. His MRI (Figure 5) was an axial T1-weighted image with gadolinium contrast and showed enhancement of the right internal auditory canal consistent with a 9-mm intracanalicular vestibular schwannoma (VS). The structures

DISCUSSION

This case was unique because there were multiple confirmed otologic findings—bilateral SSCD, right-sided VS, and right-sided BPPV. To the authors’ knowledge, combined SSCD and VS has only been described in the literature once, and in that case, the SSCD was unilateral on the same side as the VS (Aaron et al, 2015). That case apparently did not use vestibular testing to aid in the diagnosis, and the treatment options were quite different from our patient. The retrospective review of this case shows four critical steps to arrive at the appropriate diagnosis and management plan.

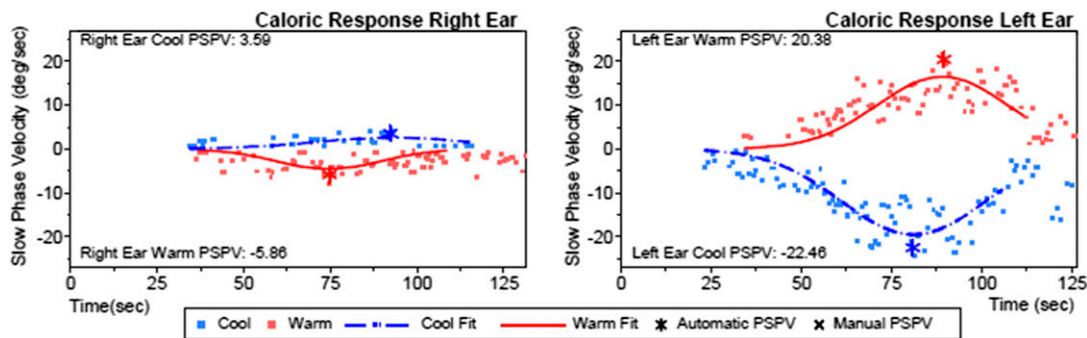


Figure 2. Caloric butterfly plot showing bithermal water caloric irrigation resulting in 62% right unilateral weakness. (This figure appears in color in the online version of this article.)

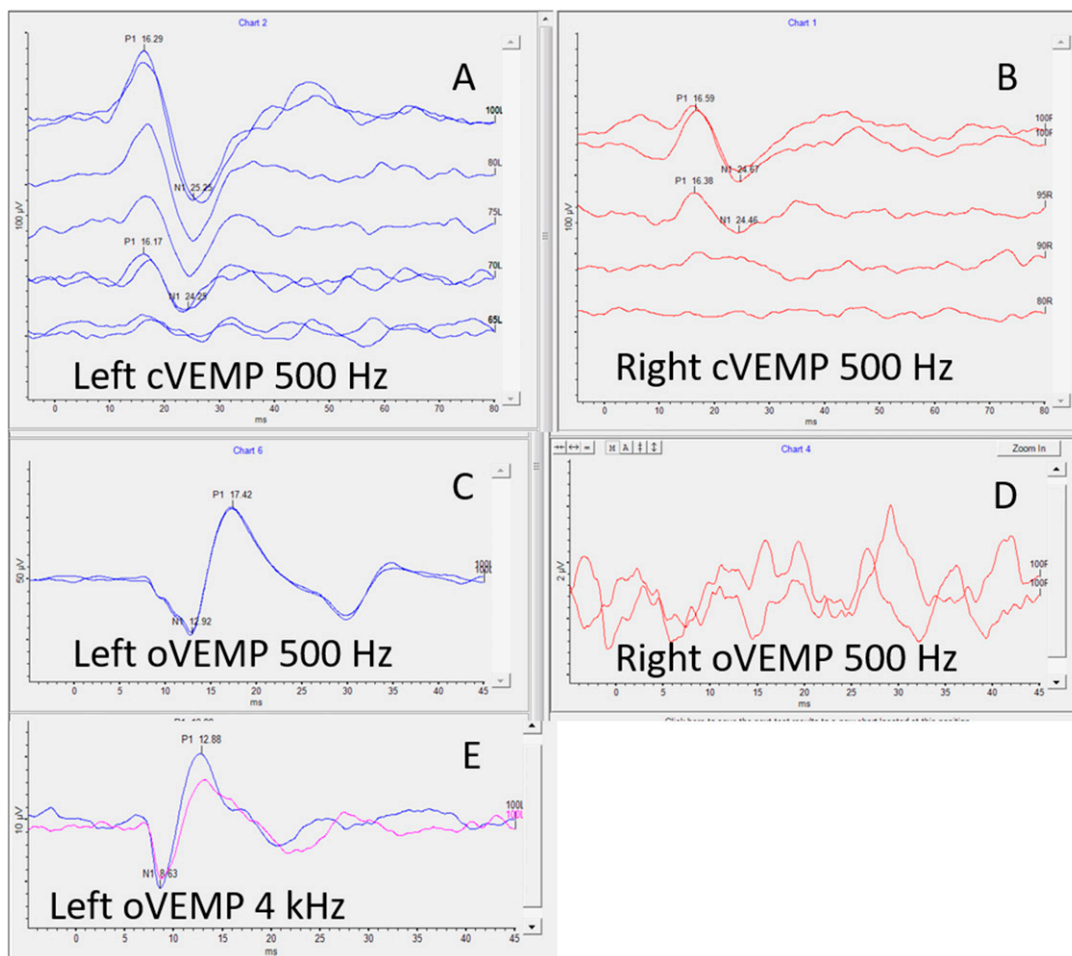


Figure 3. cVEMP/oVEMP responses. Stimulus intensities are displayed on the right side of each waveform. In panel A (left ear), the cVEMP response is present at 100-dB nHL at an amplitude of 196.7 μ V and a threshold of 70-dB nHL. In panel B (right ear), the cVEMP response is present at 100-dB nHL at an amplitude of 90.5 μ V and a threshold of 95-dB nHL. Panel C (left ear response) shows a present 500-Hz air-conducted oVEMP with an amplitude of 103.8 μ V. Panel D (right ear response) shows absent oVEMP to 500-Hz stimuli. In panel E, oVEMP responses from the left ear are present to 100-dB nHL 4-kHz stimulation with an amplitude of 21.5 μ V. (This figure appears in color in the online version of this article.)

Case History

Historically, the case history has been viewed as the most important component in both the triage of dizziness and the diagnosis of dizziness in medical settings (Goebel, 2001; Post and Dickerson, 2010; Fife, 2017). However, given the complexity of many dizzy patients, the case history is often not sufficient and additional objective data are necessary to clearly diagnose and/or confirm suspected diagnosis. In our patient, the case history alone simply did not identify all of the etiologies contributing to his symptoms. There were many symptom descriptors that pointed to potentially different etiologies. For example, the patient reported one- to two-minute episodes of vertigo that occurred spontaneously. Although the short duration of the vertigo may suggest certain etiologies (i.e., BPPV and SSCD), the fact that he did not have specific triggers

made this particular symptom difficult to isolate to a specific pathology. He also reported rotary vertigo when rolling in bed. This was taken as a clear sign of BPPV. However, in the authors' clinical experience, patients with a third-window pathology often describe dizziness when moving from sitting to laying, presumably due to sudden change in intracranial pressure following that movement. His autophony and dizziness with strain were the most convincing symptoms for a third-window pathology; however, the more symptomatic ear was not clear based on history alone. His report of asymmetric hearing loss was concerning for VS; however, his recall regarding onset was vague and his history of noise exposure offers a plausible alternative explanation. The patient provided a complicated history, and additional diagnostic measures were necessary to understand the underlying function in this patient.

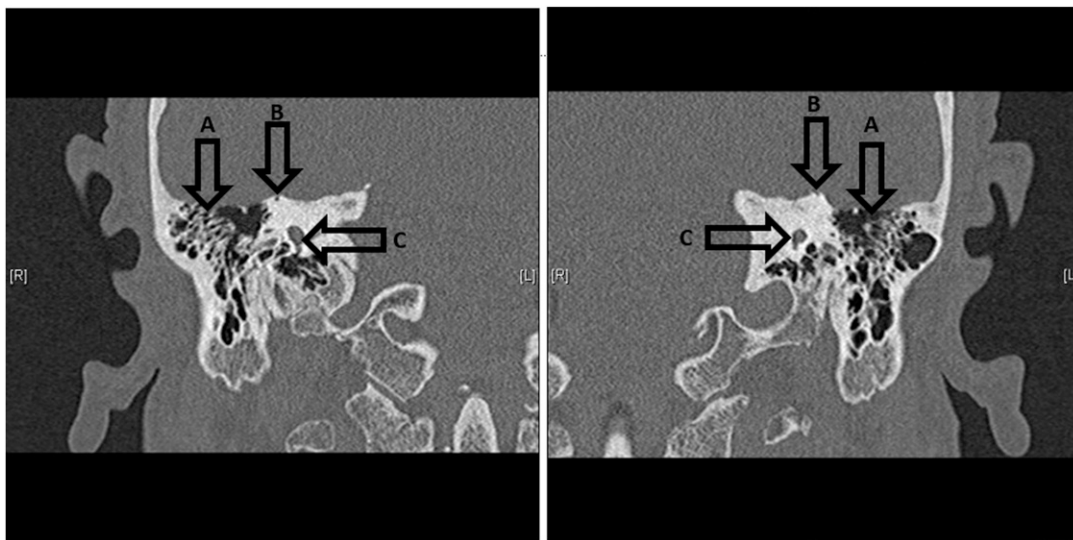


Figure 4. Coronal CT scan image showing evidence of bilateral SSCD. The image on the left is the right ear, and the image on the right is the left ear. Arrows show anatomical landmarks for both ears. A = mastoid air cells, B = SSCD (divot indicates lack of bone where the roof of the superior semicircular canal meets the floor of the middle cranial fossa), and C = vestibule. [R] = patient right ear and [L] = patient left ear.

Audiometric and Vestibular Evidence to Support VS

The most common clinical manifestation of VS is unilateral SNHL, often in association with tinnitus (Lin et al, 2005). Most patients’ hearing loss is concentrated in the high frequencies and often this progresses slowly; however, one quarter of patients will experience sudden hearing loss (Selesnick et al, 1993). This patient’s

audiogram showed a large sensorineural pure-tone asymmetry, the timing of which is unclear, suggesting a progressive onset. Hearing-impaired patients with a retrocochlear etiology often perform poorer on word recognition tasks at relatively higher suprathreshold stimulus intensities, that is, rollover. This patient did show poor (52%) word recognition scores at the 100-dB HL presentation level in the right ear; however, multiple word lists to assess for rollover were not collected, as is often the case in a busy clinical environment. His video-nystagmography examination, in addition to the right posterior canal BPPV, showed a large caloric asymmetry which agrees with the pure-tone findings lateralizing to the right. The patient had present cVEMP responses and absent oVEMP responses when stimulating the right ear, indicating impairment of the superior portion of the vestibular nerve and preservation of the inferior portion of the vestibular nerve. Furthermore, the presence of posterior canal BPPV confirms preservation of the inferior vestibular nerve function. Laterality of the vestibular deficit agrees well with the asymmetric SNHL, furthering support for retrocochlear pathology.

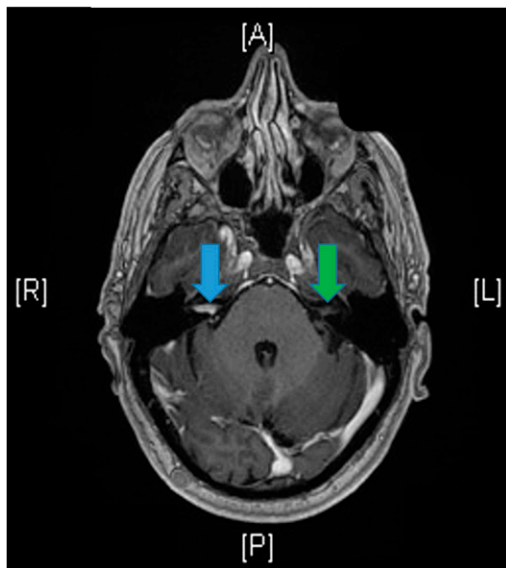


Figure 5. T1-weighted MRI with gadolinium contrast in the axial plane at the level of the IAC. The blue arrow points to enhancing intracanalicular VS on the right that was measured to be 9 mm. The green arrow points to nonenhancing IAC on left. [A] = anterior, [P] = posterior, [R] = right, and [L] = left. (This figure appears in color in the online version of this article.)

Audiometric and Vestibular Evidence to Support SCD

SSCD was first described by Minor et al (1998) as a potential etiology in patients with Tullio phenomenon or Hennebert’s sign. Additional symptoms include autophony, hyperacusis, conductive hyperacusis, and aural fullness (Yuen et al, 2009). Of a study of 65 patients with confirmed SSCD, 60/65 had vestibular

This document was downloaded for personal use only. Unauthorized distribution is strictly prohibited.

manifestations, 54/60 experienced Tullio phenomenon, and 44/60 experienced pressure-induced symptoms (Minor, 2005). This is in line with the findings of this case as the patient's chief complaints were pressure-induced dizziness and autophony. Minor's work continues to describe air-bone gaps as a common finding in these patients. The most commonly reported frequencies for air-bone gaps are 250 Hz (70%), followed closely by 500 Hz (68%) and 1000 Hz (64%) (2005). In our patient, the only air-bone gap was at 250 Hz and was only present on the right. His VEMPs offered compelling evidence of a third-window pathology in the left ear. In our clinic, we perform multiple electrophysiological measures, that is, vestibular and audiometric testing, to screen for SSCD in advance of more expensive imaging. More specifically, in cases suspicious for SSCD, our present clinical protocol calls for a progressive combination of VEMP measures, including 500-Hz cVEMP threshold, 500-Hz oVEMP amplitude, and the presence of oVEMP response to 4-kHz stimuli. This is based on reports from Zuniga et al (2013) who reported oVEMP amplitudes were more sensitive to SSCD than cVEMP thresholds and from Manzari et al (2013) who showed the presence of oVEMPs to high-frequency stimuli was another measure capable of predicting the diagnosis. This patient's VEMP data were consistent with the third-window pathology for the left ear as he meets all three of the aforementioned criteria and, moreover, he voluntarily reported oscillopsia during testing for that side only. In the right ear, VEMPs were not consistent with the third-window pathology despite an air-bone gap at 250 Hz that was not supported by immittance measures.

Merchant and Rosowski (2008) offer an excellent theory of the physiology of third-window pathologies, and the interested reader is directed there for a more comprehensive description. They offer an explanation of the air-bone gap by describing a change in impedance across the cochlear partition resulting in exaggerated movement of the basilar membrane to bone conduction and attenuated movement of the basilar membrane to air conduction. They theorize the dizziness symptoms arise as acoustic energy escapes an otherwise enclosed cochlea, activating sensory receptors of the vestibular system as it exits through a third window of the bony labyrinth. After review of 1,000 temporal bones, Carey et al (2000) found 0.5% of specimens with true dehiscence and another 1.4% with markedly thin (<0.1 mm) temporal bones that could be mistaken for dehiscence on CT scan. The etiology of SSCD is still debated. After ruling out multiple potential causes, the most likely theory is "postnatal failure to develop outer- and/or middle-layer bone over the superior canal" (Carey et al, 2000). The authors go further to suggest this may cause dehiscence or thinning that subsequently becomes dehiscence

through environmental factors such as sudden change in intracranial pressure or head injury (Carey et al, 2000).

Diagnostic Imaging to Clarify Diagnosis and Laterality

In our patient, the diagnostic workup (i.e., pure-tone and caloric asymmetry) was suggestive of retrocochlear pathology on the right and VEMP testing was convincing for the third-window pathology on the left. Some diagnostic testing on the right were seemingly incongruent as the patient showed an air-bone gap unexplained by immittance but negative VEMP findings, which supported and opposed third-window pathology, respectively. When this was combined with lack of air-bone gap yet positive VEMP findings on the left, the discerning clinician is compelled to stop and check for technical sources of error.

Having reached the limits of diagnostic audiometric and vestibular assessment, imaging provided additional clarity. MRI confirmed the suspicion of right-sided retrocochlear pathology; the intracanalicular VS measures 9 mm. The CT scan showed bilateral SSCD. It is worth considering vestibular physiology on the right specifically as there were two interesting pathologies in one ear. The VS was impinging on the nerve, resulting in deficient reflexes. The third-window of the same ear allowed for larger than expected VEMP amplitudes because of reduced impedance across the basilar membrane for air conduction stimuli. One might speculate that in this case, the impingement of the vestibular nerve by an intracanalicular VS would be sufficient to abolish the cVEMP altogether if not for the pathologic third window that allows greater than normal stimulation of the otolith organs, thereby sustaining the reflex, but only for high-intensity stimuli, which is unremarkable when viewed in isolation. In our case, the true etiology is unknown without imaging.

Treatment

The patient was treated with right Epley maneuver and the movement-provoked symptoms resolved. Surgical removal of the VS via translabyrinthine approach and concurrent repair of the right superior semicircular canal were considered. The patient's hearing loss, poor speech discrimination, and weak caloric responses provided objective evidence of preexisting impairment, implying the vestibular loss following translabyrinthine surgery would be minimal. However, poor vestibular compensation after removal of VS is always a concern, especially in the context of contralateral pathology. It has been reported that bilateral SSCD repair, while improving pressure and sound-induced vertigo, often results in oscillopsia (Agrawal et al, 2012). This patient's chief complaint was autophony and dizziness

with strain, suggesting the SSCD was the most distressing pathology. Indeed, it is possible that the VS was contributing little if at all to the patient's dizziness complaints at the present time.

After discussing risks and benefits with the surgeon, the patient decided to undergo a right transmastoid repair of the superior canal dehiscence. Briefly, a mastoidectomy was performed, which exposed all three semicircular canals. The anterior and posterior limbs of the superior canal were clearly identified. Intraoperative ABR was performed. Each limb was slowly drilled until the bone over the lumen of the canal was transparent. The bone was picked open, and the lumen was gently packed with bone dust and bone wax. ABR was checked before packing each limb and at the completion of the case. He did not have any change in his ABR. He was seen three weeks postoperatively and had no significant change in his hearing in the right ear. He reported near complete resolution of his vertigo and disequilibrium. At his last follow-up visit, three months after surgery, he reported he was able to resume all of his old activities without any restrictions. He did not report any symptoms on his left side.

CONCLUSION

Herein, the case presented shows the overlay, and subsequent presentation, of two rare otologic pathologies (SSCD and VS) combined with a common otologic condition (BPPV). Although the prevalence of bilateral SSCD in conjunction with unilateral VS is unknown, it is thought to be rare. This highlights the importance of a thorough case history, in conjunction with full audiologic, vestibular, and otologic care to ensure that apparently incidental symptoms and pathologies are not overlooked.

Multidisciplinary care teams are an essential component of tertiary care centers. This case involved multiple providers with each providing insight and expertise, leading to the diagnosis and management of a complex neurotologic case. The case history was a useful component; however, additional objective measures were required to identify underlying inner ear function and to understand the patient's various symptoms. The audiometric workup presented critical objective measures regarding the status of the auditory portion of the eighth cranial nerve and the bony labyrinth. This information was used to guide the vestibular examination and aided in the interpretation of vestibular test findings. Moreover, the auditory and vestibular testing provided

useful information to the surgical team that was used to aid in determining the treatment options and counseling of the patient on potential outcomes.

REFERENCES

- Aaron KA, Lavinsky J, Tuchman A, Go JL, Giannotta SL, Friedman RA. (2015) A case report of two different skull base pathologies causing hearing loss in the same ear: vestibular schwannoma and superior semicircular canal dehiscence. *Am J Otolaryngol* 36(3):488–491.
- Agrawal Y, Minor L, Schubert M, Janky K, Davalos-Bichara M, Carey J. (2012) Second-side surgery in superior canal dehiscence syndrome. *Otol Neurotol* 33(1):72–77.
- Carey J, Minor L, Nager G. (2000) Dehiscence or thinning of bone overlying the superior semicircular canal in a temporal bone survey. *Arch Otolaryngol Head Neck Surg* 126:137–147.
- Fife TD. (2017) Dizziness in the outpatient care setting. *Continuum (Minneapolis)* 23(2):359–395.
- Goebel JA. (2001) The ten-minute examination of the dizzy patient. *Semin Neurol* 21(4):391–398.
- Jongkees LBW, Philipszoon AJ. (1964) Electronystagmography. *Acta Otolaryngol Suppl* 189:1–111.
- Lin D, Hegarty JL, Fischbein NJ, Jackler RK. (2005) The prevalence of “incidental” acoustic neuroma. *Arch Otolaryngol Head Neck Surg* 131(3):241–244.
- Manzari L, Burgess AM, McGarvie LA, Curthoys IS. (2013) An indicator of probable semicircular canal dehiscence: ocular vestibular evoked myogenic potentials to high frequencies. *Otolaryngol Head Neck Surg* 149:142–145.
- Merchant S, Rosowski J. (2008) Conductive hearing loss caused by third-window lesions of the inner ear. *Otol Neurotol* 29:282–289.
- Minor L, Solomon D, Zinreich J, Zee D. (1998) Sound- and/or pressure-induced vertigo due to bone dehiscence of the superior semicircular canal. *Arch Otolaryngol Head Neck Surg* 124:249–258.
- Minor L. (2005) Clinical manifestations of superior semicircular canal dehiscence. *Laryngoscope* 115:1717–1727.
- Post RE, Dickerson LM. (2010) Dizziness: a diagnostic approach. *Am Fam Physician* 82(4):361–368.
- Selesnick S, Jackler R, Pitts L. (1993) The changing clinical presentation of acoustic tumors in the MRI era. *Laryngoscope* 103:431–436.
- Yuen H, Boeddinghaus R, Eikelboom R, Atlas M. (2009) The relationship between the air-bone gap and the size of superior semicircular canal dehiscence. *Otolaryngol Head Neck Surg* 141:689–694.
- Zuniga G, Janky K, Nguyen K, Welgampola M, Carey J. (2013) Ocular versus cervical VEMPs in the diagnosis of superior semicircular canal dehiscence syndrome. *Otol Neurotol* 34(1):121–126.