

Successful treatment of a necrotizing, multi-resistant bacterial pyoderma in a python with cold plasma therapy

Christoph J. Klinger¹; Berrett Dengler¹; Thomas Bauer²; Ralf S. Mueller¹

¹Small Animal Medicine Clinic, Centre for Clinical Veterinary Medicine, Ludwig-Maximilian University, Munich, Germany;

²Veterinary practice, Munich, Germany

Keywords

Non-thermal plasma, atmospheric pressure plasma, dermatology, reptiles, *Stenotrophomonas maltophilia*, *Xanthomonas*

Summary

A 4-year-old ball python was presented 3 weeks after multiple bite wounds from a prey rat with large skin lesions, a concurrent deep bacterial pyoderma and clinical signs for septicemia, including neurological symptoms. Affected tissue separated from the underlying muscular layer revealing parts of the muscles. Clinical examination and cytology was consistent with bacterial pyoderma; septicemia was an additional tentative clinical diagnosis. Empirical lincomycin and marbofloxacin (bacterial culture revealed a multi-resistant *Stenotrophomonas maltophilia* susceptible to fluoroquinolones) treatment improved the patient's general condition but skin wounds deteriorated to multifocal eschars with intracellular rods. Further diagnostics were limited for financial reasons, euthanasia was considered. Cold atmospheric pressure plasma (CAPP) therapy was performed six times in 4 weeks. Within 1 week, inflammatory symptoms resolved. Re-epithelialization was completed few weeks later. In the following year, the snake sloughed three times without any signs of dysecdysis. CAPP therapy may offer a viable treatment option for bacterial (especially multi-resistant) pyoderma and necrotizing dermatitis in snakes.

Schlüsselwörter

Kaltplasma, Atmosphärendruckplasma, Dermatologie, Reptilien, *Stenotrophomonas maltophilia*, *Xanthomonas*

Zusammenfassung

Ein 4-jähriger Königspython wurde 3 Wochen nach Bissverletzungen durch eine Ratte mit großflächigen Hautläsionen und einer bakteriellen Pyodermie mit Anzeichen einer Sepsis und neurologischen Symptomen vorgestellt. Die betroffene Haut löste sich von der Muskulatur, wodurch Teile des Muskelgewebes frei lagen. Klinische und zytologische Untersuchung ergaben eine bakterielle Pyodermie. Sepsisverdacht bestand aufgrund der klinischen Symptomatik. Die empirische Behandlung mit Lincomycin und Marbofloxacin (Befund der bakteriologischen Untersuchung waren multiresistente *Stenotrophomonas maltophilia*, sensibel gegenüber Fluorchinolonen) verbesserte das Allgemeinbefinden und die Hautläsionen demarkierten sich zu Brandschorf mit intrazellulären stäbchenförmigen Bakterien. Eine weiterführende Diagnostik konnte kostenbedingt nicht durchgeführt werden und die Euthanasie des Tieres wurde erwogen. Im Verlauf von 4 Wochen erfolgte sechsmal eine Behandlung mit Kaltplasma (cold atmospheric pressure plasma, CAPP). Innerhalb einer Woche verbesserten sich die Entzündungssymptome. Die Reepithelisierung war wenige Wochen später abgeschlossen. Drei Häutungen im Folgejahr verliefen ohne Anzeichen von Dysecdysis. CAPP könnte bei Schlangen mit bakteriellen Pyodermien (insbesondere mit resistenten Keimen) und Hautnekrosen eine nützliche Behandlungsoption darstellen.

Correspondence to

Dr. med. vet. Christoph Jan Klinger
Medizinische Kleintierklinik
Zentrum für Tiermedizin
Ludwig-Maximilians Universität München
Veterinärstraße 13
80539 München
Germany
Email: c.klinger@medizinische-kleintierklinik.de

Erfolgreiche Behandlung einer nekrotisierenden, multiresistenten bakteriellen Pyodermie bei einem Python mittels Kaltplasmatherapie
Tierärztl Prax Ausg K Kleintiere Heimtiere 2018; 46: 43–48
<http://dx.doi.org/10.15654/TPK-170190>

Received: March 8, 2017

Accepted after revision: May 26, 2017

Introduction

Ball pythons (*Python regius*, SHAW 1802) are an oviparous, non-venomous constrictor snake species inhabiting sub-Saharan Africa (36). Being amongst the smallest African giant snakes and comparatively docile, unless threatened, they make popular pets.

Bacterial infections are a common problem in reptiles (6) and are commonly caused by Gram-negative rods (31). Some of those bacteria – regardless of the host – bear a high potential to develop antibiotic resistance even without prior antibiotic usage (29, 30). In many cases systemic antibacterial therapy is needed, as topical medication or disinfectant bathing is either poorly tolerated, inef-

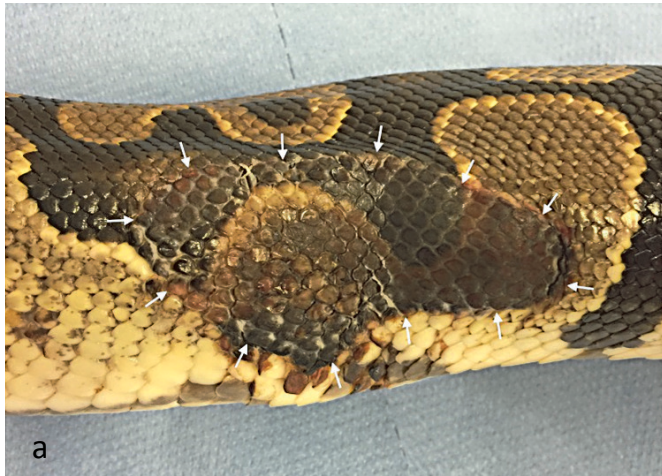


Fig. 1 Clinical presentation of the ball python. a) Sharply demarcated, necrotic skin area at the right flank in the middle of the body. b) Partially detaching eschar at the thorax revealing the underlying muscle layer.

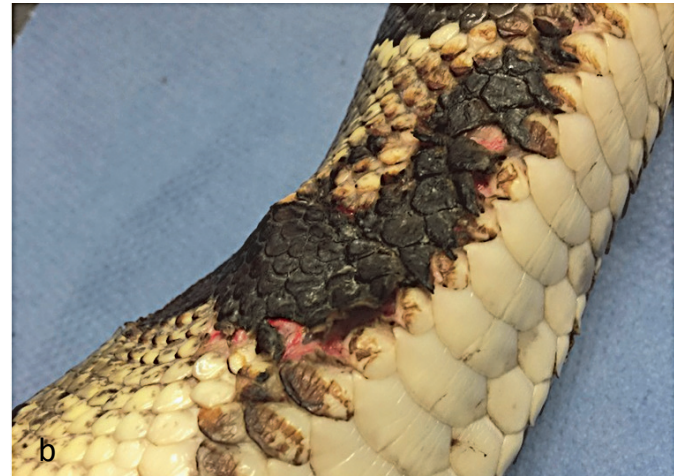

Abb. 1 Klinisches Bild des Königspythons. a) Scharf demarkiertes, nekrotisierendes Hautareal an der rechten Flanke im mittleren Körpersegment. b) Sich teilweise ablösender Brandschorf an der Brustwand mit Freilegung der darunterliegenden Muskulatur.

fective (16, 33) or does not penetrate the very thick, protective stratum corneum (19, 24). Many reptilian species rapidly develop adverse reactions with some antibiotics such as nephrotoxicity (26). Euthanasia sometimes has to be considered a reasonable option as ultima ratio.

Stenotrophomonas maltophilia is an ubiquitous, aerobic, Gram-negative, rod-shaped bacterium of the family Xanthomonadaceae, which has been reported to induce severe septicemic infections in reptiles (1, 11) and commonly shows multi-drug resistance (6).

Cold atmospheric pressure plasma (CAPP) is a relatively new and innovative therapeutic option with physical antimicrobial activity and wound healing properties (37). It can be considered as a gas mixture of electrons and ions in combination with neutral and highly reactive molecules such as free radicals, peroxide and UV-photons (9, 20). CAPP inactivates bacteria regardless of their resistance to antimicrobial agents, such as methicillin-resistant *Staphylococcus aureus* and *Pseudomonas aeruginosa* (2) and also affects bacterial biofilms, bacteriophages, and bacterial and fungal spores (18, 35).

This case report describes a ball python infected with a multi-resistant *Stenotrophomonas maltophilia* successfully treated with CAPP in combination with local therapy. To the best of the authors' knowledge, this is the first case report of CAPP therapy for a multi-drug resistant bacterial infection in a reptile.

Case description

History and clinical presentation

A female, 1.5 m long, 4-year-old ball python was presented due to anorexia, lethargy and nine large and multiple small, partially ulcerated skin areas with puncture wounds all over the body. The owner reported regularly placing live rats inside the vivarium as

a food source. Three weeks prior to this first presentation to the reptile specialist, the owner observed the prey rat causing multiple bite wounds, when the python darted for it. The snake did not kill and consume this rat, which was subsequently removed. The owner confirmed there was no contactable heat source and no sharp objects within the vivarium which could have caused the skin wounds.

The snake was underweight, did not resist the general examination and displayed an opisthotonus. When positioned in dorsal recumbency, the patient showed no compensating movements to right itself. Ventrally, multifocal small spots of subcutaneous hemorrhage were noted. The size of the wounds ranged from 1 cm² up to 15 x 7 cm.

Diagnostic approach, treatment and outcome

Cytology of specimens sampled directly from small ulcers revealed heterophils and intracellular rod-shaped bacteria consistent with bacterial pyoderma. Petechia and neurological signs were suggestive for septicemia. The patient was hospitalized and swabs taken from the muscle surface underneath larger skin wounds were sent to a commercial laboratory for bacteriology and susceptibility testing. Due to financial constraints, the owner refused any further tests.

Intramuscular injections of marbofloxacin (Marbocyl® 2%, Vetoquinol, Magny-Vernois, France) at 4 mg/kg/d (initially 8 mg/kg once) and lincomycin (Lincobel® 113.4 mg/ml, bela-pharm GmbH & Co. KG, Vechta, Germany) at 10 mg/kg/d were initiated empirically in combination with subcutaneous infusion with a physiological electrolyte solution (Ringer-Lactat-Lösung nach Hartmann®, B. Braun Vet Care, Melsungen, Germany) at 10 ml/kg/d. Concurrent topical silver-sulfadiazine creme (Flammazine®-1%, Sinclair Pharma GmbH, Frankfurt/Main, Germany) was applied

twice daily after the snake had been bathed in highly concentrated black tea (cooled down to 25 °C). The culture revealed an abundant but high amount of *Stenotrophomonas maltophilia* resistant to all antibiotics except for fluoroquinolones, trimethoprim-sulfonamides and chloramphenicol/florfenicol. Both systemic and topical therapy was continued for 1 week and a guarded prognosis was given.

Ten days later, the patient had improved in its general condition, and was now able to right itself when turned on its back. However, the skin wounds had worsened with multifocal full-thickness skin eschar and sloughing, revealing muscles (▶ Fig. 1). The patient was referred to dermatology for an alternative to euthanasia. Cytology from the muscle surface revealed large numbers of heterophils and intracellular rods. No further tests were allowed by the owner. Treatment with CAPP (kINPen VET®; neoplas GmbH, Greifswald, Germany) was proposed for disinfection and induction of wound healing. This was performed for 15 s/cm² with a jet-wound distance of 10 mm three times weekly for 2 weeks (▶ Fig. 2). The topical silver-sulfadiazine therapy was continued as supportive treatment following CAPP; tea baths and systemic antibiotics were discontinued.

After 7 days, granulation tissue was visible at the wound edges and on cytology, bacteria were now absent. After 14 days, the necrotic areas had decreased in size by approximately 50%, with no further tissue sloughing. CAPP therapy was discontinued after another 2 weeks of once weekly administration. Two months later, all skin lesions had completely resolved, leaving only residual scars which did not create any problems with dysecdysis in the subsequent 12 months (▶ Fig. 3).

Discussion

Feeding living prey carries risks, as prey animals oftentimes defend themselves by biting or scratching (4). It is a controversial issue even amongst experts due to the possible injuries to the snake (4) and ethical concerns for the captive prey (German Law, Art. 4 Abs. 3 TSchV). Changing the food source to killed or frozen-thawed was recommended to the owner.

The owner observed direct bites by the prey rat and the wounds at the initial presentation to the referring veterinarian, a reptile specialist, were considered consistent with deep puncture wounds.

Captive ball pythons frequently develop anorexia if stressed and can fast for months, particularly during the breeding season, before ecdysis and in cases of environmental changes within the vivarium, illness or external stress factors (39). The vivarium of this python was however designed very precisely and no risk factors for anorexia or skin injuries were noted. Possible sharp objects within the vivarium or skin necrosis due to a heat source/environmental burn were excluded historically.

Very few pharmacokinetic studies have been conducted in reptiles and antibiotic doses are frequently based on empirical experience and anecdotal information (23). Fluoroquinolones are regu-

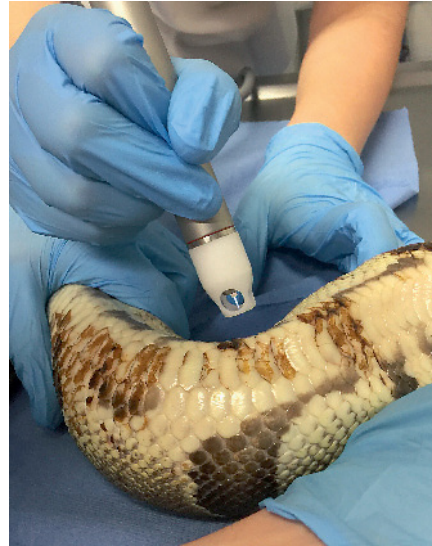

Fig. 2 Process of cold plasma therapy (necrotic skin area not visible due to angle of photo). Each square centimeter was treated for 15 seconds.

Abb. 2 Durchführung der Kaltplasmatherapie (nekrotisches Hautareal aufgrund des Fotografiewinkels nicht sichtbar). Jeder Quadratzentimeter wurde über 15 Sekunden behandelt.

larly used to treat bacterial infections in snakes despite the limited pharmacokinetic data available (40). They are effective against most aerobic bacteria in reptiles, and distribute to all tissue including bone and inflammatory tissues (27). Adverse effects to fluoroquinolones are very uncommon in reptiles, though pain and in-



Fig. 3 Condition of the patient after 4 months. Despite scar tissue persisted on the former wounds, the snake has shown no symptoms of dysecdysis.

Abb. 3 Zustand des Patienten nach 4 Monaten. Obwohl Narbengewebe an den ehemaligen Wundstellen verblieb, zeigte die Schlange keine Anzeichen für Dysecdysis.

flammation at the injection site are reported (25). Almost all the anaerobes isolated from snakes were sensitive to macrolide antibiotics (34).

Multi-resistant bacteria are an increasing worldwide problem (7), at least partially due to frequent antibiotic usage (17). Antibiotic stewardship recommendations include an initial single-antibiotic approach (5, 13). However, in this patient septicemia with neurologic signs and high risk of imminent death made aerobic as well as anaerobic bacteria plausible causative agents. With no available single product licensed for intramuscular injections targeting both bacteria types, a double-antibiotic approach was started prior to the susceptibility test results.

Stenotrophomonas (S.) maltophilia can create devastating infections and even septicemia in immunocompromised patients (1) and has been reported to induce severe infections in reptiles (11), but can be a part of the normal oral bacterial flora of snakes (12). It remains unknown whether the bacterial infection originated from the prey rat bite or was due to self-trauma by the python during the fight with the rat.

It could not be elucidated, if *S. maltophilia* caused both the systemic and neurologic signs or just the skin ulcers as recommended defining tests including blood cultures, complete blood count, serum biochemistry, deep tissue cultures, and histopathology were declined by the owner due to financial constraints. As the skin wounds deteriorated despite improvement in the general condition, a lack of antimicrobial penetration by the systemic antibiotics possibly due to tissue necrosis and/or bacterial resistance to the topicals was suspected. A fungal infection could not be ruled out, as a fungal culture could not be initiated. In fungal infections, a histiocytic inflammation would have been expected and no fungal elements were identified on cytology. Thus, the sudden onset of the disease in combination with the heterophilic inflammation and the bacteria identified rendered a bacterial infection more likely. Viral infections are another possible cause for neurologic signs in giant snakes. However, the patient was kept as a sole pet for 3 years and with the timely association of the skin infection to the bite wounds, a bacterial pathogen appeared more likely, especially in light of the clinical outcome. In addition, there were no intracytoplasmic or intranuclear inclusion bodies visible on skin cytology. Virus antibody as well as spinal fluid testing was not permitted due to financial constraints.

CAPP is an emerging, painless and well-tolerated, therapeutic option for wound management due to its effects on wound healing and microbes (3, 37). It is a physical mixture of electrons and ions with charged molecules into an electronically conducted gas (9, 20). CAPP is bacteriostatic against methicillin-resistant *Staphy-*

lococcus aureus (MRSA) and *Pseudomonas aeruginosa* (2, 28) and has been shown to be effective against viral and fungal infections (18, 35) as well as the formation of biofilms (2). Furthermore, it affects different cell elements, such as lipids, proteins and DNA via charged and active molecules (free radicals, peroxide, and other reactive species) and also the production and secretion of growth factors (32, 38). The similar plasma jet “kINPen Med[®]” is used in human medicine for treatment of non-healing wounds and ulcers (14, 21) and shows antimicrobial activity in animals and human beings (15, 18). The depth of penetration of CAPP was measured via micro-spectroscopy to be approximately 10 µm into intact human skin (8, 22). Snake skin is reported to be 14–40 µm thick in several overlapping layers (19) and is composed of epidermal scales and dermal folds (10, 19). However, the defective skin barrier due to ulceration likely enabled a clinically relevant CAPP effect. No adverse reactions were observed.

To the best of the authors’ knowledge, this is the first case report describing a successive CAPP therapy of a multi-drug resistant bacterial infection in a reptile and may offer a promising therapeutic option for infections in those species.

Conflict of interests

The authors declare not to have any conflict of interest.

Acknowledgements

The authors want to thank neoplas tools GmbH (which were not involved in the selection of patients or their treatment) for providing the CAPP therapy device to the Small Animal Medicine Clinic.

References

- Abbott IJ, Slavin MA, Turnidge JD, Thursky KA, Worth LJ. *Stenotrophomonas maltophilia*: emerging disease patterns and challenges for treatment. *Expert Rev Anti Infect Ther* 2011; 9: 471–488.
- Alkawareek MY, Algwari QT, Laverty G, Gorman SP, Graham WG, O’Connell D, Gilmore BF. Eradication of *Pseudomonas aeruginosa* biofilms by atmospheric pressure non-thermal plasma. *PLoS One* 2012; 7: e44289.
- Arndt S, Unger P, Wacker E, Shimizu T, Heinlin J, Li YF, Thomas HM, Morfill GE, Zimmermann JL, Bosserhoff AK, Karrer S. Cold atmospheric plasma (CAP) changes gene expression of key molecules of the wound healing machinery and improves wound healing in vitro and in vivo. *PLoS One* 2013; 8: e79325.
- Barten SL. Bites from prey. In: *Reptile Medicine and Surgery*, 2nd edn. Mader DR, ed. Saint Louis: Saunders 2006; 747–750.
- Beco L, Guaguere E, Lorente Mendez C, Noli C, Nuttall T, Vroom M. Suggested guidelines for using systemic antimicrobials in bacterial skin infections: part 2 – antimicrobial choice, treatment regimens and compliance. *Vet Rec* 2013; 172: 156–160.
- Cushing A, Pinborough M, Stanford M. Review of bacterial and fungal culture and sensitivity results from reptilian samples submitted to a UK laboratory. *Vet Rec* 2011; 169: 390.
- Dennesen PJ, Bonten MJ, Weinstein RA. Multiresistant bacteria as a hospital epidemic problem. *Ann Med* 1998; 30: 176–185.
- Fluhr JW, Sassning S, Lademann O, Darwin ME, Schanzer S, Kramer A, Richter H, Sterry W, Lademann J. In vivo skin treatment with tissue-toler-

Conclusion for practice

Non-thermal ionized plasma therapy may offer a viable treatment option for bacterial pyoderma and necrotizing dermatitis in snakes, especially in cases of multi-resistant bacterial infections.

- able plasma influences skin physiology and antioxidant profile in human stratum corneum. *Exp Dermatol* 2012; 21: 130–134.
9. Fridman A, Chirokov A, Gutsol A. Non-thermal atmospheric pressure discharges. *J Phys D: Applied Physics* 2005; 38: R1.
 10. Funk RS. Snakes. In: *Reptile Medicine and Surgery*, 2nd edn. Mader DR, ed. Saint Louis: Saunders 2006; 42–58.
 11. Harris NB, Rogers DG. Septicemia associated with *Stenotrophomonas maltophilia* in a West African dwarf crocodile (*Osteolaemus tetraspis* subsp. *tetraspis*). *J Vet Diagn Invest* 2001; 13: 255–258.
 12. Hejnar P, Bardon J, Sauer P, Kolar M. *Stenotrophomonas maltophilia* as a part of normal oral bacterial flora in captive snakes and its susceptibility to antibiotics. *Vet Microbiol* 2007; 121: 357–362.
 13. Hillier A, Lloyd DH, Weese JS, Blondeau JM, Boothe D, Breitschwerdt E, Guardabassi L, Papich MG, Rankin S, Turnidge JD, Sykes JE. Guidelines for the diagnosis and antimicrobial therapy of canine superficial bacterial folliculitis (Antimicrobial Guidelines Working Group of the International Society for Companion Animal Infectious Diseases). *Vet Dermatol* 2014; 25: 163–175, e142–163.
 14. Hubner NO, Matthes R, Koban I, Randler C, Muller G, Bender C, Kindel E, Kocher T, Kramer A. Efficacy of chlorhexidine, polihexanide and tissue-tolerable plasma against *Pseudomonas aeruginosa* biofilms grown on polystyrene and silicone materials. *Skin Pharmacol Physiol* 2010; 23 Suppl: 28–34.
 15. Koban I, Matthes R, Hübner NO, Welk A, Meisel P, Holtfreter B, Sietmann R, Kindel E, Weltmann KD, Kramer A, Kocher T. Treatment of *Candida albicans* biofilms with low-temperature plasma induced by dielectric barrier discharge and atmospheric pressure plasma jet. *New J Phys* 2010; 12: 073039.
 16. Kawai T, Narisawa N, Yoneda S, Tsutsumi Y, Ishikawa J, Hoshino Y, Senpuku H. Inhibition of *Streptococcus mutans* biofilm formation using extracts from Assam tea compared to green tea. *Arch Oral Biol*; 68: 73–82.
 17. Kerwat K, Kerwat M, Graf J, Wulf H. [Resistance to antibiotics and multi-resistant pathogens]. *Anesthesiologie, Intensivmedizin, Notfallmedizin, Schmerztherapie: AINS* 2010; 45: 242–243.
 18. Klampfl TG, Isbary G, Shimizu T, Li YF, Zimmermann JL, Stolz W, Schlegel J, Morfill GE, Schmidt HU. Cold atmospheric air plasma sterilization against spores and other microorganisms of clinical interest. *Appl Environ Microbiol* 2012; 78: 5077–5082.
 19. Klein MC, Gorb SN. Epidermis architecture and material properties of the skin of four snake species. *J R Soc Interface* 2012; 9: 3140–3155.
 20. Kogelschatz U. Atmospheric-pressure plasma technology. *Plasma Phys Contr F* 2004; 46: B63.
 21. Kramer A, Lademann J, Bender C, Sckell A, Hartmann B, Münch S, Hinz P, Ekkernkamp A, Matthes R, Koban I, Partecke I, Heidecke CD, Masur K, Reuter S, Weltmann KD, Koch S, Assadian O. Suitability of tissue tolerable plasmas (TTP) for the management of chronic wounds. *Clin Plasma Med* 2013; 1: 11–18.
 22. Lademann J, Ulrich C, Patzelt A, Richter H, Kluschke F, Klebes M, Lademann O, Kramer A, Weltmann KD, Lange-Asschenfeldt B. Risk assessment of the application of tissue-tolerable plasma on human skin. *Clin Plasma Med* 2013; 1: 5–10.
 23. Lawrence K. Drug dosages for chelonians. *Vet Rec* 1984; 114: 150–151.
 24. Maas AK, 3rd. Vesicular, ulcerative, and necrotic dermatitis of reptiles. *Vet Clin North Am Exot Anim Pract* 2013; 16: 737–755.
 25. Mitchell MA. Therapeutics. In: *Reptile Medicine and Surgery*, 2nd edn. Mader DR, ed. Saint Louis: Saunders 2006; 2006; 631–664.
 26. Montali RJ, Bush M, Smeller JM. The pathology of nephrotoxicity of gentamicin in snakes. A model for reptilian gout. *Vet Pathol* 1979; 16: 108–115.
 27. Montay G, Goueffon Y, Roquet F. Absorption, distribution, metabolic fate, and elimination of pefloxacin mesylate in mice, rats, dogs, monkeys, and humans. *Antimicrob Agents Chemother* 1984; 25: 463–472.
 28. Napp M, Daeschlein G, von Podewils S, Hinz P, Emmert S, Haase H, Spitzmueller R, Gumbel D, Kasch R, Junger M. In vitro susceptibility of methicillin-resistant and methicillin-susceptible strains of *Staphylococcus aureus* to two different cold atmospheric plasma sources. *Infect* 2016; 44: 531–537.
 29. Gopee NV, Adesiyun AA, Caesar K. A longitudinal study of *Escherichia coli* strains isolated from captive mammals, birds, and reptiles in Trinidad. *J Zoo Wildl Med* 2000; 31: 353–360.
 30. Ash RJ, Mauck B, Morgan M. Antibiotic resistance of gram-negative bacteria in rivers, United States. *Emerg Inf Dis* 2002; 8: 713–716.
 31. Santoro M, Hernandez G, Caballero M. Aerobic bacterial flora of nesting green turtles (*Chelonia mydas*) from Tortuguero National Park, Costa Rica. *J Zoo Wildl Med* 2006; 37: 549–552.
 32. Schmidt A, Wende K, Bekeschus S, Bundscherer L, Barton A, Ottmüller K, Weltmann KD, Masur K. Non-thermal plasma treatment is associated with changes in transcriptome of human epithelial skin cells. *Free Radic Res* 2013; 47: 577–592.
 33. Smith DA, Barker IK, Allen OB. The effect of certain topical medications on healing of cutaneous wounds in the common garter snake (*Thamnophis sirtalis*). *Can J Vet Res* 1988; 52: 129–133.
 34. Stewart JS. Anaerobic bacterial infections in reptiles. *J Zoo Wildl Med* 1990; 21: 180–184.
 35. Trompeter FJ, Neff WJ, Franken O, Heise M, Neiger M, Shuhai L, Pietsch GJ, Saveljew AB. Reduction of *Bacillus Subtilis* and *Aspergillus Niger* spores using nonthermal atmospheric gas discharges. *IEEE T Plasma Sci* 2002; 30: 1416–1423.
 36. Uetz P, Hošek J. The Reptile Database. 20 Aug 2016. <http://www.reptile-database.org/>.
 37. von Woedtke T, Metelmann HR, Weltmann KD. Clinical plasma medicine: state and perspectives of in vivo application of cold atmospheric plasma. *Contrib Plasma Phys* 2014; 54: 104–117.
 38. Wende K, Barton A, Bekeschus S, Bundscherer L, Schmidt A, Weltmann KD, Masur K. Proteomic tools to characterize non-thermal plasma effects in eukaryotic cells. *Plasma Med* 2013; 3: 81–95.
 39. Wilkinson SL. Reptile wellness management. *Vet Clin North Am Exot Anim Pract* 2015; 18: 281–304.
 40. Young LA, Schumacher J, Papich MG, Jacobson ER. Disposition of enrofloxacin and its metabolite ciprofloxacin after intramuscular injection in juvenile Burmese pythons (*Python molurus bivittatus*). *J Zoo Wildl Med* 1997; 28: 71–79.