

Management of Iatrogenic Injury to the Inferior Vena Cava and Right Common Iliac Artery for Drainage of Psoas Abscess

Sandeep Mahapatra, MS, DNB*, Pinjala Ramakrishna, MS, FRCS, Bhumika Gupta, MS, Naren Shetty, MS, Muneer Ahmad Para, MS

Department of Vascular Surgery, Nizam's Institute of Medical Sciences, Hyderabad, India

Abstract

Iatrogenic simultaneous inferior vena cava (IVC) and iliac vessel injury is a rare entity. Ligation of the IVC in a life-threatening situation is well reported in the literature. Our case demonstrates that such a clinical situation requires optimization of fluid volume and management of sequelae such as deep vein thrombosis.

Copyright © 2017 Science International Corp.

Key Words:

Inferior vena cava injury • Psoas abscess • Deep vein thrombosis

Introduction

Combined inferior vena cava (IVC) and iliac vessel injury after interventional procedures is a rare entity. Ligation of the IVC in a life-threatening situation is well reported in the literature. Our case demonstrates that such a clinical situation requires replacement of fluid volume and management of sequelae such as deep vein thrombosis (DVT).

Case Presentation

A 50-year-old man presented to the emergency room with a history of insertion of a 16 F pigtail catheter for drainage of psoas abscess in a peripheral hospital (Figure 2). The patient had a gush of blood from the cath-

eter, for which he underwent a computed tomography scan (Figure 1) in the referring hospital, which was suggestive of the catheter piercing the IVC. In our hospital, a catheter angiogram was advised, which revealed a leak from the sideholes of the catheter into the right common iliac artery. To delineate the exact location of the catheter, the patient underwent a conventional angiogram through left groin access. The catheter was confirmed to have traversed the IVC and passed through the right common iliac artery, with the tip of the catheter communicating with the retroperitoneal free space.

For this iatrogenic injury of major vascular structures, with the catheter *in situ*, we decided to proceed with open surgery. The patient was clinically stable with palpable distal pulses. Under general anesthesia, a midline abdominal incision was made and infra-renal abdominal aorta control achieved. Right colon mobilization was performed to track the pathway of the pigtail catheter. The catheter was found to have crossed the psoas abscess cavity and to have pierced the confluence of the IVC and right common iliac artery (Figure 3). The catheter was cut between the aorta and IVC and removed with repair of the right common iliac artery with a 4-0 prolene suture. While mobilizing the catheter from the IVC, the rent extended into the left common iliac vein. Despite applying proximal and distal venous compression followed by Satinsky clamps, there was further extension of the injury with massive exsanguination. In a life-saving



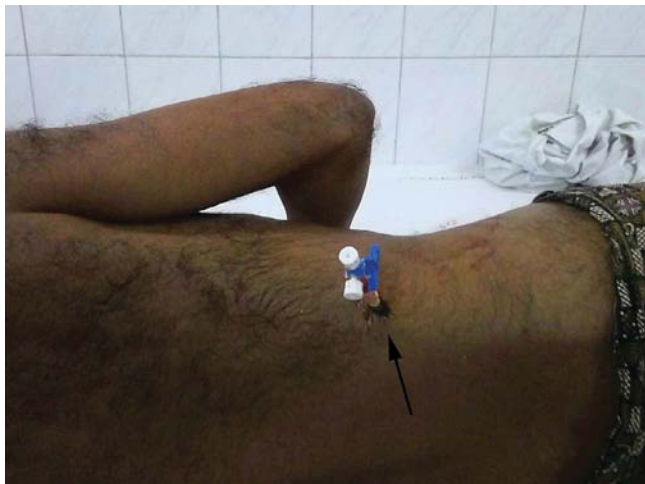

Figure 1. The entire length of the pigtail catheter passed through the right flank (arrow).

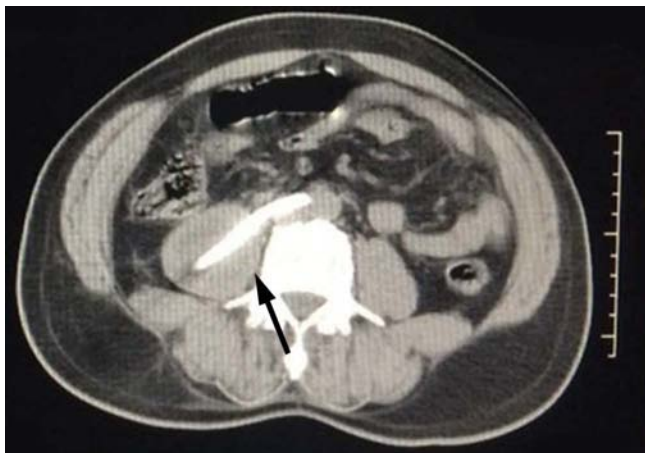

Figure 2. Computerized tomogram showing the tip of the pigtail catheter traversing the inferior vena cava and right common iliac artery.

approach, the IVC was plicated at its confluence with the iliac vein. Hemostasis was achieved. Drains were placed in the psoas abscess cavity and peritoneum. The abdominal cavity was closed. The patient was managed with inotropic support and transfusion of blood and blood products in the perioperative period. He was administered unfractionated heparin considering the high probability of DVT.

The patient developed swelling of the right lower limb, for which intermittent pneumatic compression was performed and a crepe bandage applied. Both lower limb pulses were palpable. Unfractionated heparin was initiated for suspected DVT, which was

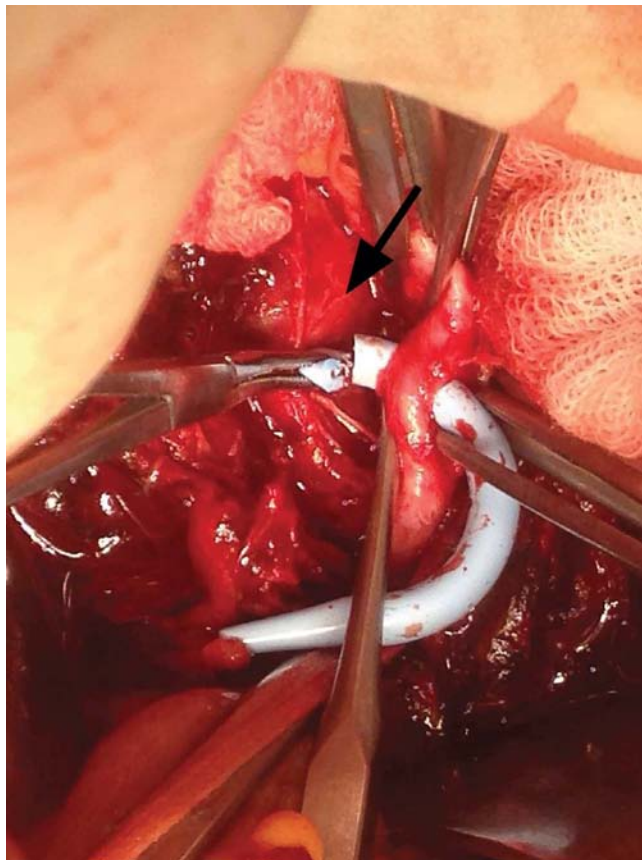


Figure 3. The tip of the pigtail catheter pierced the inferior vena cava and right common iliac artery (arrow).

confirmed by Duplex scan of the venous system. The patient had an uneventful post-operative course and was discharged on oral anticoagulation for 3 months. He was also advised to wear elastic compression stockings for 3 months. When the patient was assessed in the follow-up clinic, he exhibited normal gait and contour of both lower limbs.

Discussion

The earliest reported IVC ligations date back to Kocher in 1883 and Billroth in 1885 [1]. The first survivors of vena caval transection were reported by Bottini for infrarenal and Detrie for suprarenal ligation [1]. Yet, documented cases of caval ligation are rare. Ivy et al. described 23 case reports of infrarenal caval ligation and six case reports of suprarenal ligation in addition to their patient [2]. Also, a literature search revealed trauma or IVC tumor resection as

the antecedent cause of IVC ligation [3–7]. Whereas infrarenal caval ligation has been performed more frequently, there is reluctance among surgeons to ligate the suprarenal cava [8–11].

Hypotension and renal failure following ligation of an infrarenal cava has been documented by Gazzaniga et al. [1]. If this acute dramatic problem can be controlled, collateral circulation soon develops via the retroperitoneal and vertebral plexuses, ascending lumbar veins, and paravertebral veins, which drain into the azygos and hemiazygos systems. Testicular and ovarian veins may also contribute as accessory pathways [1].

The left renal vein and collaterals are the principal draining channels following suprarenal ligation of the IVC. The left adrenal vein and left spermatic/ovarian vein normally join the left renal vein. In addition, the left renal vein has lumbar and hemiazygos connections in 70% of patients [12]. Lumbar, ascending lumbar, and vertebral veins also contribute to collateral drainage. In 35% of patients, transient edema of the extremities develops, which becomes permanent in 2% of patients [13]. Abdominal compartment syndrome with extensive pedal edema following suprarenal ligation of the IVC has also been reported [2]. Our patient had edema of both lower limbs lasting 1 month. Doppler ultrasound and strain gauge plethysmography have been used to study the venous pattern following caval ligation [14]. Transient defects in renal function manifesting as oliguria/anuria and hematuria with rising creatinine levels have also been observed following caval ligation [2, 9, 10].

The pre-hospital mortality rate for IVC injuries is 36%, and among those who reach the hospital alive, mortality ranges from 21 to 57% [1]. Mortality also varies with the level of IVC injury. Trauma to the infrarenal cava is associated with a mortality of 25%, whereas injuries between the renal and hepatic veins carry a mortality of 41–55%. The mortality rates for caval injuries at or above the level of the hepatic veins exceed 80% [2]. Mortality following

IVC injury is attributed to persistent hemorrhage and associated hypotension, hypothermia, coagulopathy, and acidosis [2]. Navsaria et al. retrospectively evaluated risk factors by comparing survivors and non-survivors after IVC injuries. They found that the site of injury and type of surgical management (ligation vs. repair) were not predictors of survival [7]. Thus, it may be concluded that the mortality associated with IVC injuries is related to the associated trauma and surrounding organ injury.

Elective ligation in a controlled setting allows collaterals to develop and results in a good outcome. When IVC ligation is performed, intensive monitoring to correct hypovolemic shock and possible abdominal compartment syndrome is required, particularly when the ligation is performed in the acute setting. In the context of trauma, with caval injuries, ligation of the IVC has been suggested as an acceptable and life-saving option [7].

In conclusion, management of IVC injury has long been a challenge. The key to management of IVC injury lies in the decision for repair or ligation. Repair should be given preference when possible. In an unavoidable circumstance, timely ligation of the IVC is rewarding and compatible with life.

Acknowledgments

Dr Pinjala Ramakrishna for kind help in guiding through the operating procedure.

Conflict of Interest

The authors have no conflicts of interest relevant to this publication.

Comment on this Article or Ask a Question

References

- Gazzaniga AB, Colodny AH. Long-term survival after acute ligation of the vena cava above the renal veins. *Ann Surg.* 1972;175:563-568. DOI: [10.1097/00000658-197204000-00016](https://doi.org/10.1097/00000658-197204000-00016)
- Ivy ME, Possenti P, Atweh N, Sawyer M, Bryant G, Caushaj P. Ligation of the suprarenal vena cava after a gunshot wound. *J Trauma.* 1998;45:630-632. DOI: [10.1097/00005373-199809000-00042](https://doi.org/10.1097/00005373-199809000-00042)
- Asensio JA, Chahwan S, Hanpeter D, Demetriades D, Forno W, Gambaro E, et al. Operative management and outcome of 302 abdominal vascular injuries. *Am J Surg.* 2000;180:528-534. DOI: [10.1016/S0002-9610\(00\)00519-5](https://doi.org/10.1016/S0002-9610(00)00519-5)
- Kieffer E, Alaoui M, Piette JC, Cacoub P, Chiche L. Leiomyosarcoma of the inferior vena cava: experience in 22 cases. *Ann Surg.* 2006;244:289-295. DOI: [10.1097/01.sla.0000229964.71743.db](https://doi.org/10.1097/01.sla.0000229964.71743.db)
- Dew J, Hansen K, Hammon J, McCoy T, Levine EA, Shen P. Leiomyosarcoma of the inferior vena cava: surgical management and clinical results. *Am Surg.* 2005;71:497-501. DOI: [10.1186/1477-7819-7-56](https://doi.org/10.1186/1477-7819-7-56)

6. Hollenbeck ST, Grobmyer SR, Kent KC, Brennan MF. Surgical treatment and outcomes of patients with primary inferior vena cava leiomyosarcoma. *J Am Coll Surg.* 2003;197:575-579. DOI: [10.1016/S1072-7515\(03\)00433-2](https://doi.org/10.1016/S1072-7515(03)00433-2)
7. Navsaria PH, de Bruyn P, Nicol AJ. Penetrating abdominal vena cava injuries. *Eur J Vasc Endovasc Surg.* 2005;30:499-503. DOI: [10.1016/j.ejvs.2005.08.004](https://doi.org/10.1016/j.ejvs.2005.08.004)
8. Cassebaum WH, Bukanz SL, Baum V, Azzi E. Ligation of the inferior vena cava above the renal vein of a sole kidney with recovery. *Am J Surg.* 1967;113:667-670. DOI: [10.1016/0002-9610\(67\)90316-9](https://doi.org/10.1016/0002-9610(67)90316-9)
9. Caplan BB, Halasz NA, Bloomer WE. Resection and ligation of the suprarenal inferior vena cava. *J Urol.* 1964;92:25-29. PMID: [14195020](https://pubmed.ncbi.nlm.nih.gov/14195020/)
10. Ramnath R, Walden EC, Caguin F. Ligation of the suprarenal vena cava and right nephrectomy with complete recovery. *Am J Surg.* 1966;112:88-90. DOI: [10.1016/S0002-9610\(66\)90990-1](https://doi.org/10.1016/S0002-9610(66)90990-1)
11. Turpin I, State D, Schwartz A. Injuries to the inferior vena cava and their management. *Am J Surg.* 1977;134:25-32. DOI: [10.1016/0002-9610\(77\)90279-3](https://doi.org/10.1016/0002-9610(77)90279-3)
12. Anson BJ, Cauldwell EW, Pick JW, Beaton LE. The anatomy of the para-renal system of veins, with comments on the renal arteries. *J Urol.* 1948;60:714-737. PMID: [18895260](https://pubmed.ncbi.nlm.nih.gov/18895260/)
13. Timberlake GA, Kerstein MD. Venous injury: to repair or ligate, the dilemma revisited. *Am Surg.* 1995;61:139-145. PMID: [7856974](https://pubmed.ncbi.nlm.nih.gov/7856974/)
14. Perhoniemi V, Salmenkivi K, Vorne M. Venous hemodynamics in the legs after ligation of the inferior vena cava. *Acta Chir Scand.* 1986;152:23-27. PMID: [3513470](https://pubmed.ncbi.nlm.nih.gov/3513470/)

Cite this article as: Mahapatra S, Ramakrishna P, Gupta B, Shetty N, Para MA. Management of Iatrogenic Injury to the Inferior Vena Cava and Right Common Iliac Artery for Drainage of Psoas Abscess. *AORTA (Stamford).* 2017;5(2):64-67. DOI: <https://doi.org/10.12945/j.aorta.2017.16.024>

EDITOR'S COMMENTS

Initially, one may wonder why a venous paper is being included in *AORTA*. As Dr. Stansel taught years ago, iatrogenic operative venous injuries, incurred during arterial surgery, can be much more difficult

to control and pose a greater risk to life than arterial injuries. I was not aware that inferior vena caval ligation was tolerable. Perhaps other readers will benefit from knowing that this option is available when dealing with massive hemorrhage from an iliac vein or the vena cava itself, at the infra- or supra-renal levels.