

Long-Term Survival After Composite Mechanical Aortic Root Replacement

Khaled E. Al-Ebrahim, FRCSC*, Husain H. Jabbad, FRCSC, Ahmad H. Alqari, MBBS

Division of Cardiothoracic Surgery, King Abdulaziz University Hospital, Jeddah, Saudi Arabia

Abstract

This report describes the long-term follow-up of the repair of a giant ascending aneurysm using a composite graft with a mechanical valve.

Copyright © 2016 Science International Corp.

Key Words

Aneurysm • Aortic • Ascending • Composite root

A 55-year-old male presented with severe cardiac and renal failure ten years ago. Electrocardiogram (ECG) showed aortic root dilatation, severe aortic regurgitation, and left ventricular dysfunction. Chest computed tomography revealed an ascending aortic aneurysm larger than the heart, measuring 13.5 cm in the transverse diameter and 12 cm anteroposteriorly (Figure 1). Aortic root replacement using a size 33 composite graft and coronary reimplantation were performed. Ejection fraction, renal function, and general health gradually improved. This patient was followed-up for 10 years

with no complications and has led a normal life. Recent chest computed tomography showed normal aortic root and coronary arteries (Figure 2). Right coronary implantation is shown in a colored three-dimensional image (Figure 3). This case demonstrates excellent longevity and freedom from reoperation in patients who undergo composite root replacement.

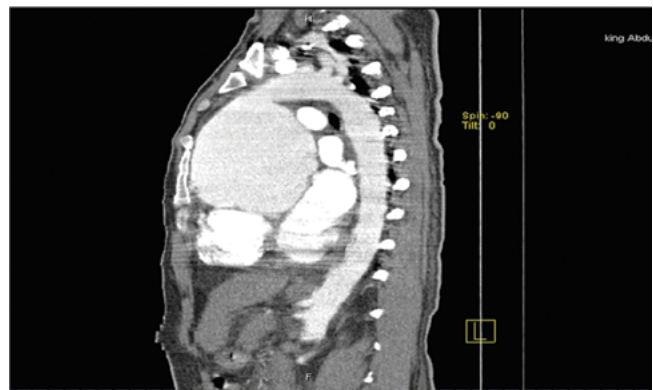


Figure 1. Preoperative computed tomography image showing a 13-cm ascending aortic aneurysm involving the sinuses of Valsalva.



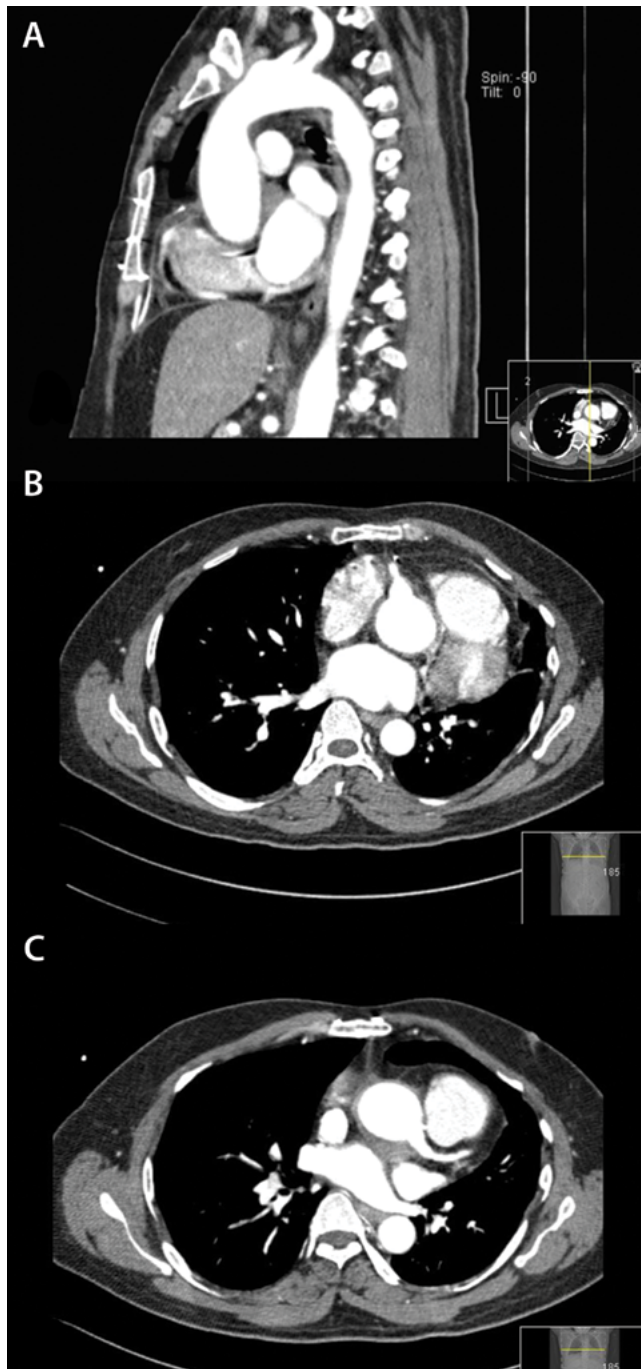


Figure 2. Postoperative computed tomography images obtained 10 years after surgery. *Panel A.* Sagittal section showing the neo-ascending aorta. *Panel B.* Coronal section showing the neo-right coronary artery. *Panel C.* Coronal section showing the neo-left coronary artery.

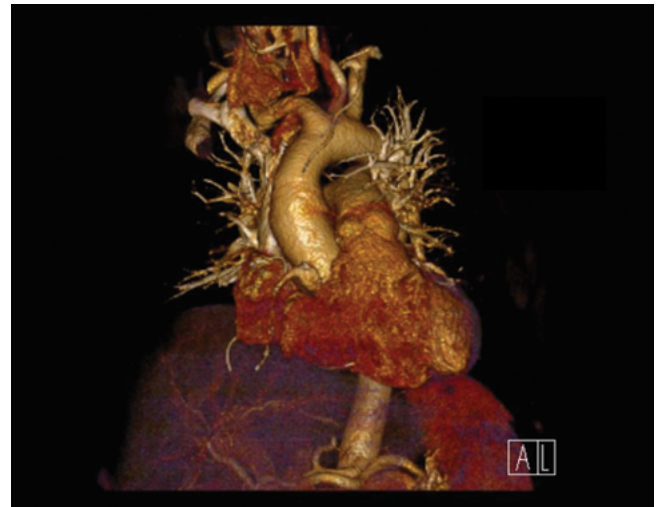

Figure 3. Postoperative computed tomography image obtained 10 years after surgery showing the ascending aorta and right coronary artery.

Conflict of Interest

The authors have no conflict of interest relevant to this publication.

[Comment on this Article or Ask a Question](#)

Cite this article as: Al-Ebrahim KE, Jabbad HH, Alqari AH. Long-Term Survival After Composite Mechanical Aortic Root Replacement. *AORTA (Stamford)*. 2016;4(4):146-147. DOI: <http://dx.doi.org/10.12945/j.aorta.2016.15.039>