

# Acute Conditions Caused by Infectious Aortitis

Jiri Molacek, MD, PhD<sup>1\*</sup>, Vladislav Treska, MD, PhD<sup>1</sup>, Jan Baxa, PhD<sup>2</sup>,  
Bohuslav Certik, MD, PhD<sup>1</sup>, Karel Houdek, MD, PhD<sup>1</sup>

<sup>1</sup>School of Medicine in Pilsen, Charles University in Prague, Vascular Surgery Department, University Hospital in Pilsen, Pilsen, Czech Republic; <sup>2</sup>School of Medicine in Pilsen, Charles University in Prague, Department of Imaging Techniques, University Hospital in Pilsen, Pilsen, Czech Republic

## Abstract

Infection of the aorta is rare but potentially very dangerous. Under normal circumstances the aorta is very resistant to infections. Following some afflictions, the infection can pass to the aorta from blood or the surrounding tissues. The authors present their 5-year experience with therapy of various types of infections of the abdominal aorta. **Methods:** In the 5-year period between January 2008 and December 2012, the Surgical Clinic of the University Hospital in Pilsen treated 17 patients with acute infection of the abdominal aorta. They included 9 males and 8 females. The mean age was 73.05 years (58-90). The most common pathogens were *Salmonella* (7), *Staphylococcus aureus* (2), *Klebsiella pneumoniae* (1), *Listeria monocytogenes* (1), and *Candida albicans* (1). Two cases included mixed bacteria and no infectious agent was cultured in three cases. In 14 cases (82.6%) we decided on an open surgical solution, i.e., resection of the affected abdominal aorta, extensive debridement, and vascular reconstruction. In all of these 14 cases we decided on in situ reconstruction. Twelve cases were treated using silver-impregnated prostheses. An antibiotic impregnated graft was used in one case and fresh aortic allograft in one case. In one case (5.9%) we decided on an endovascular solution, i.e., insertion of a bifurcation stent graft and prolonged antibiotic therapy. In two cases (11.8%) we decided on conservative treatment, as both patients refused any surgical therapy. **Results:** Morbidity was 47.2% (8 patients). In one case we had to perform reoperation of a patient on the 15th postoperative day to evacuate the postoperative hematoma. The 30-day mortality was 5.9% (1 patient). The hospital mortality was 11.8% (2 patients). One

patient died on the 42nd postoperative day due to multiorgan failure following resection of perforated aortitis. During follow-up (average 3.5 years), we had no case of infection or thrombosis of the vascular prosthesis. **Conclusion:** Patients with mycotic aneurysms or acute aortitides face a high risk of death. One can legitimately expect an increase of "aortic infections" to parallel the increase of immunocompromised individuals. Surgical procedures for infectious aortitis are always demanding and require excellent interdisciplinary cooperation, but, as this experience shows, can lead to mid-term survival.

Copyright © 2014 Science International Corp.

## Key Words

Aortic infection · Pseudoaneurysm · Aortitis · Ruptured aortic aneurysm · Aneurysm

## Introduction

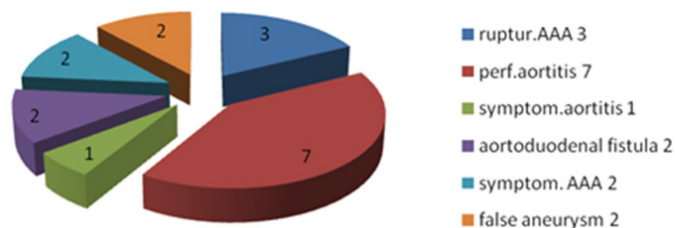
Infection of the aorta is rare but potentially very dangerous [1]. Under normal circumstances the aorta is very resistant to infections. Following some afflictions, such as atherosclerotic ulcers, trauma, or cystic necrosis of the tunica media, an infection can pass to the aorta from blood or surrounding tissues. Other risk factors for infection of the aorta include diabetes mellitus, vascular malformations, and any invasive catheterization [2,3]. Infection of the large arteries is always a serious and life-threatening disease, especially in the case of aortic infection. Infection of the

The work was supported by Research Project of Charles University in Prague P36.

\*Corresponding author:

Jiri Molacek, MD, PhD  
Vascular Surgery Department  
University Hospital in Pilsen  
Alej Svobody 80  
304 60 Pilsen, Czech Republic  
Tel: +1 420 603 8777, Fax: +1 420 377 103 965, E-Mail: molacek@fnplzen.cz



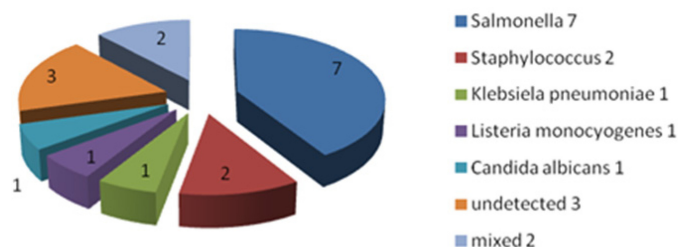


**Figure 1.** Demographics of patient group by diagnosis. The group included patients with acute infectious perforated aortitis, acute infectious symptomatic or rupturing aneurysm of the abdominal aorta, or acute symptomatic pseudoaneurysm of the abdominal aorta.

thoracic aorta in patients with syphilis, which was relatively common in the past, has practically disappeared. However, it has been replaced by other types of infections, especially of the abdominal aorta, which are variable from the etiopathogenetic point of view. Whether typical mycotic aneurysm (caused by septic embolism), infectious pseudoaneurysms, infected pre-existing aneurysms, or infectious aortitis, all these cases are always serious and require acute therapy. However, the discussions on the method of therapy of these emergency conditions [whether concerning the type of reconstruction (in situ/extra-anatomic), the type of the graft used, or duration of antibiotic therapy] continue. Use of endovascular methods of therapy remains controversial as well. The authors present their 5-year experience with therapy of various types of infections of the abdominal aorta. They discuss methods of diagnosis and therapy.

## Methods

Data were collected from medical records. In the 5-year period between January 2008 and December 2012, in the Surgical Clinic of the University Hospital in Pilsen (tertiary referral hospital for a large geographic area), we treated 17 patients with acute infection of the abdominal aorta. These included patients with acute infectious perforated aortitis, acute infectious symptomatic or rupturing aneurysm of the abdominal aorta, or acute symptomatic pseudoaneurysm of the abdominal aorta (Fig. 1). These cases were always acute, not elective, surgeries with a positive culture finding. They included 9 males and 8 females. The mean age was 73 years (range 58-90). The most common pathogens were *Salmonella* (7), *Staphylococcus aureus* (2), *Klebsiella pneumoniae* (1), *Listeria monocytogenes* (1), and *Candida albicans* (1). Two cases included mixed bacteria and no infectious agent was cultured in three cases (Fig. 2). In these 3 cases we were convinced of an infectious etiology based on further information (medical history, clinical course, macroscopic appearance, laboratory tests). The infectious microorganisms were obtained from a smear from the



**Figure 2.** Demographics of patient group by infectious organism. Two cases included mixed bacteria and no infectious agent was cultured in three cases.

aortic wall tissue or intraluminal thrombus; blood culture was the source of the result in 6 cases.

In 14 cases (82.6%) we decided on an open surgical solution, i.e., resection of the affected abdominal aorta, extensive debridement, and vascular reconstruction. In all 14 cases we decided on in situ reconstruction. Twelve cases were treated using silver-impregnated prostheses. An antibiotic (ATB; rifampicin)-impregnated graft was used in one case, and fresh aortic allograft in one case.

In one case (5.9%) we decided on an endovascular solution, i.e., insertion of a bifurcation stent graft and prolonged antibiotic therapy.

In two cases (11.8%) we decided on a conservative procedure as both patients refused any surgical therapy. Detailed information on the group of patients is included in Table 1.

## Results

Morbidity in our group of patients was 47.2% (8 patients). This most commonly included transient respiratory failure (associated with comorbidities of the patients and duration of surgery), renal failure, and wound infection. In one case we had to perform a reoperation on a patient on the 15th postoperative day to evacuate a postoperative hematoma.

The 30-day mortality was 5.9% (1 patient). This was a female patient with rupture of the abdominal aortic aneurysm (AAA) who refused surgery. She died on the 4th day following admission to hospital. The hospitalization mortality was 11.8% (2 patients). One patient, following resection of perforated aortitis, died on the 42nd postoperative day due to multiorgan failure.

During follow-up (average 3.5 years), we had no case of infection or thrombosis in the vascular prosthesis (one patient was lost to follow-up).

## Discussion

Aortic ruptures in patients with syphilis were described as early as the 16th century. In the 19th cen-

**Table 1.** Details of Patient Group

No.	Sex	Age	Pathogen	Imagine finding	ATB	Therapy	Hospital outcome	Late outcome
1	1F	88	<i>Staphylococcus aureus</i>	Subrenal aorta pseudoaneurysm	Ceftriaxon	Resection, ABI bypass (silvergraft)	Ok, discharged 17th day	Alive 2 years after surgery
2	M	62	<i>Salmonella enters</i>	Symptom. aortitis	Ciprofloxacin, Ampicilin	Resection, ABI bypass (allograft)	Ok, discharged 15th day	Alive 4 years after surgery
3	M	62	<i>Salmonella enteritidis</i>	AAA rupture	Ceftriaxon	Resection, AA graft (silvergraft)	OK, discharged 51st day	Alive 1 year after surgery
4	M	64	<i>Salmonella enteritidis</i>	Perforated aortitis	Ampicilin, Ciprofloxacin	Resection, AA graft (silovergraft)	OK, discharged 8th day	Alive 5 years after surgery
5	F	89	<i>Salmonella enteritidis</i>	Perforated aortitis	Ciprofloxacin	Resection, AA graft (ATB graft)	OK, discharged 24th day	Died 2 months after surgery
6	F	89	<i>Stahylococcus aureus</i>	AAA rupture	0	Conservative	Died 4 th day, refuse surgery	
7	F	90	Mixed	Perforated aortitis	Vancomycin	EVAR	OK, discharged 16th day	Alive 1 year after EVAR
8	F	89	<i>Klebsiela pneumonie</i>	Subrenal aorta pseudoaneurysm	Amoxicilin	Conservative	OK, discharged 14th day	Alive 2 years after diagnostic
9	M	84	Unknown	Symptomatic AAA	Ciprofloxacin, Ampicilin	Resection, AA graft (silvergraft)	OK, discharged 8th day	Unknown
10	M	78	<i>Salmonella enteritidis</i>	AAA rupture	Ciprofloxacin	Resection, ABF bypass (silvergraft)	OK, discharged 20th day	Alive 4 years after surgery
11	F	69	Mixed	Aorto-duodenal fistula	PNC, Genta, Metronidazol	Resection, ABF bypass (silvergraft)	OK, discharged 26th day (limb lost)	Alive 2 years after surgery
12	M	63	<i>Listeria monocytogenes</i>	Perforated aortitis	Gentamycin, Ampicilin	Resection, AA graft (silvergraft)	OK, discharged 18th day	Alive 2 years after surgery
13	M	62	<i>Salmonella enteritidis</i>	Perforated aortitis	Ciprofloxacin, Cefotaxim	Resection, AA graft (silvergraft)	OK, discharged 8th day	Unknown
14	F	59	<i>Salmonella species</i>	Perforated aortitis	Ciprofloxacin	Resection, AA graft (silvergraft)	OK, discharged 14th day	Alive 3 years after surgery
15	F	58	<i>Candida albicans</i>	Symptomatic AAA	Cefazolin	Resection, AA graft (silvergraft)	OK, discharged 12th day	Alive 3 years after surgery
16	M	65	Unknown	Aortoduodenal fistula	Vancomycin	Resection, ABF bypass (silvergraft)	OK, discharged 31st day	Alive 6 months after surgery
17	M	71	Unknown	Perforated aortitis	Vancomycin	Resection, AA graft (silvergraft)	OK, discharged 28th day	Unknown

PNC = penicili.

ture, Kochr and Rokitanski described case reports of rupturing infectious aortic aneurysms [11]. In 1885, William Osler gave a lecture for the Royal College of Physicians in London in which he described a *mycotic aneurysm* "caused most probably by an alleged fungal infection [11]."

Since that time, a number of types of infectious aortitides have been described. In the preantibiotic era they were caused mostly by streptococcus during infectious endocarditis. A significant reduction of this etiopathogenetic agent occurred following the advent of antibiotic therapy. However, other mechanisms of infectious aortitides and other infectious agents have emerged. Under normal circumstances, the aorta is well resistant against infection (tunica intima is a barrier). Infectious aortitis often has roots in existing aortic pathology, including atherosclerosis and ulceration. Also, immunocompromised individuals (chronic disease or medication) are vulnerable; the infection can spread from bacteremia (e.g., following salmonella

gastroenteritis, pneumococcal bronchopneumonia) or by direct extension from the surrounding organs (pancreas, intervertebral disc). The risk factors for aortic infection include any catheterization procedures (infection, injury of tunica intima) [2,3]. Post-traumatic lesions may also be involved. It is not clear why there is a significant epidemiological difference between the European and Asian population. Incidence of aortic infection in the European—but also American—population ranges between 1 and 2% [4–6], while in the Asian population it is around 13% [6]. The typical age for infection of the aorta is > 50 years, but cases have been described in the literature in all age groups, including newborns [3,4].

Most authors report that more than one third of pathogens are represented by *Salmonella*, and the other microorganisms include *Staphylococcus*, *Pneumococcus*, *Escherichia coli*, *Streptococcus* [1,7], and, more rarely, *Candida*, *Aspergillus*, and *Listeria monocytogenes*. The aneurysms caused by Gram-negative

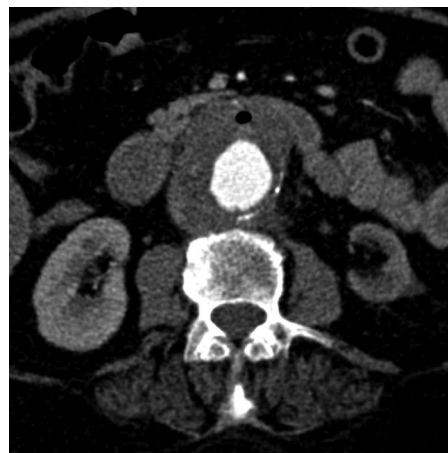bacteria have a much higher risk of expansion and rupture compared to Gram-positive infections [8]. The results of cultivation of pathogens in our group correspond to the literature data, with a dominance of *Salmonella*. In three cases we failed to cultivate a pathogen, which is also in compliance with the literature data [9]. Preoperatively initiated antibiotic therapy may be the reason. It has to be emphasized that, based on the literature, approximately 30% of AAAs are colonized mostly by less virulent strains [10], and these aneurysms cannot be classified as mycotic or infectious. Therefore, a positive microbiological finding from the AAA sac does not necessarily mean an infectious etiopathogenesis of the aneurysm.

Nomenclature for infections of the aorta is problematic. Most authors use the term mycotic aneurysm for all infectious aneurysms. In clinical practice it is a fully sufficient name that describes infectious etiology. From the didactical point of view, we should differentiate between various etiopathogenetic mechanisms, which are well described in the Rutherford classification of infections of the aorta [11]. In our group of patients, we recorded all types from the four categories of this classification (mycotic aneurysm, microbial aortitis, infected preexisting aneurysm, infectious pseudoaneurysm).

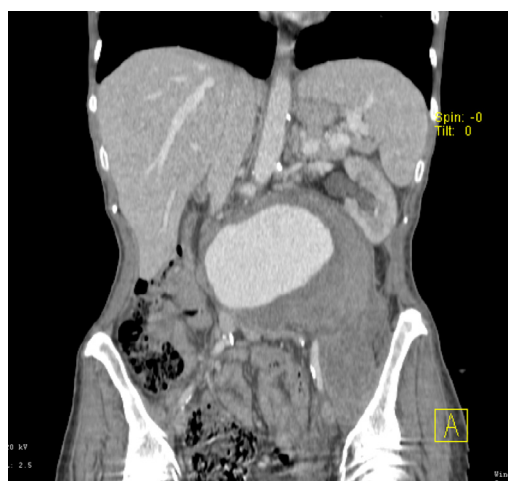
In some cases the single categories are mixed. An infected pseudoaneurysm occurs commonly in the case of aortic perforation on the basis of infected atherosclerotic plaque. Therefore, is it a perforated aortitis or infected pseudoaneurysm? These discussions have absolutely no bearing on the diagnosis and therapy.

The symptoms depend on the type of infection. In the case of aortic perforation, the typical signs are the same as in the rupture of a common aneurysm. In nonbleeding lesions, the course can be transiently asymptomatic; however, more often, there can be seen fever, abdominal and back discomfort, tiredness, exhaustion, and signs of sepsis. Four patients in our group reported severe gastroenteritis in the recent 4 weeks, out of which two had a positive cultivation for *Salmonella* during their gastroenteritis. Both patients with primary aortic-duodenal fistula had signs of bleeding into the upper gastrointestinal tract.

Following careful medical history and physical examination, standard imaging methods are most



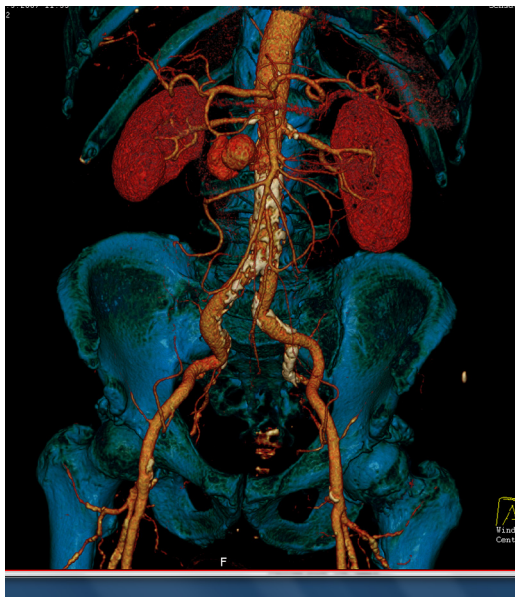**Figure 3.** A typical CT scan of aortitis or mycotic aneurysm.



**Figure 4.** Characteristics of the of the AAA.

beneficial for diagnosis. We preferred mostly CT (computer tomography); rarely, we used MRI or the hybrid methods [positron emission tomography with CT (PET CT), or single-photon emission CT (SPECT)]. A typical picture of aortitis or mycotic aneurysm is a thickened margin of hyperdense tissue around the aortic wall, and there is often a suspicion of leakage from the aneurysm. Bubbles of gas indicate an advanced finding and practically an abscess in the retroperitoneum or the presence of a fistula between the aorta and gastrointestinal tract (mostly duodenum) (Fig. 3). In infected aneurysms, a rapid increase of diameter may occur up to the point of rupture.

Bizarre eccentric shapes of the AAA may be seen (Fig. 4). If a perforation of the nondilated aorta occurs (mostly on the basis of rupture at the site of the



**Figure 5.** A pseudoaneurysm.

infected atherosclerotic plaque), a pseudoaneurysm often develops and no massive extravascular leakage usually occurs (Fig. 5).

Patients with infectious aortitis should be immediately indicated for the relevant therapy. Preoperative preparation should include only the necessary steps and must not cause unnecessary delay of surgery. In our group of patients, we mostly decided on surgery (open repair), which is still a gold standard of therapy. Open questions remain regarding options for reconstruction. However, in recent years, most authors prefer anatomic (in situ) reconstruction using grafts which are more resistant to inflammation [12,13]. We also used in situ reconstruction in all cases. In extra-anatomical reconstructions, there is poorer long-term patency, and the main disadvantage is the risk of failure of the suture line of the aortic stump, so-called “stump blowout syndrome,” which is practically always fatal. Silver-impregnated prostheses are popular and were used extensively in our series. In one case we used a prosthesis saturated with antibiotic and in one case a fresh aortic allograft. Use of fresh or cryopreserved aortic allografts is beneficial as it is associated with minimum risk of reinfection. However, it has disadvantages, including the necessary immunosuppression; also, the logistics of obtaining the allograft in acute conditions are not easy. We have not used reconstruction with superficial femoral veins, which is mentioned in the literature [14]. A certain disadvan-

tage associated with this method is the extension of time of surgery, and the veins cannot always be used in acute conditions. Always, when we expected an infectious etiology, we initiated therapy with broad-spectrum bactericidal antibiotics administered preoperatively; later, we adjusted this therapy based on the results of microbiological cultivation. In our opinion, the antibiotic therapy should never be shorter than 2 months, and a control CT and examination of inflammatory markers should be performed before its discontinuation.

Endovascular therapy is still a bit controversial in this field, even though there is considerable literature data justifying this method [15–20]. Some studies report successful therapy of mycotic AAA with a retroperitoneal abscess using a stent graft and percutaneous drainage [15,21]. We used stent grafts once in our group of patients in acute symptomatic aortitis with a good result. A study with long-term results is missing in this field. Endografting can be considered as a possible method of solution for infectious aneurysms or aortitides. In some cases, it may serve as a bridge, i.e., bridging of the acute phase before later resection.

Most authors agree that simple conservative therapy with antibiotics is absolutely insufficient, with mortality almost 100% [22]. In our group of patients, we used conservative therapy in two cases, and a patient’s refusal regarding an invasive solution was always accepted. One female patient died due to rupture of the mycotic AAA; another female patient is undergoing successful conservative treatment of infectious pseudoaneurysm. The follow-up period in this female patient is now 2 years, and she has no complications.

Morbidity of patients with an aortic infection is often related to a number of comorbidities occurring in elderly patients and depends also on the severity, or the surgical or endovascular procedure. Respiratory failure, renal failure, or multiorgan failure is most common. Wound infection occurs more commonly compared to routine vascular reconstruction. The most serious complication is the infection of the graft. We had no such case in our group of patients (the mean follow-up period is 3 years).

Patients with mycotic aneurysms or acute aortitides always have a high risk of death. There are five known independent factors associated with high mortality: extensive periaortic infection, female gen-

der, *Staphylococcus aureus* as an infectious agent, aortic rupture, and suprarenal location [23]. These patients should be referred to cardiovascular centers which have greater experience with aortic therapy. One can legitimately expect an increase of "aortic infections" with regard to increase of immunocompromised individuals (chronic diseases, HIV, chronic medication, post-transplantation state). The required surgical procedures are always demanding

and require excellent interdisciplinary cooperation and a thoughtful approach to the patient.

### Conflict of Interest

The authors have no conflict of interest relevant to this publication.

[Comment on this Article or Ask a Question](#)

### References

- Gornik HL, Creager MA. Aortitis. *Circulation*. 2008; 117:3039–3051. [10.1161/CIRCULATIONAHA.107.760686](#)
- Samore MH, Wessolovsky MA, Lewis SM, Shubrooks SJ, Karchmer AW. Frequency, risk factors, and outcome for bacteremia after percutaneous transluminal coronary angioplasty. *Am J Cardiol*. 1997;79:873–877. [10.1016/S0002-9149\(97\)00006-4](#)
- Andersen ND, Bhattacharya SD, Williams JB, McCann RL, Hughes GC. Mycotic aneurysm of the thoracoabdominal aorta in a child with end-stage renal disease. *J Vasc Surg*. 2011;54:1161–1163. [10.1016/j.jvs.2011.04.051](#)
- Miller DV, Oderich GS, Aubry MC, Panneton JM, Edwards WD. Surgical pathology of infected aneurysms of the descending thoracic and abdominal aorta: clinicopathologic correlations in 29 cases (1976 to 1999). *Hum Pathol*. 2004;35:1112–1120. [10.1016/j.humpath.2004.05.013](#)
- Svensson LG, Crawford ES. Aortic dissection and aortic aneurysm surgery: clinical observations, experimental investigations, and statistical analyses. Part I. *Curr Probl Surg*. 1992;29:817–911. [10.1016/0011-3840\(92\)90003-L](#)
- Luo CY, Ko WC, Kan CD, Lin PY, Yang YJ. In situ reconstruction of septic aortic pseudoaneurysm due to *Salmonella* or *Streptococcus* microbial aortitis: long-term follow-up. *J Vasc Surg*. 2003;38:975–982. [10.1016/S0741-5214\(03\)00549-4](#)
- Oz MC, Brener BJ, Buda JA, Todd G, Brenner RW, Goldenkranz RJ, et al. A ten-year experience with bacterial aortitis. *J Vasc Surg*. 1989;10:439–449. [10.1067/mva.1989.14207](#)
- Fillmore AJ, Valentine R. Surgical mortality in patients with infected aortic aneurysms. *J Am Coll Surg*. 2003;196:435–441. [10.1016/S1072-7515\(02\)01607-1](#)
- Brown SL, Busuttill RW, Baker JD, Machleder HI, Moore WS, Barker WF. Bacteriologic and surgical determinants of survival in patients with mycotic aneurysms. *J Vasc Surg*. 1984; 4:541–547. [10.1016/0741-5214\(84\)90040-5](#)
- da Silva RM, Lingaas PS, Geiran O, Tronstad L, Olsen I. Multiple bacteria in aortic aneurysms. *J Vasc Surg*. 2003;38:1384–1389. [10.1016/S0741-5214\(03\)00926-1](#)
- Rutherford R. Infected aneurysms. In *Vascular Surgery*, 6th edition, volume 2. Philadelphia: Elsevier Saunders. 2009;1581–1583.
- Lopes R, Almeida J, Dias PJ, Pinho P, Maciel MJ. Infectious thoracic aortitis: a literature review. *Clin Cardiol*. 2009;32:488–490. [10.1002/clc.20578](#)
- Ting AC, Cheng SW, Ho P, Poon JT, Tsu JH. Surgical treatment of infected aneurysms and pseudoaneurysms of the thoracic and abdominal aorta. *Am J Surg*. 2005;189:150–154. [10.1016/j.amjsurg.2004.03.020](#)
- Staffa R, Kríz Z, Vlachovský R, Dvorák M, Novotný T, Bucek J, et al. Autogenous superficial femoral vein for replacement of an infected aorto-ilio-femoral prosthetic graft. *Rozhl Chir*. 2010;89:39–44.
- Koeppel TA, Gahlen J, Diehl S, Probst RL, Dueber C. Mycotic aneurysm of the abdominal aorta with retroperitoneal abscess: successful endovascular repair. *J Vasc Surg*. 2004;40:164–166. [10.1016/j.jvs.2004.02.046](#)
- Berchtold C, Eibl C, Seelig MH, Jakob P, Schonleben K. Endovascular treatment and complete regression of an infected abdominal aortic aneurysm. *J Endovasc Ther*. 2002; 9:543–548. [10.1583/1545-1550\(2002\)009<0543:ETACRO>2.0.CO;2](#)
- Kinney EV, Kaebnick HW, Mitchell RA, Jung MT. Repair of mycotic paravisceral aneurysm with a fenestrated stent-graft. *J Endovasc Ther*. 2000;7:192–197. [10.1583/1545-1550\(2000\)007<0192:ROMPAW>2.3.CO;2](#)
- Patetsios PP, Shutze W, Holden B, Garrett WV, Pearl GJ, Smith BL, et al. Repair of a mycotic aneurysm of the infrarenal aorta in a patient with HIV, using a Palmaz stent and autologous femoral vein graft. *Ann Vasc Surg*. 2002;16:521–523. [10.1007/s10016-001-0070-3](#)
- Corso JE, Kasirajan K, Milner R. Endovascular management of ruptured, mycotic abdominal aortic aneurysm. *Am Surg*. 2005;71:515–517.
- Madhavan P, McDonnell CO, Dowd MO, Sultan SA, Doyle M, Colgan MP, et al. Suprarenal mycotic aneurysm exclusion using a stent with a partial autologous covering. *J Endovasc Ther*. 2000;7:404–409. [10.1583/1545-1550\(2000\)007<0404:SMAEUA>2.0.CO;2](#)
- Kim JG, Kwon JB, Park K, Lee J. Endovascular treatment of ruptured infected aortic aneurysm with sepsis. *J Korean Surg Soc*. 2012; 83:250–253. [10.4174/jkss.2012.83.4.250](#)
- Sakamoto S, Yokoyama N, Kasai S, Tamori Y, Okajima T, Yoshimuta T, et al. Serial assessment at computed tomography and fluorine-18-labeled deoxyglucose positron emission tomography for the diagnosis and treatment of nonaneurysmal infective aortitis. *Can J Cardiol*. 2009;25:367. [10.1016/S0828-282X\(09\)70101-1](#)
- Oderich GS, Panneton JM, Bower TC, Cherry KJ, Rowland CM, Noel AA, et al. Infected aortic aneurysms: aggressive presentation, complicated early outcome, but durable results. *J Vasc Surg*. 2001;34:900–908. [10.1067/mva.2001.118084](#)

**Cite this article as:** Molacek J, Treska V, Baxa J, Certik B, Houdek K. Acute Conditions Caused by Infectious Aortitis. *Aorta* 2014;2(3):93–99. DOI: <http://dx.doi.org/10.12945/j.aorta.2014.14-004>

## EDITOR'S COMMENTS AND QUESTIONS

### Comments

We appreciate the authors' informative report on this relatively uncommon condition not familiar to many US surgeons.

### Questions

1. Can we be sure of the diagnosis (especially in the culture negative cases)?

*This is a very good question. It is true that sometimes we do not have the proofs for infectious aortitis (cases of negative cultures). But the suspected diagnosis of infectious aortitis can be done according to anamnesis, CT, and perioperative findings. If all these factors show infectious etiology, we believe in this rare diagnosis.*

2. Was any of the histology revealing?

*To be honest, it was not revealing. Very often, we found lymphocyte infiltration in the wall (tunica media and adventitia), but we can see this histological finding also in "normal" AAA.*

3. What could be the rationale for adding more foreign material into a stent graft, while not removing the infected aortic tissue? Would not medical treatment be better if there is no false aneurysm or rupture?

*The literature shows very poor results when using only medical treatment. It is true that foreign material can be the permanent source of infection but, again, literature data and also our experiences show good results. Long-term ATB treatment is mandatory!*