

Retrograde Type A Ascending Dissection after Total Endovascular Aortic Arch Repair

Maximilian Luehr, MD^{1*}, Christian D. Etz, MD, PhD¹, Lukas Lehmkuhl, MD², Michael A. Borger, MD, PhD¹, Friedrich-Wilhelm Mohr, MD, PhD¹

¹Department of Cardiac Surgery, Leipzig Heart Center, University of Leipzig, Leipzig, Germany; and ²Department of Radiology, Leipzig Heart Center, University of Leipzig, Leipzig, Germany

Abstract

An 80-year-old man with aortic arch aneurysm successfully underwent surgical debranching of the supra-aortic branches followed by thoracic endovascular aortic repair of the transverse arch with 3 stent grafts via the femoral artery. His postoperative course was uneventful. However, on postoperative day 10, he developed acute chest pain and required cardiopulmonary resuscitation due to cardiac tamponade.

Copyright © 2014 Science International Corp.

Key Words

Dissection · Endovascular · CT scan · Stent graft · TEVAR

Introduction

An 80-year-old man with aortic arch aneurysm successfully underwent surgical debranching of the supra-aortic branches followed by thoracic endovascular aortic repair (TEVAR) of the transverse arch with 3 stent grafts via the femoral artery. His postoperative course was uneventful. However, on postoperative day 10, he developed acute chest pain and required cardiopulmonary resuscitation due to cardiac tamponade.

Computed tomography (CT) of the chest [Fig. 1–1D, sagittal plane, arrows; Video 1 (<http://dx.doi.org/10.12945/j.aorta.2014.14-001.vid.01>)] showed a retrograde type A aortic dissection extending into the

native ascending aorta and the aortic root. Emergent open reoperation with ascending aortic replacement was performed using bilateral selective cerebral perfusion and moderate hypothermia (28°C). The patient was discharged to a neurological rehabilitation clinic—despite preserved motor function—due to multi-infarction syndrome 2 weeks postoperatively.

Delayed retrograde type A aortic dissection is a rare—most likely underreported—fatal complication that may occur after TEVAR of the transverse arch. The potential mechanisms that may lead to retrograde dissection post-TEVAR are still unknown; however, various associations have been suggested: (1) stent graft oversizing during deployment [1], (2) the use of bare springs at the proximal end of the prosthesis [2,3], or (3) preexisting aortic pathology/intimal damage (Type B dissection, penetrating aorta ulcer, aortic ectasia, cross-clamping injury, compliance mismatch, etc.) [4]. With regard to these assumptions, we and others [5,6] strongly recommend replacing an ectatic ascending aorta (> 40 mm) to achieve an optimal proximal landing zone during the rerouting procedure.

These images illustrate that close CT surveillance for retrograde aortic dissection is essential—especially in patients with a proximal landing zone in the native, possibly ectatic ascending aorta—

*Corresponding author:
Maximilian Luehr, MD
Department of Cardiac Surgery
Leipzig Heart Center – University of Leipzig
Struempellstrasse 39
04289 Leipzig, Germany
Tel: +49 (0) 341 865 1421, Fax: +49 (0) 341 865 1452, E-Mail: maximilian.luehr@medizin.uni-leipzig.de



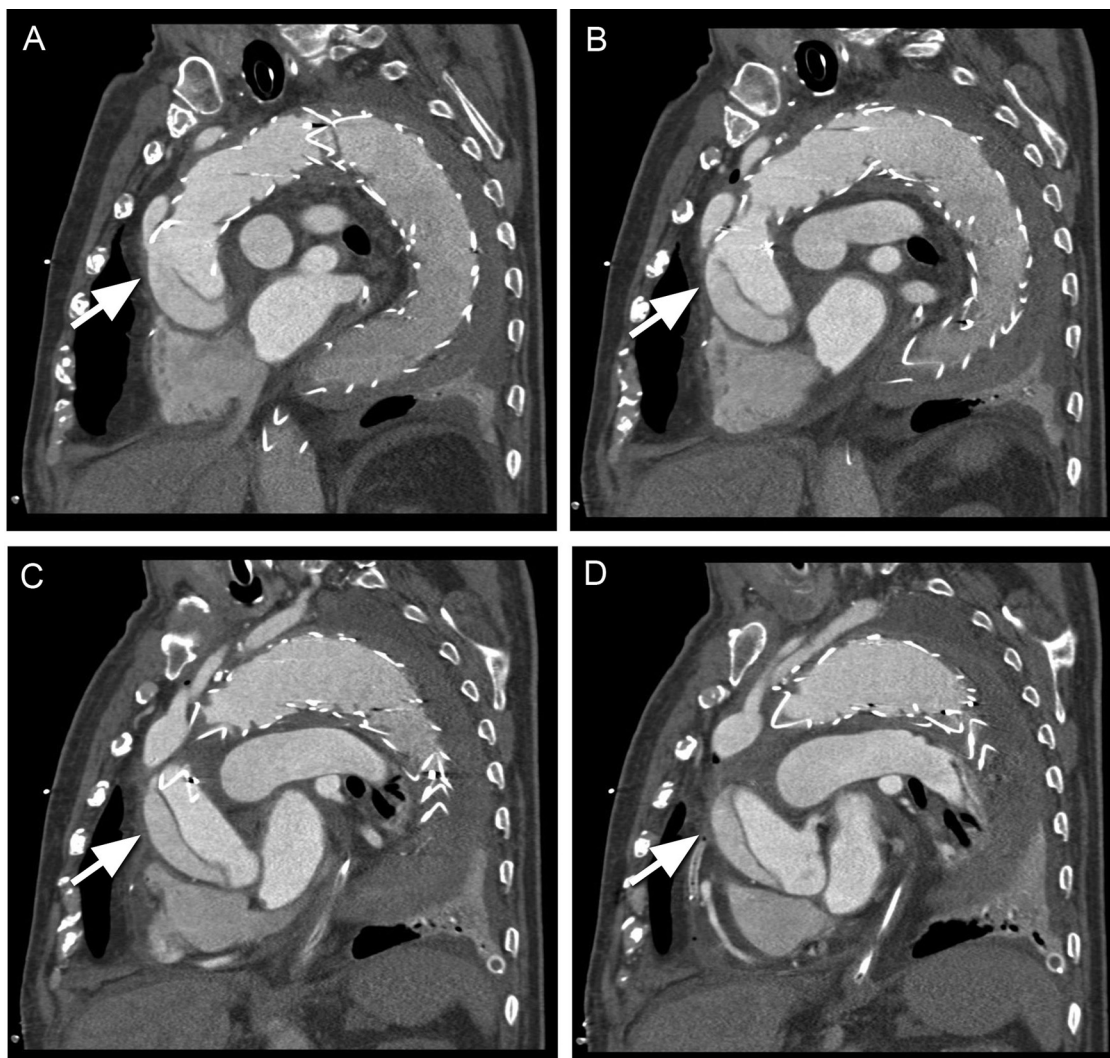


Figure 1. Computed tomography (CT) of the chest shows retrograde type A dissection involving the ascending aorta and the aortic root (panel A-D).

prior to discharge as well as during follow-up in a routine fashion. Physicians, clinicians, and surgeons should be aware of such potentially life-threatening complications after TEVAR that may occur without clinical symptoms even months to years after initial treatment.

Conflict of Interest

The authors have no conflict of interest relevant to this publication.

[Comment on this Article or Ask a Question](#)

References

1. Kpodonu J, Preventza O, Ramaiah VG, Shennib H, Wheatley GH 3rd, Rodriquez-Lopez JA, et al. Retrograde type A dissection after endovascular stenting of the descending thoracic aorta. Is the risk real? *Eur J Cardiothorac Surg.* 2008;33: 1014–1018. [10.1016/j.ejcts.2008.03.024](https://doi.org/10.1016/j.ejcts.2008.03.024)
2. Eggebrecht H, Thompson M, Rousseau H, Czerny M, Lönn L, Mehta RH, et al. Retrograde ascending aortic dissection during or after thoracic aortic stent graft placement: insight from the European registry on endovascular aortic repair complications. *Circulation.* 2009;120(11 Suppl):S276–S281. [10.1161/CIRCULATIONAHA.108.835926](https://doi.org/10.1161/CIRCULATIONAHA.108.835926)
3. Dong ZH, Fu WG, Wang YQ, Guo da Q, Xu X, Ji Y, et al. Retrograde type A aortic dissection after endovascular stent graft placement for treatment of type B dissection. *Circulation.* 2009; 119:735–741. [10.1161/CIRCULATIONAHA.107.759076](https://doi.org/10.1161/CIRCULATIONAHA.107.759076)
4. Czerny M, Weigang E, Sodeck G, Schmidli J, Antona C, Gelpi G, et al. Targeting landing zone 0 by total arch rerouting and TEVAR: midterm results of a transcontinental registry. *Ann Tho-*

- rac Surg. 2012;94:84–89. [10.1016/j.athoracsur.2012.03.024](https://doi.org/10.1016/j.athoracsur.2012.03.024)
5. Luehr M, Etz CD, Lehmkuhl L, Schmidt A, Misfeld M, Borger MA, et al. Surgical management of delayed retrograde type A aortic dissection following complete supra-aortic de-branching and stent-grafting of the transverse arch. *Eur J Cardiothorac Surg.* 2013;44:958–963. [10.1093/ejcts/ezt180](https://doi.org/10.1093/ejcts/ezt180)
6. Milewski RK, Szeto WY, Pochettino A, Moser GW, Moeller P, Bavaria JE. Have hybrid procedures replaced open aortic arch reconstruction in high-risk patients? A comparative study of elective open arch debranching with endovascular stent graft placement and conventional elective open total and distal aortic arch reconstruction. *J Thorac Cardiovasc Surg.* 2010;140:590–597. [10.1016/j.jtcvs.2010.02.055](https://doi.org/10.1016/j.jtcvs.2010.02.055)

Cite this article as: Luehr M, Etz CD, Lehmkuhl L, Borger MA, Mohr F-W. Retrograde Type A Ascending Dissection after Total Endovascular Aortic Arch Repair. *Aorta* 2014;2(2):84–86. DOI: <http://dx.doi.org/10.12945/j.aorta.2014.14-001>

EDITOR'S COMMENTS

We thank Dr. Luehr and his group for their very instructive case report. We feel that the setting of an iatrogenic intimal injury in a susceptible aorta recreates an experimental model for induction of aortic dissection.

We agree with the recommendation that ascending

replacement should be strongly considered for proximal landing zone creation. But, this begs the question: If one is to replace the ascending aorta, why do endografts at all? Why not just replace the aortic arch? After all, cardiopulmonary bypass is required to replace the ascending aorta.