

A Pregnant Patient with Native Aortic Coarctation and Aneurysm

Titia P. E. Ruys, MD, PhD^{1*}, Jos A. Bekkers, MD, PhD², Johannes J. Duvekot, MD, PhD³, Jolien W. Roos-Hesselink, MD, PhD¹

¹Department of Cardiology, Erasmus Medical Centre, Rotterdam, The Netherlands; ²Department of Cardiothoracic Surgery, Erasmus Medical Centre, Rotterdam, The Netherlands; and ³Department of Obstetrics and Gynecology, Erasmus Medical Centre, Rotterdam, The Netherlands

Abstract

Uncorrected coarctation is rare and is known to cause hypertension in adult patients. Retrospective observational studies showed hypertension and occasionally aortic dissection to be the principal risks during pregnancy after correction of aortic coarctation. We present a case of a patient with known hypertension, who presented at 32 weeks of gestation. A saccular aortic aneurysm of 4.5 × 8.8 cm was found by echocardiogram and confirmed with a chest X-ray. She delivered a healthy girl by caesarean section. After delivery a CT-angiography was performed showing a stable situation. Two months postpartum she was successfully operated. We present images of echocardiography, X-ray, CT and the surgical procedure. We discuss the literature on native coarctation and the management choices in this difficult case.

Copyright © 2014 Science International Corp.

Key Words

Aortic coarctation · Pregnancy · Thoracic aortic aneurysm · Delivery

Introduction

Aortic coarctation accounts for 6–9% of all congenital heart disease. In most cases aortic coarctation is discovered and treated during childhood. Uncorrected (native) coarctation in adult patients is rare. In adult life, uncorrected coarctation may lead to therapy-

resistant hypertension. Retrospective observational studies showed hypertension and occasionally aortic dissection to be the principal risks during pregnancy after correction of aortic coarctation [1,2]. The risks of pregnancy in patients with uncorrected coarctation are largely unknown.

Case Presentation

A 28-year-old pregnant woman presented at our outpatient clinic with severe hypertension at 32 weeks of gestation. Two previous pregnancies had also been complicated by hypertension (140/80); two healthy babies (3500 g) were delivered vaginally, but no diagnosis was made at that time. She had been hypertensive from the beginning of this pregnancy, but now she had complaints of shortness of breath during exercise; therefore, she was sent to our center for further evaluation. On physical examination we saw a healthy woman with a blood pressure of 186/80 mm Hg via the right arm and 126/65 mm Hg via the left arm. A systolic murmur grade 3/6 was heard best at the back. She had normal breath sounds and some minor peripheral edema. The ECG showed left ventricular hypertrophy. Echocardiography showed an increased systolic velocity of up to 4 m/s over the distal aortic arch and continuous anterograde flow throughout diastole. Furthermore, severe dilatation of the descending aorta, distal to the left subclavian artery,



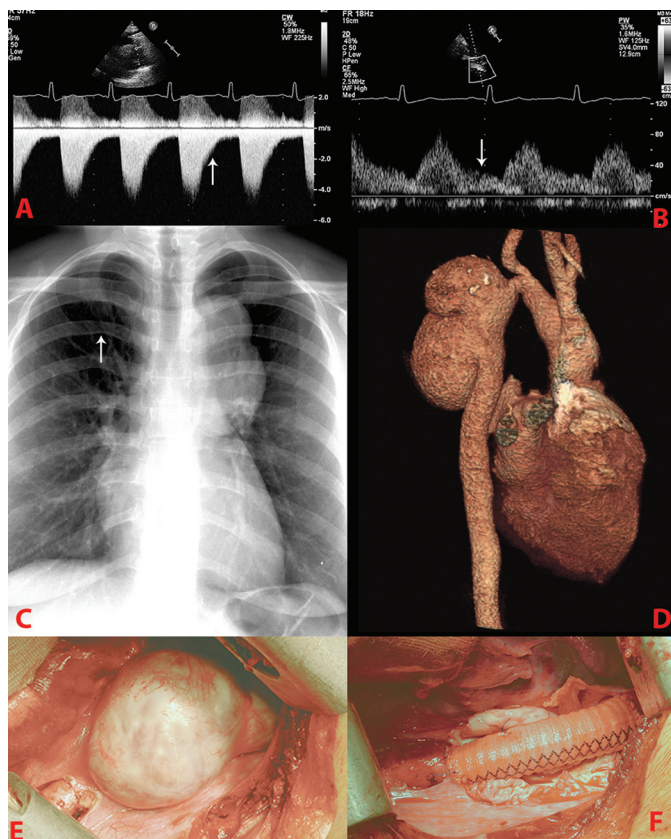


Figure 1. (A) Echocardiography: suprasternal view with continued Doppler waves of the descending aorta with diastolic runoff, as indicated by the arrow. (B) Echocardiography: pulsed wave Doppler of the abdominal aorta with diastolic runoff as indicated by the arrow. (C) Chest radiography showing rib notching (indicated by arrow) and aortic aneurysm. (D) See Video 1: 3D reconstruction of CT angiogram showing an aortic aneurysm of 4.5×8.8 cm. (E) Photograph of the aneurysm during operation. (F) Photograph of graft interposition after operation.

was discovered (Fig. 1A and 1B). The chest X-ray showed rib notching and signs of an aortic aneurysm (Fig. 1C). On MRI, the diagnosis of native coarctation (minimal diameter of 0.8 cm) and a huge saccular aortic aneurysm of 4.5×8.8 cm was confirmed. We monitored both mother (growth of the aneurysm) and baby for 3 weeks extensively, by echocardiography and X-rays. An elective caesarean section under regional anesthesia was performed at 35 weeks of gestation and a healthy girl (2625 g) was born. After delivery, a CT-angiography was performed which showed a stable (no change in size) aortic situation (Fig. 1D: see Video 1 [<http://dx.doi.org/10.12945/j.aorta.2014.13-038.vid.01>]). The patient was continuously monitored until 2 months post pregnancy, when

successful resection of the aneurysm and aortic coarctation, by graft interposition, was performed (Fig. 1E and 1F).

Comment

No other pregnant patient with native coarctation and aortic aneurysm has been described so far, to our knowledge. Beauchesne et al. [3] described a series of 44 pregnancies in 16 patients with native coarctation. In this series, 43% of the patients with native coarctation had hypertension. One patient died at 36 weeks of pregnancy of a Stanford Type A dissection; she had Turner syndrome. Seven additional cases have been published since 1990. The most frequently encountered problems were hypertension and miscarriage; no endocarditis or aneurysm was described [4–10].

Our patient was known to have hypertension, but the diagnosis of aortic coarctation was missed at earlier stages in her life. Although preeclampsia is the most prevalent cause of hypertension in pregnancy, in this case the diagnosis was aortic coarctation, which requires a high index of suspicion. The arm–leg blood pressure difference, the systolic murmur at the back, and a diastolic run-off Doppler pattern in the abdominal aorta can easily unmask the diagnosis. Our case stresses the importance of thorough physical examination and echocardiography in young patients with hypertension. The latter should always include Doppler registration of the abdominal aorta.

During pregnancy, due to hormonal changes, the aortic wall may become more vulnerable to dissection [11]. Choosing the optimal time and mode of delivery in this patient with native coarctation complicated by huge aneurysm formation was difficult. In such a challenging case, multiple factors have to be taken into account in the decision of timing and mode of delivery. In this case we used a shared decision model, informing both parents about the choices to be made. We wanted to plan the delivery, making sure that the team included the most experienced anesthesiologist and obstetrician. We preferred to deliver as soon as possible, to limit the risk of rupture of the aneurysm. Despite many discussions with the parents, the mother refused early delivery, because she thought that premature birth would have a negative influence on the baby. We convinced the mother that at 35 weeks the fetal lung maturation would be complete; therefore, at that point, the risk of the mother would outweigh the positive benefit for the baby.

We decided to plan caesarean section at 35 weeks, at a time when the most experienced specialists were available, and a thoracic surgeon would be able to give backup. According to the European Society of Cardiology guidelines, [12] an acute or chronic aortic dissection is one of the few reasons to plan a caesarean section. Although this was not the case in our patient, we decided we should try to limit the risk of rupture with a caesarean section. Our anesthetic approach in this case was to use an epidural anesthetic, with continuous hemodynamic monitoring. We did not use general anesthesia, since the hemodynamic changes could be kept minimal with a low-dose epidural, which was slowly increased. Perioperative management focused on minimizing hemodynamic disturbances, since it was thought that both high and low blood pressures could potentially be very dangerous in this case (possibly producing rupture or distal hypoperfusion).

The decision on timing of resection of the aneurysm was also challenging. In case of immediate surgery, there is a high risk of major hemorrhage, with hepa-

rinization during cardiac bypass being warranted as well as the presence of a fresh uterine wound bed. On the other hand, there are large hemodynamic shifts in the first days after delivery; the risk of rupture is considered highest during delivery and directly afterward. We chose to wait to let the placenta bed recover during the 2 months the patient was monitored with X-rays and echocardiography. She stayed in the hospital the first week after delivery on the medium care cardiology ward. Since the patient remained stable, surgery under full heparinization could be performed, when the uterus was considered completely healed and there was low bleeding risk.

Conflict of Interest

The authors have no conflict of interest relevant to this publication.

Comment on this Article or Ask a Question

References

- Vriend JW, Drenthen W, Pieper PG, Roos-Hesselink JW, Zwinderman AH, van Veldhuisen DJ, et al. Outcome of pregnancy in patients after repair of aortic coarctation. *Eur Heart J*. 2005;26:2173–2178. [10.1093/eurheartj/ehi338](https://doi.org/10.1093/eurheartj/ehi338)
- Krieger EV, Landzberg MJ, Economy KE, Webb GD, Opatowsky AR. Comparison of risk of hypertensive complications of pregnancy among women with versus without coarctation of the aorta. *Am J Cardiol*. 2011;107:1529–1534. [10.1016/j.amjcard.2011.01.033](https://doi.org/10.1016/j.amjcard.2011.01.033)
- Beauchesne LM, Connolly HM, Ammash NM, Warnes CA. Coarctation of the aorta: outcome of pregnancy. *J Am Coll Cardiol*. 2001;38:1728–1733. [10.1016/S0735-1097\(01\)01617-5](https://doi.org/10.1016/S0735-1097(01)01617-5)
- Venning S, Freeman LJ, Stanley K. Two cases of pregnancy with coarctation of the aorta. *J R Soc Med*. 2003;96:234–236. [10.1258/jrsm.96.5.234](https://doi.org/10.1258/jrsm.96.5.234)
- Singh BM, Kriplani A, Bhatla N. Vaginal delivery in a woman with uncorrected coarctation of aorta. *J Obstet Gynaecol Res*. 2004;30:24–26. [10.1111/j.1341-8076.2004.00150.x](https://doi.org/10.1111/j.1341-8076.2004.00150.x)
- Dessole S, D'Antona D, Ambrosini G, Fadda MC, Capobianco G. Pregnancy and delivery in young woman affected by isthmus coarctation of the aorta. *Arch Gynecol Obstet*. 2000;263:145–147. [10.1007/PL00007472](https://doi.org/10.1007/PL00007472)
- Walker E, Malins A. Anaesthetic management of aortic coarctation in pregnancy. *Int J Obstet Anesth*. 2004;13:266–270. [10.1016/j.ijoa.2004.03.001](https://doi.org/10.1016/j.ijoa.2004.03.001)
- Lip GY, Singh SP, Beevers D. Aortic coarctation diagnosed after hypertension in pregnancy. *Am J Obstet Gynecol*. 1998;179:814–815. [10.1016/S0002-9378\(98\)70089-4](https://doi.org/10.1016/S0002-9378(98)70089-4)
- Zwiers WJ, Blodgett TM, Vallejo MC, Finegold H. Successful vaginal delivery for a parturient with complete aortic coarctation. *J Clin Anesth*. 2006;18:300–303. [10.1016/j.jclinane.2005.10.004](https://doi.org/10.1016/j.jclinane.2005.10.004)
- Plunkett MD, Bond LM, Geiss DM. Staged repair of acute type I aortic dissection and coarctation in pregnancy. *Ann Thorac Surg*. 2000;69:1945–1947. [10.1016/S0003-4975\(00\)01278-9](https://doi.org/10.1016/S0003-4975(00)01278-9)
- Immer FF, Bansi AG, Immer-Bansi AS, McDougall J, Zehr KJ, Schaff HV, et al. Aortic dissection in pregnancy: analysis of risk factors and outcome. *Ann Thorac Surg*. 2003;76:309–314. [10.1016/S0003-4975\(03\)00169-3](https://doi.org/10.1016/S0003-4975(03)00169-3)
- European Society of Gynecology (ESG), Association for European Paediatric Cardiology (AEPC), German Society for Gender Medicine (DGesGM), Regitz-Zagrosek V, Blomstrom Lundqvist C, Borghi C, et al. ESC Guidelines on the management of cardiovascular diseases during pregnancy: the Task Force on the Management of Cardiovascular Diseases during Pregnancy of the European Society of Cardiology (ESC). *Eur Heart J*. 2011;32:3147–3197. [10.1093/eurheartj/ehr218](https://doi.org/10.1093/eurheartj/ehr218)

Cite this article as: Ruys TPE, Bekkers JA, Duvekot JJ, Roos-Hesselink JW. A Pregnant Patient with Native Aortic Coarctation and Aneurysm. *Aorta* 2014;2(3):110–112. DOI: <http://dx.doi.org/10.12945/j.aorta.2014.13-038>

EDITOR'S COMMENTS

Thank you for sharing this fascinating case. Congratulations on an excellent outcome for both mother

and daughter. You made some difficult high-risk decisions, which paid off.