Images in Aortic Disease

AORTA

Aorta, June 2013, Volume 1, Issue 1: 57–58
DOI: http://dx.doi.org/10.12945/j.aorta.2013.13.019

Received: March 18, 2013
Accepted: March 18, 2013
Published online: June 2013

Patient With a Massive Aortic Arch Aneurysm With Contained Rupture

Bulat A. Ziganshin

Aortic Institute, Yale University School of Medicine, New Haven, Connecticut

Key Words

Aortic arch aneurysm · Aneurysm rupture · Surgical treatment

The patient is a 66-year-old African American male who presented to an outside emergency room in serious condition with neck pain as well as neck and facial swelling and difficulty swallowing of about 5 weeks duration. He finally came for attention when the pain became very severe. He was a chronically ill-appearing male bordering on cachexia. His evaluation at the referring hospital showed an ascending and arch aneurysm with rupture of the aortic arch and a large mediastinal hematoma (Fig. 1A). The patient had a significant history of hypertension, dyslipidemia, chronic obstructive pulmonary disease, and heavy smoking. He was transferred to our institution for further care.

The preoperative computed tomography (CT) showed a massive ruptured aneurysm of the aortic arch measuring up to 11.7 cm (Fig. 2).

On entry into the pericardium we discovered a contained rupture of what turned out to be a false aneurysm containing a clot that had breeched the aortic wall, resulting in a large cavity between the innominate and left carotid arteries. The patient was placed on bypass through the femoral vessels and an aortic valve replacement (severe aortic regurgitation on echocardiogram), ascending aortic replacement (root sparing), and formal arch replacement with stage 1 elephant trunk was performed. Deep hypothermic circulatory arrest (31 minutes at 18°C) and bilateral antegrade cerebral perfusion (14 minutes at 400 cc/minute) was required for cerebral protection. The formal arch replacement included anastomosing the innominate artery and the left carotid artery end-to-end between each other with a 12-mm graft, which was then anastomosed with the main arch graft with a separate 10-mm graft end-to-side of both grafts (see Fig. 1B). The total bypass time and cross-clamp times were 214 and 163 minutes, respectively.

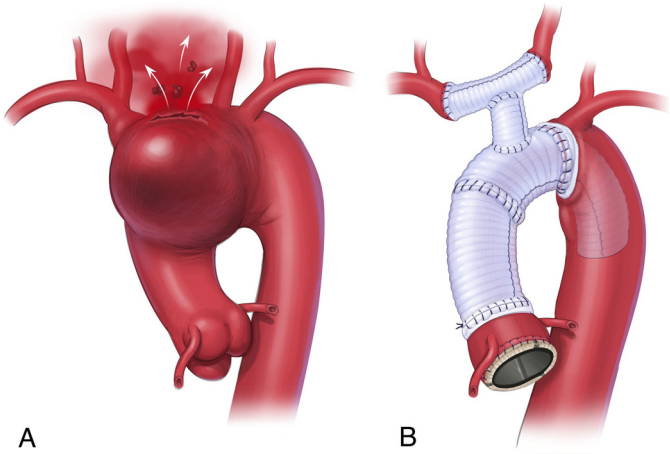

Figure 1. (A) Illustrates the appearance of the aortic arch rupture discovered intraoperatively. (B) Shows the complete reconstruction of the ascending aorta and aortic arch.

The patient had a difficult postoperative recovery, requiring reintubation. The patient also developed atrial fibrillation, which resolved before discharge. Five months postoperatively the patient is doing well.

Fax +1 203 785 3346
E-Mail: aorta@scienceinternational.org
http://aorta.scienceinternational.org

© 2013 Aorta.
Published by Science International Corp.
ISSN 2325-4637

Accessible online at:
http://aorta.scienceinternational.org

Corresponding author:
Bulat A. Ziganshin
Aortic Institute, Yale University School of Medicine
Boardman 204
330 Cedar St.
New Haven, CT 06510 (USA)
Tel. +1 203 785 2551, Fax +1 203 785 3346, E-Mail: bulat.ziganshin@yale.edu

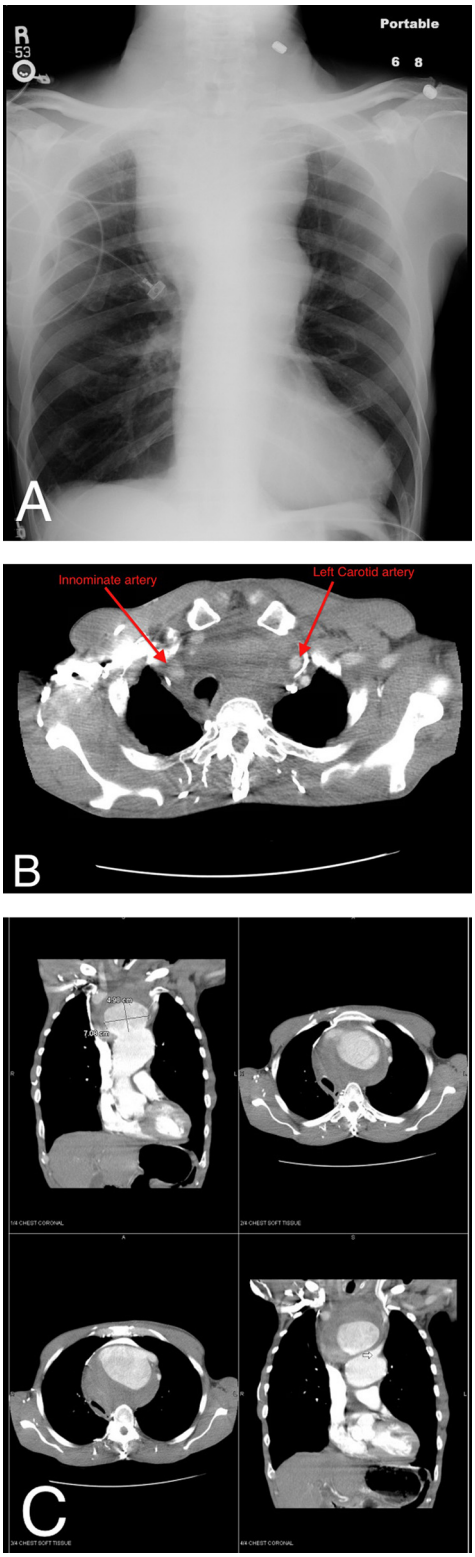

Figure 2. Preoperative chest X-ray (A) and CT scan images (B) and (C) showing a massive aneurysm of the aortic arch. On the axial CT image please note how far apart the innominate and left carotid arteries are.

This case is especially interesting for the extraordinary preoperative images of the aortic arch (Fig. 2). We encourage similar submissions to the AORTA journal's category "Images in Aortic Disease."

Comment on this Article or Ask a Question

Cite this article as: Ziganshin BA. Patient With a Massive Aortic Arch Aneurysm With Contained Rupture. Aorta 2013;1(1): 57–58. DOI: http://dx.doi.org/10.12945/j.aorta.2013.13.019