

Acute Total Occlusion of the Abdominal Aorta in an Elderly Patient with Atrial Fibrillation

Xiaoye He, MD, Yu Hu, MD*

Department of Geriatrics, Affiliated Zhongshan Hospital of Fudan University, Shanghai, China

Abstract

A 76-year-old man without regular anticoagulation therapy for his atrial fibrillation was found to have a complete occlusion of the abdominal aorta and bilateral iliac and femoral arteries, confirmed by multi-slice computed tomography angiography. Prompt diagnosis and immediate intervention are important to minimize complications and avoid fatal outcome whenever arterial occlusion is suspected or diagnosed.

Copyright © 2013 Science International Corp.

Introduction

A 76-year-old man presented with 5 hours of hypoesthesia of the lower extremities. He had chronic atrial fibrillation along with a past history of stroke and was not anticoagulated. He declined surgical intervention, and expired after supportive medical care and anticoagulation. Multi-slice computed tomography angiography of the patient's lower extremity vessels showed luminal narrowing in abdominal aorta below the left renal artery and the lower segment of abdominal aorta, and bilateral iliac, femoral, and other lower extremity arteries were occluded (Fig. 1).

Acute total occlusion of the abdominal aorta is rare and potentially catastrophic, as indicated in this case. It can be caused by embolus or thrombus, which obstructs distal arterial blood flow. Many factors such as atherosclerosis, dissection, or aneurysm [1] have been associated with aortic mural thrombi, and acute thrombosis

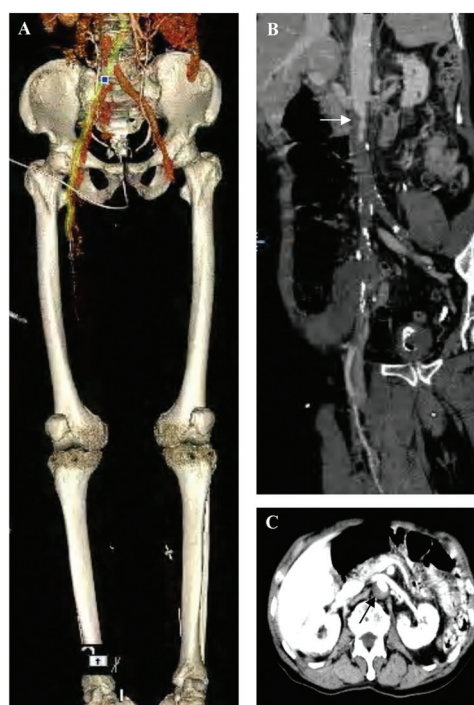


Figure 1. The whole image (A), 3-dimensional computed tomography image (B), and cross-sectional computed tomography images (C) of the patient. **Arrows** refer to the aortic occlusion position.

may also be related to identifiable hypercoagulable states [2–4]. The most common source of emboli is the heart, secondary to atrial fibrillation or myocardial infarction. The differentiation between embolus and thrombus can be difficult, but atrial fibrillation is viewed as a reliable discriminator [5].



Acute occlusion of the abdominal aorta is associated with high morbidity and mortality. The causes of death are not only associated with major organ ischemia, but also with severe respiratory failure, fatal arrhythmia, uncontrollable hyperkalemia, and renal failure secondary to myonecrosis [6]. Delay in diagnosis severely impacts prognosis. The clinical picture of acute arterial occlusion includes the classic 6 "P's": pain, paresthesia, paralysis, pallor, pulse-

lessness, and poikilothermia. Immediate intervention is important to minimize complications and avoid fatal outcome whenever aortic occlusion is suspected or diagnosed. Heparin alone is not effective, and aggressive treatment is essential, with embolectomy, surgical therapy, and, when necessary, amputation.

Comment on this Article or Ask a Question

REFERENCES

1. Sheikhzadeh A, Ehlermann P. Atheromatous disease of the thoracic aorta and systemic embolism. Clinical picture and therapeutic challenge. *Z Kardiol*. 2004;93:10–17. [10.1007/s00392-004-1030-z](https://doi.org/10.1007/s00392-004-1030-z)
2. Poirée S, Monnier-Cholley L, Tubiana JM, Arrivé L. Acute abdominal aortic thrombosis in cancer patients. *Abdom Imaging*. 2004;29:511–513.
3. Kaushik S, Federle MP, Schur PH, Krishnan M, Silverman SG, Ros PR. Abdominal thrombotic and ischemic manifestations of the antiphospholipid antibody syndrome: CT findings in 42 patients. *Radiology*. 2001;218:768–771. [10.1148/radiology.218.3.r01fe43768](https://doi.org/10.1148/radiology.218.3.r01fe43768)
4. Gouin-Thibaut I, Samama MM. Venous thrombosis and cancer. *Ann Biol Clin (Paris)*. 2000;675–682.
5. Cambria RP, Abbott WM. Acute arterial thrombosis of the lower extremity. Its natural history contrasted with arterial embolism. *Arch Surg*. 1984;119:784–787. [10.1001/archsurg.1984.01390190028006](https://doi.org/10.1001/archsurg.1984.01390190028006)
6. Surowiec SM, Isiklar H, Sreeram S, Weiss VJ, Lumsden AB. Acute occlusion of the abdominal aorta. *Am J Surg*. 1998;76:193–197. [10.1016/S0002-9610\(98\)00129-9](https://doi.org/10.1016/S0002-9610(98)00129-9)

Cite this article as: He X, Hu Y. Acute Total Occlusion of the Abdominal Aorta in an Elderly Patient with Atrial Fibrillation. *Aorta* 2013;1(5):255–256. DOI: <http://dx.doi.org/10.12945/j.aorta.2013.13-039>