Dr. Cooley's Inaugural Article

AORTA

Aorta, June 2013, Volume 1, Issue 1: 1–3
DOI: http://dx.doi.org/10.12945/j.aorta.2013.12.006

Received: October 16, 2012
Accepted: October 26, 2012
Published online: June 2013

A Brief History of Aortic Aneurysm Surgery

Denton A. Cooley

Dr. Cooley is Surgeon-in-Chief and President Emeritus of the Texas Heart Institute at St. Luke's Episcopal Hospital in Houston, Texas

Key Words

Aorta · Aortic disease · Aneurysm · Medical history

For centuries, aortic disease has been a major problem of mankind. Hieroglyphic texts from ancient Egypt attest to the presence of aortic aneurysms millennia before the birth of Christ. Although no medical solution for aneurysms was available in that era, the advice allegedly given for the care of affected patients was a passionate plea, which simply stated, "*Do not abandon them*." As medical history reveals, the treatment of aortic aneurysms did not progress significantly until modern times. Most measures used to control these lesions were attempts to relieve pain and forestall inevitable rupture. Efforts to promote thrombosis by introducing foreign bodies, such as wire and other substances, were sometimes successful but more often ineffective. Other efforts were aimed at strengthening or reinforcing the wall of the aneurysm to retard its growth. Many different measures were tried, but their success was limited. A major advance took place in 1888, when Rudolph Matas reported an internal repair technique known as endoaneurysmorrhaphy for treating arterial lesions. In this approach, he excised the clot from the aneurysmal sac and sutured the orifices of the arteries that entered the sac, from within, reestablishing continuous blood flow.

More aggressive or definitive treatment became available only in the second half of the 20th century. Encouraged by experience with the surgical treatment of wounds during World War II, surgeons began taking a more direct approach to cardiovascular lesions. A few case reports concerning the repair of small sacciform aneurysms appeared in the medical literature, but there were no recommendations for definitive surgery.

In December 1951, I presented a paper that Dr. Michael DeBakey and I had written entitled, "Surgical Considerations of Intrathoracic Aneurysms of the Aorta and Great Vessels," [1] at a meeting of the Southern Surgical Association (Fig. 1). The paper described six cases in which excision and aortorrhaphy had been performed. During the discussion that followed the presentation, the renowned surgeon Dr. Evarts Graham complimented us on our paper and suggested that it was a landmark in vascular surgery. Shortly afterward, I performed the first repair of a ruptured abdominal aneurysm [2]; the patient survived for 5 days, then died of kidney failure. I soon repaired four more ruptured aneurysms. In 1952, Dr. DeBakey and I were the first to use a homograft to repair a large aneurysm of the thoracoabdominal aorta [3]. Later, we successfully used homografts to replace the ascending aorta (1956) [4] and the aortic arch (1957) [5].

During the same period, many other surgeons made important contributions to aneurysm treatment. Among those pioneers were Henry Bahnson and his colleague, Frank Spencer, who began an active aortic surgery program at Johns Hopkins Hospital. Soon, many other surgeons and institutions established programs for treating aortic aneurysms and occlusive disease.

Since that time, aortic disease has continued to hold widespread interest for surgeons and other specialists. Countless symposia and publications have resulted. Many advances in diagnosis and

Fax +1 203 785 3346
E-Mail: aorta@scienceinternational.org
http://aorta.scienceinternational.org

© 2013 Aorta.
Published by Science International Corp.
ISSN 2325-4637

Accessible online at:
http://aorta.scienceinternational.org

Corresponding author:
Denton A. Cooley
Texas Heart Institute
MC 3-258, PO Box 20345
Houston, TX 77225-0345 (USA)
Tel. +1 832 355 4932, Fax +1 832 355 3424, E-Mail: dcooley@heart.thi.tmc.edu

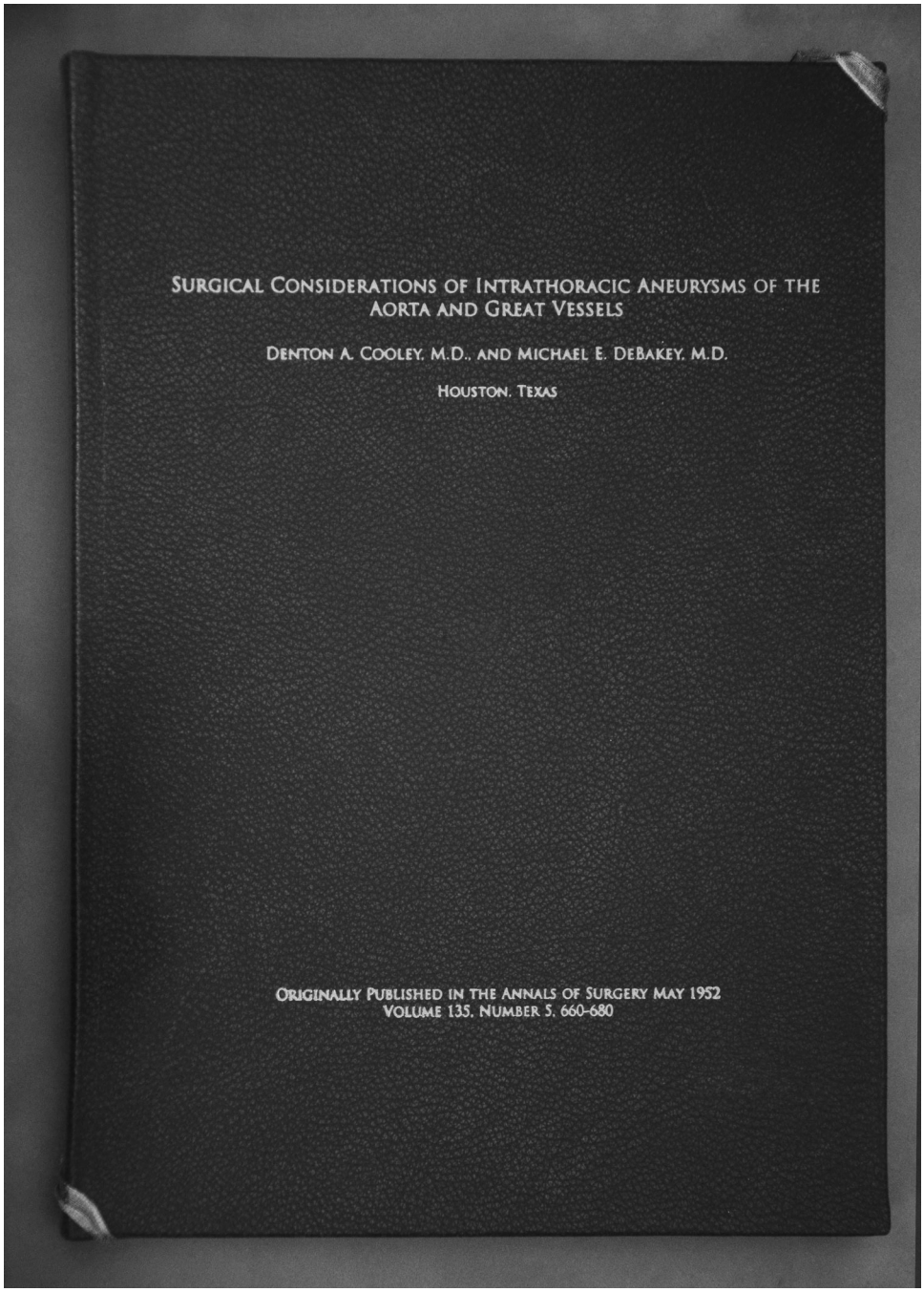

Figure 1. A leather-bound copy of the historic and seminal paper that I presented to the Southern Surgical Association in 1951, which is now prominently displayed in the Wallace D. Wilson Museum at the Texas Heart Institute. I am proud to have participated in the initial stimulus for aortic aneurysm surgery.

treatment have occurred, such as aortography, the introduction of vascular grafts and anticoagulants, and the techniques of cardiopulmonary bypass and induced hypothermia. More recently, noninvasive diagnostic methods have been introduced, including ultrasonography, computed tomography, and MRI. In the last part of the 20th century, the goal of treatment reverted to endoaneurysmorrhaphy, with use of a suitable graft to restore aortic continuity. Today, the emphasis is on catheter placement of prosthetic grafts, a less invasive approach to these lesions.

It is highly appropriate now that Dr. John Elefteriades, of the Yale University School of Medicine, has created a specialty journal, *AORTA*, devoted entirely to aortic disease. Dr. Elefteriades has long been a world-renowned leader in cardiovascular surgery. I applaud this new journal and am sure that it will contain many articles of interest.

Comment on this Article or Ask a Question

References

1. Cooley DA, DeBakey ME. Surgical considerations of intrathoracic aneurysms of the aorta and great vessels. Ann Surg. 1952;135:660–680. 10.1097/00000658–195205000-00010
2. Cooley DA, DeBakey ME. Ruptured aneurysms of abdominal aorta; excision and homograft replacement. Postgrad Med. 1954; 16:334–342.
3. Cooley DA, DeBakey ME. Successful resection of aneurysm of thoracic aorta and replacement by graft. JAMA. 1953;152:673–676. 10.1001/jama.1953.03690080017005
4. Cooley DA, DeBakey ME. Resection of entire ascending aorta in fusiform aneurysm using cardiac bypass. JAMA. 1956;162:1158–1159. 10.1001/jama.1956.72970290003013a
5. DeBakey ME, Crawford ES, Cooley DA, Morris GC Jr. Successful resection of fusiform aneurysm of aortic arch with replacement by homograft. Surg Gynecol Obstet. 1957;105:657–664.

Cite this article as: Denton A. Cooley. A Brief History of Aortic Aneurysm Surgery. Aorta 2013;1(1):1–3. DOI: http://dx.doi.org/10.12945/j.aorta.2013.12.006