

Therapy of deep vein thrombosis

M. Finkenrath

Hospital zum Heiligen Geist, Akadem. Lehrkrankenhaus der Universität Düsseldorf, Kempen

With an annual incidence of one to two per 1000 persons, deep vein thrombosis (▶ Fig. 1) with or without pulmonary embolism (▶ Fig. 2) is a common disease (according to a publication of the Bavarian

Medical Journal from 2015). Deep vein thrombosis, without a concurrent malignancy, reduces the life expectation on average by 5 years. Hence treatment of this disease assumes a high significance. Treat-

ment guidelines have been and continue to be constantly updated, most recently in 2016 (1). In addition, in October 2017 (publication in the German Medical Journal [Dt. Ärzteblatt Volume 41/2017]), the action group “Thrombosis” produced a traffic light diagram (▶ Table 3 at the end of the text [2]) regarding a possible extension of the period of treatment. This diagram reminds specialists in all disciplines once more of the importance and severity of the disease and its correct treatment.

Recognition of the disease at an early stage and initiation of the correct treatment for deep vein thrombosis has several aims: firstly to avoid the danger of appositional thrombus growth with potential embolisation in the lungs. This often happens asymptotically, but in the case of a fulminant pulmonary embolism, can also be a potentially life-threatening complication (3). Furthermore, adequate treatment should favour subsequent recanalisation and avoid the development of post-thrombotic syndrome. Early effective treatment is also aimed at preventing thrombosis recurrence.

In everyday practice, diagnosis should identify the cause, since this can have consequences for treatment, such as the decision concerning the duration of anticoagulation. If the cause cannot be deduced directly from the medical history (long flights or coach journeys, immobility etc.) – which happens in about half of the cases encountered in clinical routine practice – and if additional risk factors (young patient age, atypical thrombosis, positive family history) are present, the possibility of thrombophilia or a malignant disease should be excluded.

In most cases, treatment is conservative and consists of two main pillars: external compression and therapeutic anticoagulation.

External compression in the acute phase is achieved by a compression bandage applied according to Fischer. After the initial

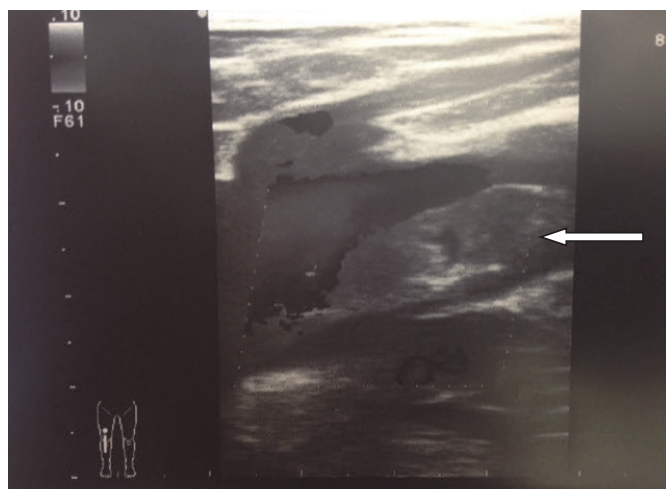


Fig. 1

Colour-coded duplex ultrasonography. Longitudinal section: Deep vein thrombosis of the femoral vein, floating thrombus (arrow) in the region of the deep femoral vein junction (source: M. Finkenrath)

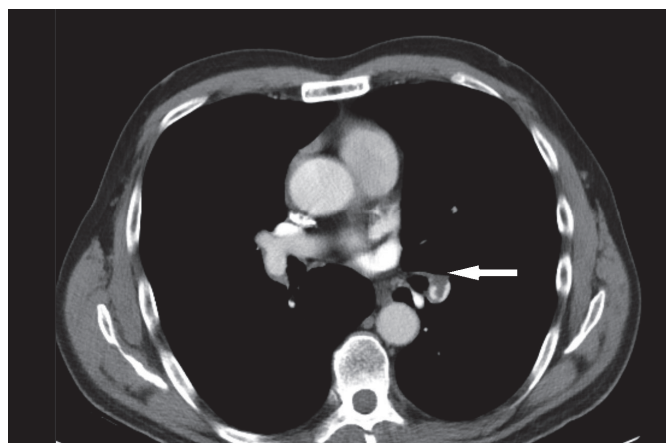


Fig. 2

Contrast-enhanced CT angiography of the pulmonary artery: parietal thrombus (arrow) in the right pulmonary artery (source: M. Finkenrath).

Correspondence to:

Dr. med. Meike Finkenrath
Chefärztin Phlebologie
Fachärztin für Dermatologie
ZB Phlebologie, Allergologie, Proktologie
Medizinische Begutachtung
Hospital zum Heiligen Geist
Akadem. Lehrkrankenhaus der Universität Düsseldorf
Von-Broichhausen-Allee 1
47906 Kempen
Tel. 02152 142–500
Fax 02152 142–322
E-Mail: meike.finkenrath@krankenhaus-kempen.de

Therapie der tiefen Beinvenenthrombose

Phlebologie 2018; 47: 364–367
<https://doi.org/10.12687/phleb2457-6-2018>
Eingegangen: 03. September 2018
Angenommen: 07. September 2018

swelling has subsided, a circular knit medical compression stocking is prescribed (usually Class II, often A-D adequate). Compression therapy is intended to reduce the clinical symptoms of congestion and prevent post-thrombotic syndrome – though this latter aspect is questioned in more recent studies (SOX study).

Therapeutic anticoagulation should begin immediately after diagnosis. In Germany, drugs licensed for thrombosis therapy are unfractionated heparin, low molecular weight heparins (LMWH), selective factor Xa inhibitors (for example fondaparinux), vitamin K antagonists and the new, non-vitamin K antagonising oral anti-

coagulants (NOACs), (► Table 1 [1]). Since vitamin K antagonists such as Marcumar (phenprocoumon) need several days to reach their therapeutic effect, they are not suitable for treatment in the acute phase. This treatment is nowadays generally carried out with LMWHs or NOACs.

Tab. 1 Initial anticoagulation and maintenance therapy in venous thrombosis/pulmonary embolism (1); LMWH = low molecular weight heparin; UFH = unfractionated heparin; FDX = fondaparinux; IU = international units; BW = body weight; *Observe product-specific approval situation; **enoxaparin

Drug/group	Active substance	Product	Manufacturer	Initial dose / Start medication	Maintenance dose	Application	Lab. monitoring/testing
LMWH	Certoparin	Mono-Embolex® 8000 I.U. therapy	Aspen Germany	8000 IU	* 8000 IU	2x sc / d	Generally not required, if necessary Anti-Xa test
	Dalteparin	Fragmin®	Pfizer	100 IU/kg BW	* 100 IU/kg BW	2x sc / d	
	Dalteparin	Fragmin®	Pfizer	200 IU/kg BW	* 200 IU/kg BW	1x sc / d	
	Enoxaparin**	Clexane®	Sanofi	1.0 mg/kg BW	* 1.0 mg/kg BW	2x sc / d	
	Nadroparin	Fraxiparine®	Aspen Germany	0.1 ml/10kg BW	* 0.1 ml/10kg BW	2x sc / d	
	Nadroparin	Fraxodi®	Aspen Germany	0.1 ml/10kg BW	* 0.1 ml/10kg BW	1x sc / d	
	Reviparin	Clivarin®	MylanHealthcare GmbH	0.6 ml for BW 45–60 kg	* 0.6 ml for BW 45–60 kg	2x sc / d	
	Reviparin	Clivarodi®	MylanHealthcare GmbH	0.6 ml for BW > 60 kg	* 0.6 ml for BW > 60 kg	1x sc / d	
	Tinzaparin	innohep®	LEO Pharma GmbH	175 IU/kg BW	* 175 IU/kg BW	1x sc / d	
Pentasaccharide	Fondaparinux	Arixtra®	Aspen Germany	7.5 mg 5 mg for BW < 50 kg 10 mg for BW > 100 kg	* 7.5 mg 5 mg for BW < 50 kg 10 mg for BW > 100 kg	1x sc / d	Generally not required, if necessary Anti-Xa test
UFH	Heparin calcium	Heparin-Calcium®	ratiopharm	Bolus 5000 IU, then 15–20 IU/kg BW/h	* approx. 15–20 IU/kg BW/h	Bolus iv, then iv- infusion or 2x sc / d	Always required with aPTT
	Heparin sodium	Heparin-Natrium®	B.Braun Melsungen, ratiopharm				
Direct oral anticoagulants	Dabigatran etexilate	Pradaxa®	Boehringer Ingelheim International GmbH	LMWH, UFH or FDX min. 5 days	150 mg	2x oral / d	Generally not required, if necessary measure levels
	Rivaroxaban	Xarelto®	Bayer Healthcare	15 mg 2x/d oral 3 wk.	20 mg	1x oral / d	
	Apixaban	Eliquis®	Bristol-Myers Squibb	10 mg 2x/d oral 1 wk.	5 mg	2x oral / d	
	Edoxaban	Lixiana®	Daiichi-Sankyo	NMH, UFH or FDX min. 5 days	60 mg	1x oral / d	
Vitamin K antagonists***	Phenprocoumon	Marcumar® Falthrom®	MedaPharma GmbH & Co Hexal AG	6 mg/d on 1st and 2nd. days; LMWH, UFH or FDX parallel until INR ≥ 2.0	approx. 1.5 – 4.5 mg continued alone if INR ≥ 2.0	1x oral / d	Always required, INR target range 2.0–3.0
	Warfarin sodium	Coumadin® 5 mg	Bristol-Myers Squibb	2.5–5 mg/d on 1st and 2nd days; LMWH UFH or FDX parallel until INR ≥ 2.0	approx. 2.5 – 10.0 mg continued alone if INR ≥ 2.0	1x oral / d	

After the first use of intravenous heparin in 1939 and warfarin in 1954, the introduction of LMWH in 1985 was a milestone in the treatment of thrombosis, because subcutaneous administration became possible and laboratory monitoring of clotting was no longer necessary (4). Hence there was no need for hospital admission and in most cases, deep vein thrombosis was treated on an outpatient basis.

A further important development was the marketing authorisation of the NOACs dabigatran and rivaroxaban in 2008 (5, 6). Even in the acute therapy of deep vein thrombosis, these drugs can be administered orally, which increases the patient's

quality of life (and improves compliance). The initial treatment with these direct oral anticoagulants is either with the same drug as in the subsequent maintenance phase – but at a higher dose – or in combination with a parenteral anticoagulant (LMWH or fondaparinux). The baseline clotting status, including measurement of the platelet count, must be established before the start of any anticoagulant therapy and renal function must be checked.

In routine clinical practice, surgical or interventional recanalisation measures are only required in special cases such as ileo-femoral thrombosis in young patients (e.g. May-Turner syndrome) or to preserve the

extremity in Phlegmasia coerulea dolens. Such measures can also only be generally undertaken with relatively fresh thromboses (thrombus age up to 14 days), because adherence of the thrombus to the venous wall is already high with older thromboses and the clot can no longer be removed without destroying the venous valves. Evidence on the effectiveness of the recanalising technique is limited, but there are suggestions that with correct diagnosis and patient selection, the incidence of post-thrombotic syndrome can be reduced (7). Whether surgical or interventional, catheter-assisted techniques are used, is of secondary importance.

The patient should return for a repeat colour-coded compression duplex ultrasonography at the end of the minimum period of three months of full anticoagulation. If the scan shows no recurrence and/or no new thrombosis, the question then arises whether treatment should be prolonged or not. The guidelines set out the following criteria to aid this decision (► Table 2):

This table lists ongoing cancer treatment, antiphospholipid syndrome, clotting inhibitor deficiency of protein C, S or anti-thrombin and a > 40% narrowing of the lumen caused by a residual thrombus as risk factors. Men also have a 60% higher probability of recurrence than women.

The patients should be told about all treatment options and their wishes taken into account after they have been fully informed (compliance). During this decision-making process, the risk of recurrence

Criterion	For continued therapy	Against continued therapy
Risk factor	ongoing	transient
Genesis	unclear	triggered
Recurrence	yes	no
Risk of bleeding	slight	high
Previous quality of anticoagulation	good	poor
D-dimers (after end of treatment)	increased	normal
Residual thrombus	present	absent
Sex	male	female
Thrombus extent	long	short
Thrombus site	proximal	distal
Severe thrombophilia	yes*	no**
Patient preference	for it	against it

Tab. 2

Criteria for or against a prolonged maintenance therapy with anticoagulants (1); * e.g. antiphospholipid syndrome, ** e.g. heterozygous factor V or heterozygous prothrombin mutation

Red light	Severe thrombophilia	High risk of recurrence	Continue anticoagulation
	Active malignancy	High risk of recurrence	Continue anticoagulation
	Persistent risk factor	High risk of recurrence	Continue anticoagulation
Amber light	Unprovoked DVT	Consider prolonged maintenance therapy	Clarify other results with specialist
	Recurrent VTE	Consider prolonged maintenance therapy	Clarify other results with specialist
	DVT after soft, uncertain risk factor	Consider prolonged maintenance therapy	Clarify other results with specialist
Green light	Clear, hard risk factor (OP, plaster, immobility)	Low risk of recurrence	Stop anticoagulation after 3–6 months
	Contraceptive pill or hormone therapy(now stopped)	Low risk of recurrence	Stop anticoagulation after 3–6 months
	Calf vein thrombosis	Low risk of recurrence	Stop anticoagulation after 3–6 months

Tab. 3

Traffic light illustration for possible prolonged treatment period (2)

must be weighed against the estimated risk of bleeding and a treatment chosen that is tailored to the individual situation of the patient.

This also applies to special entities such as the treatment of venous thrombosis in pregnancy, during which LMWH are preferable because they do not cross the placenta. Vitamin K antagonists are contraindicated in pregnancy for this reason (can cross the placenta).

Treatment of venous thrombosis in patients with active malignancies is also somewhat different. Hitherto, it was thought that LMWH should also be given in such cases for a period of at least three months, though the somewhat higher risk of bleeding has to be weighed against the tumour-associated increase in thrombogenicity (in the sense of the risk of recurrence). However, here too there have been changes recently, for example a pilot study (comparison of rivaroxaban versus dalteparin) showed that NOACs could be used

in certain cases and possibly on a long-term basis in this group of patients. This would also mean a significant plus in their quality of life due to the oral form of administration.

In conclusion, as stated in the final sentence of the guidelines: "Patients with venous thrombosis at any site and of any morphology ("free-floating thrombus") must not be immobilised unless to relieve severe pain". Immobilisation was previously often practiced in the belief that it would prevent embolisation of the thrombus and a pulmonary embolism. However, several studies have clearly shown that the rate of pulmonary embolism is not higher in mobile patients and the reduction in swelling and freedom from pain in the affected extremity is even promoted by early mobilisation (8). This aspect has also contributed to the possibility of treating most patients with deep vein thrombosis in an outpatient setting.

References

1. AWMF-Leitlinie (AWMF-Leitlinien-Register Nr.065/002). Diagnostik und Therapie der Venenthrombose und der Lungenembolie; Veröffentlichung in: *Vasa* 2016; 45 (Suppl. 90): 1–48 (S2k-Leitlinie).
2. Online-Veröffentlichung des Dt. Ärzteblatts Heft 41/2017; <https://www.aerzteblatt.de/nachrichten/81844/Thrombose-Antikoagulations-Ampel-als-Orientierungshilfe>.
3. Esmon CT. Basic mechanisms and pathogenesis of venous thrombosis. *Blood Rev* 2009; 23: 225–229.
4. Haas S, Bramlage P. *Vasomed* 2015; 27: 116–123.
5. Schulman S. *Blood* 2017; 129(25): 3285–3293.
6. Weitz JI, Harenberg J. *ThrombHaemost* 2017; 117(7): 1283–1288.
7. Strandness DE, Jr, Langlois Y, Cramer M, Randlett A, Thiele BL. Longterm sequelae of acute venous thrombosis. *JAMA* 1983; 250: 1289–1292.
8. Douketis J, Tosetto A, Marcucci M, Baglin T, Cosmi B, Cushman M, Kyrle P, Poli D, Tait R.c., Lorio A. Patient-level meta-analysis: effect of measurement timing, threshold, and patient age on ability of D-dimer testing to assess recurrence risk after unprovoked venous thromboembolism. *Ann Intern Med* 2010; 153: 523–531.