

Perforating veins incompetence

K. Korsake

Department of Vascular and Endovascular Surgery/Phlebology, Dessau City Hospital, Dessau-Roßlau

Keywords

Perforating veins, varikosis, duplex ultrasound, venous insufficiency

Summary

Perforating veins connect the superficial and deep venous system. In the diagnosis and treatment of varicosis, perforating veins are of high importance in search for the most proximal and most distal point of insufficiency. The examination of the perforating veins is a challenge in duplex sonography. The pathophysiological relevant significant incompetent perforating veins should be treated with surgical or minimal invasive methods.

Schlüsselwörter

Perforansvenen, Varikosis, Duplex, Veneninsuffizienz

Zusammenfassung

Perforansvenen verbinden die epifaszialen Beinvenen mit den subfaszial gelegenen tiefen Venen und dienen zur Drainage des venösen Blutflusses. In der Diagnostik und Therapie einer Varikosis haben die Perforansvenen eine große Bedeutung beim Aufsuchen des proximalen und distalen Insuffizienzpunkt. Die Untersuchung der Perforansvenen ist eine Herausforderung in der Duplexsonographie. Die pathophysiologisch bedeutsamen insuffizienten Perforansvenen sollten operativ oder minimal invasiv ausgeschaltet werden.

Correspondence to:

Dr. med. Kristina Korsake
Klinik für Gefäß- und Endovaskuläre Chirurgie/Phlebologie
Städtisches Klinikum Dessau, Auenweg 38
D-06847 Dessau-Roßlau
E-Mail: kristina.korsake@gmail.com

Perforansinsuffizienz

Phlebologie 2018; 47: 279–285
<https://doi.org/10.12687/phleb2442-5-2018>
Received: 10. Juli 2018
Accepted: 23. Juli 2018

Definition

A perforating vein is one that connects a vein that is part of the deep truncal vein system with an epifascial vein that penetrates the fascia. The physiological direction of flow of a perforating vein is from the surface into the deep tissues. If a perforating vein is incompetent, then the direction of flow in it is reversed and the superficial vein becomes congested (1) (► Fig. 1).

More than 40 perforating veins that are always present in a particular location have been described in the literature (2). Perforating veins are considerably more numerous in the lower leg than in the thigh.

The perforating veins most commonly involved in varicose veins are depicted in ► Figures 2 and 3.

Classification

In routine clinical practice, perforating veins are often known by the names of the physicians who first described them. However, according to the more recent, international nomenclature, the perforators are no longer described eponymously, but on the basis of their topography. However, the old designations are still widely used in clinical parlance (3). For example, according to the new nomenclature, Cockett's perforators are now called the posterior tibial perforator veins (► Figs. 5 and 6). A summary of the old and new names is shown in ► Table 1.

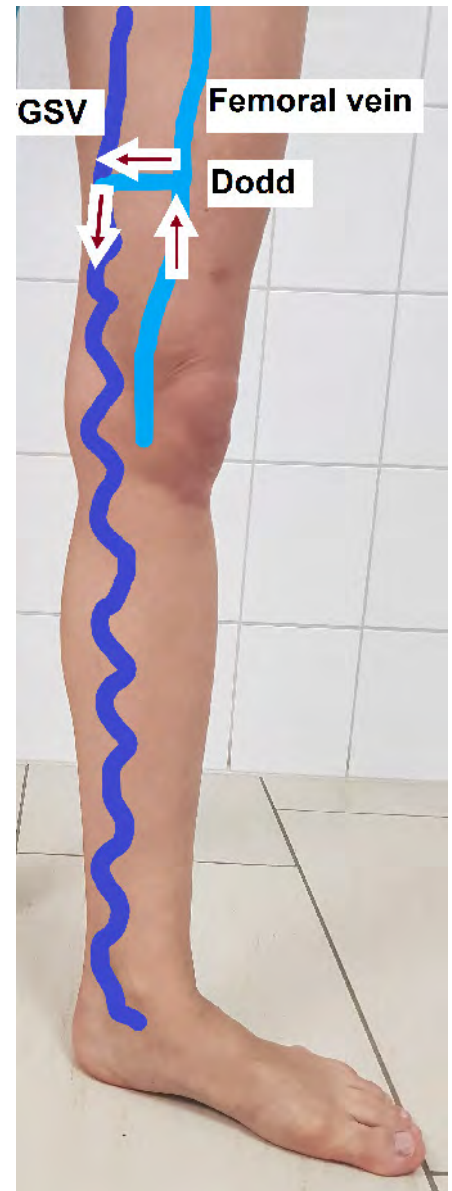

Fig. 1 Incompetent Dodd perforator with reversal of flow into the GSV

Diagnosis

Clinical and imaging methods can be used to assess the functioning of perforator veins during the diagnostic workup of varicose veins and CVI.

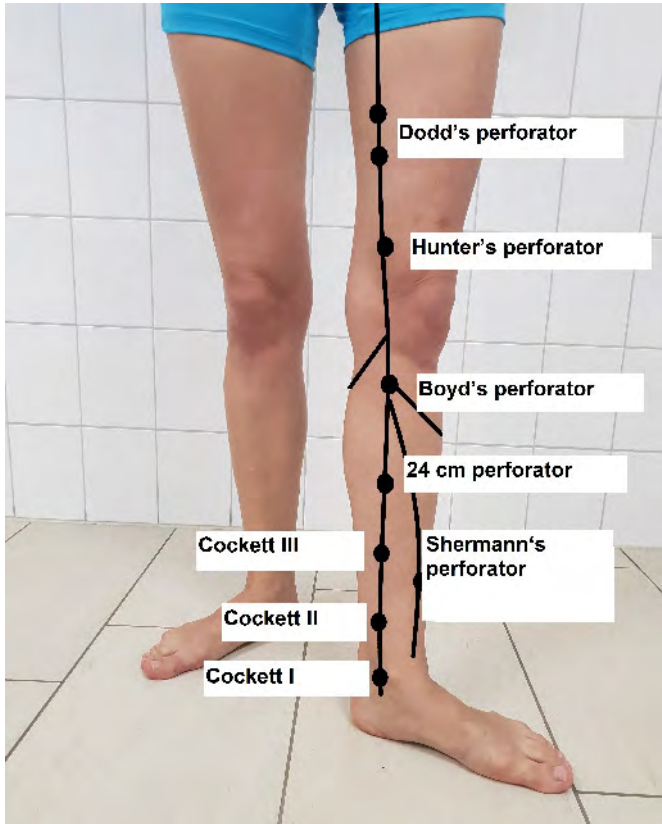


Fig. 2 Ventral view of the location of the best-known perforating veins

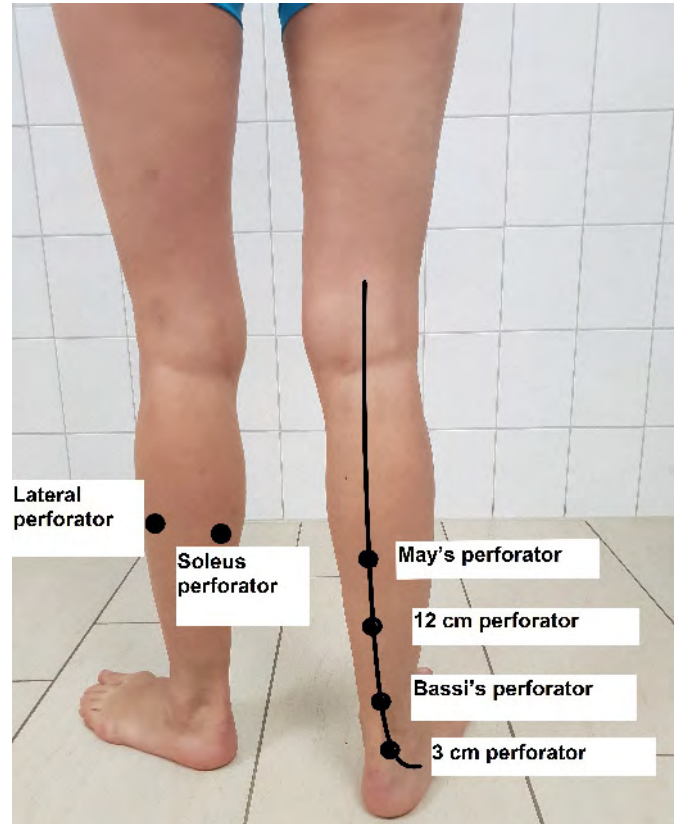


Fig. 3 Dorsal view of the location of perforating veins

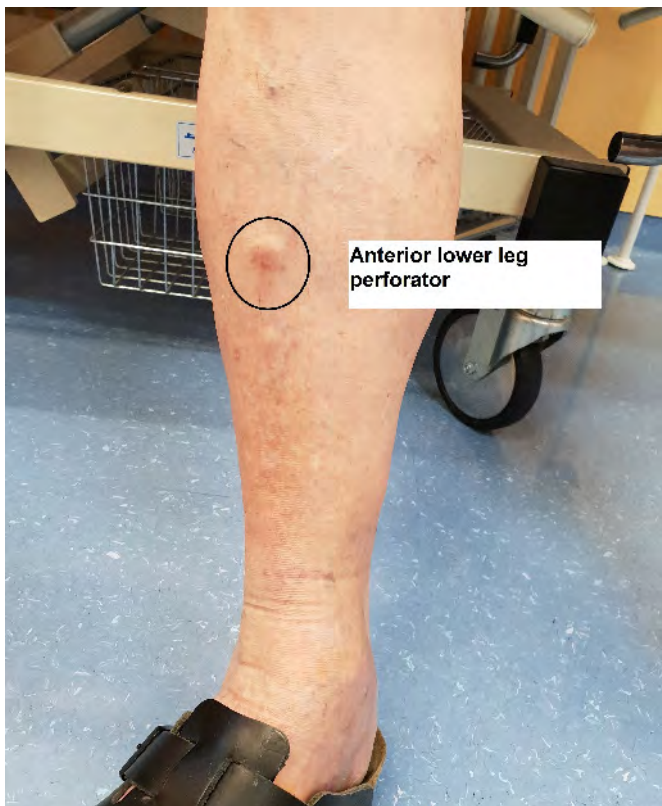


Fig. 4 Paratibial perforating vein after traumatic injury to the tibia with typical blow-out phenomenon

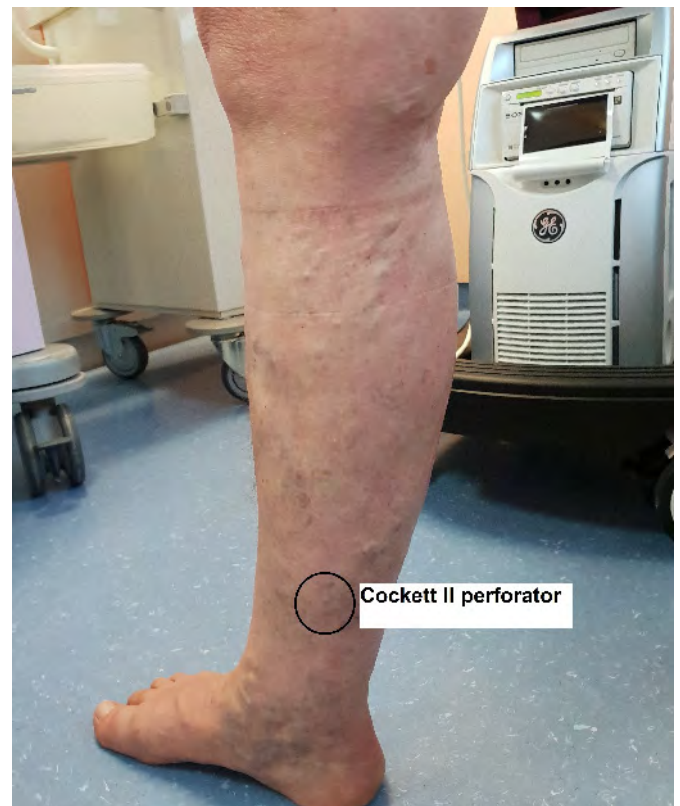

Fig. 5 Recurrent varicosis after high ligation and stripping of the right GSV, with Cockett II perforator incompetence

Clinical diagnosis

Perforator vein incompetence usually leads to pathologically dilated fascial gaps that are often painful on palpation. Incompetent perforators are generally detectable even on simple inspection of the erect patient by the blow-out phenomenon.

Venous function tests (Perthes, Mahorner-Ochsner, Trendelenburg and Pratt tests) can be used for further clinical diagnosis

Colour-coded duplex ultrasonography

The simplest way to demonstrate perforator incompetence is by duplex ultrasonography. The dilated perforator veins are readily visible in the B-mode image (► Fig. 7).

Only perforators that are pathologically dilated are generally detectable by ultrasound. In most of them, the blood flows from the surface into the deep tissues, as drainage for the reflux in the truncal vein or in the tributaries to the deep leg veins. With retrograde flow, a perforator vein is the source of reflux for a varicose vein (4).

Perforators can also be readily visualised in colour-coded duplex ultrasonography. The physiological flow of blood in a perforator is directed from the surface into the deep tissues. Blood flow in a perforator can be shown under the Valsalva provocation manoeuvre or on manual compression of the calf. This increases pressure in the deep veins and the blood is directed proximally and into the perforating veins. If, due to reflux or volume overload, a perforator is dilated, an outward-directed flow is present during muscular systole (4) (► Figs. 8 and 9).

The flow after decompression is relevant for diagnosis. If flow towards the surface is present during diastole, then the perforator is incompetent.

The provocation tests should be carried out using Valsalva's pressing manoeuvre, by movement of the toes (Wunstorf manoeuvre) or by manual calf compression. A tourniquet applied proximal to the perforator can lead to false pathological results in the manoeuvre, because the incompetent

Tab. 1 Topographical nomenclature of perforating veins

Old nomenclature	New topographical nomenclature
Cockett perforators (I, II, III)	Posterior tibial perforators (upper, middle and lower)
Bassi's perforator	Para-Achilles perforating vein
Shermann's perforator	Paratibial perforator
May's perforator (mid-calf perforator)	Intergemellar (soleal) perforators
Boyd's perforator	Proximal paratibial perforator
Hunter's perforator	Inguinal perforators
Dodd's perforator	Perforator veins of the femoral canal
Hach's perforator	Posterolateral perforator

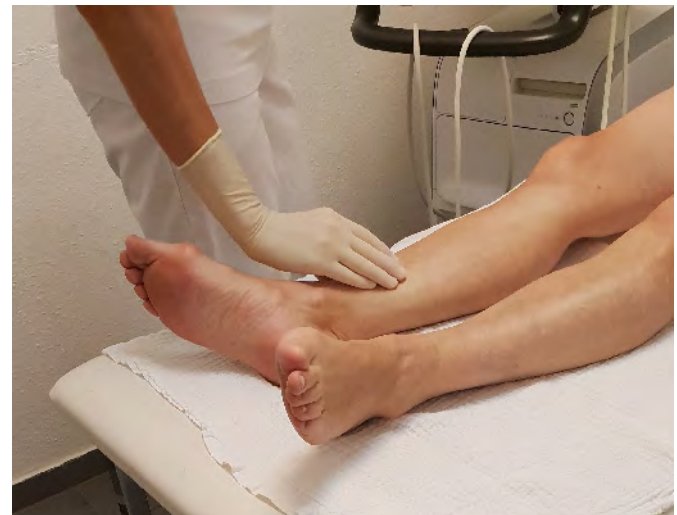

Fig. 6 The incompetent perforators are detected on palpation by enlarged fascial gaps

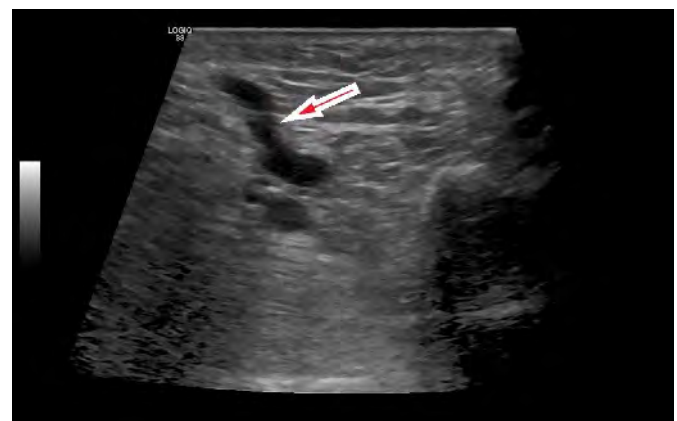


Fig. 7 B-image of a dilated perforator

vein is closed proximally by the tourniquet and the recirculation in diastole, that is otherwise present, is prevented. After decompression, blood flow from the deep vein drains into the distal incompetent superficial segment via the dilated perforator. Thus a vein that, under physiological conditions without a tourniquet, serves re-

circulation as an incompetence point. The exceptions are the secondary varices after trauma to the calf. Single refluxing muscle veins are more often present after trauma. These then fill side branch varices and form their proximal point of incompetence. (4)

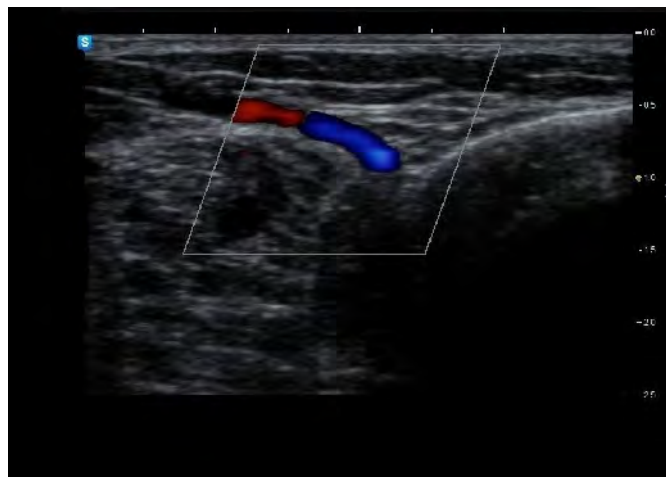

Fig. 8
Pretibial perforating vein with no pathological reflux

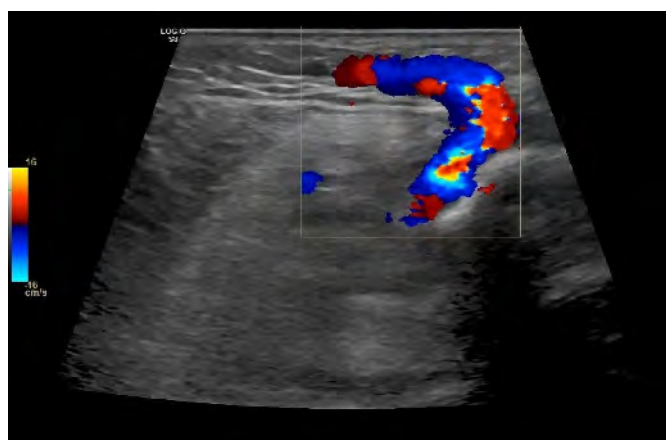


Fig. 9
Incompetent perforating vein, flow after decompression is directed to the surface

The incompetent muscle veins are frequently the origin of subcutaneous reticular varices. They are generally post-traumatic varices.

It is very rare that a dilated perforating vein also fills an already refluxing vein, but this can occur with a secondary varicose vein. If the vein above the perforator is already refluxing, the flow patterns in the saphenous vein and perforating vein must be accurately compared before the latter is designated as an incompetent perforator needing treatment. Its flow pattern must be predominantly directed outwards and the flow patterns of the distal vein lead to a larger reflux volume than in its proximal portion. This investigation is only possible in the PW mode.

The perforating veins can serve as drainage. Most often they are veins in the calf, especially the Cockett group and the paratibial perforators (► Fig. 10).

Phlebography

Phlebography with contrast agent – previously often used in the diagnosis of perforator incompetence – has become less important in view of the possibilities of duplex ultrasound. The indication for phlebographic diagnosis is to be made in the case of a questionable result following duplex ultrasound examination. It can be worthwhile in rare cases with legs that have undergone several operations, after recent thrombosis or in extreme obesity (► Figs. 11 and 12).

Venous leg ulcer

There is a correlation between the number of incompetent perforators and the severity of CVI and/or the development of a venous leg ulcer. Perforator incompetence is rarely the sole cause of the venous ulcer, but the

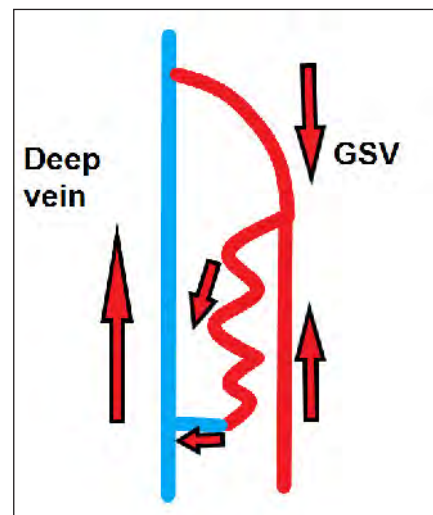


Fig. 10 Incompetence of the great saphenous vein with conjugating side branch varicosis, drainage via the perforating vein (arrows show direction of flow).

Cockett perforators are more commonly involved. Phlebodynamometric studies indicate that the risk of developing a venous ulcer increases with the severity of haemodynamic decompensation. Permanent healing of an ulcer is only likely with a far-reaching normalisation of the ambulatory venous hypertension. If incompetence is confined to the superficial venous system and accompanying perforator incompetence, then eradication of the epifascial reflux components is usually sufficient. In contrast, if there is irreversible damage of the deep venous system at the same time, the venous hypertension will persist after treatment of the epifascial incompetence, even after additional eradication of incompetent perforators (5, 6).

A few studies show that after abolition of epifascial reflux (high ligation and stripping), the number of preoperative incompetent perforating veins decreases (7, 8) (► Figs. 13 and 14).

Treatment methods

Eradication of the incompetent perforating veins should be considered if the incompetence is of clinical and/or haemodynamic relevance (9–11). The benefits of a routine ablation of perforators in uncomplicated, purely epifascial varicosities are not proven

(11–13). Provided the skin condition is healthy, surgical ligation of the perforating veins is currently the technique with the fewest complications (11) (► Figs. 15 and 16).

Exposure of the perforating vein according to Linton (16), without consideration of its pathophysiological importance and the skin condition, is no longer recommended (11).

Cases of endovenous treatment of perforator incompetence have been described in the literature (17, 18). However, there is still no treatment recommendation for endovenous laser or radiofrequency treatment of perforators (11).

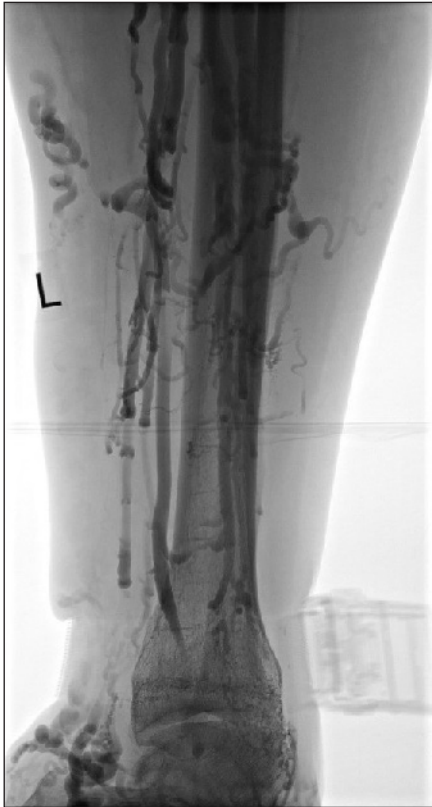

Fig. 11 Phlebological demonstration of an incompetent Cockett III perforator with existing recurrent varicosis, severe secondary lymphoedema and venous ulcerations after high ligation and stripping

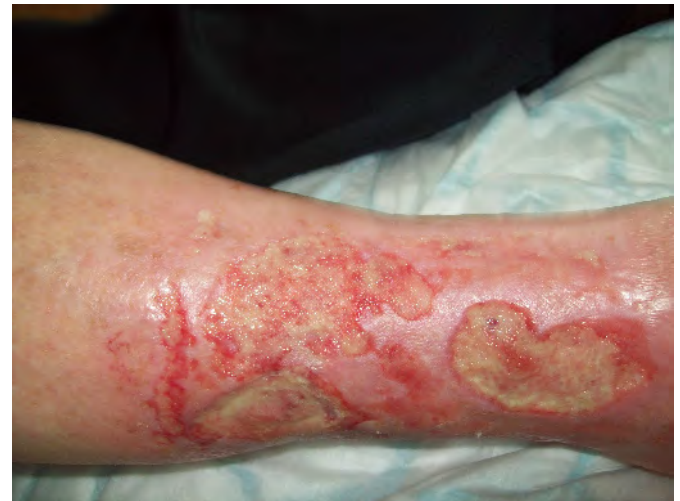

Fig. 13 Chronic venous ulcers in Cockett III perforator incompetence

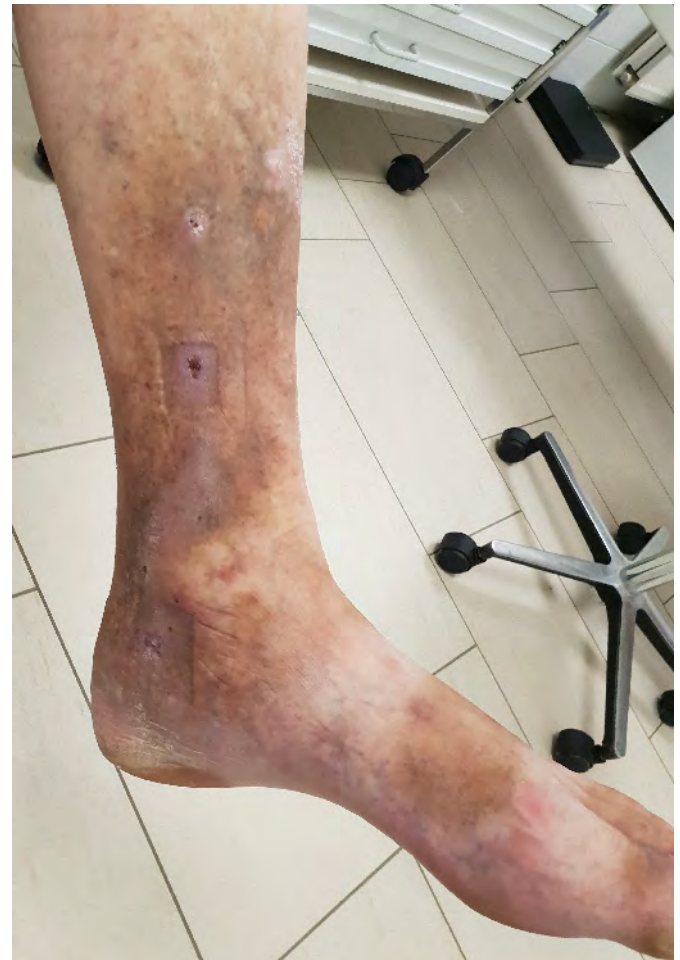

Fig. 14 Healing venous leg ulcer after sclerotherapy with perforator incompetence

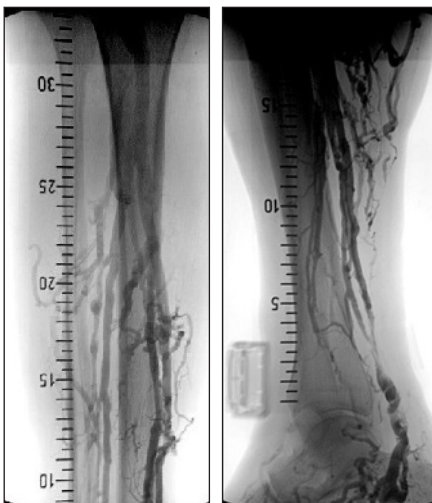

Fig. 12 Truncal incompetence of GSV Hach II with incompetent-appearing Dodd perforators (a and b)

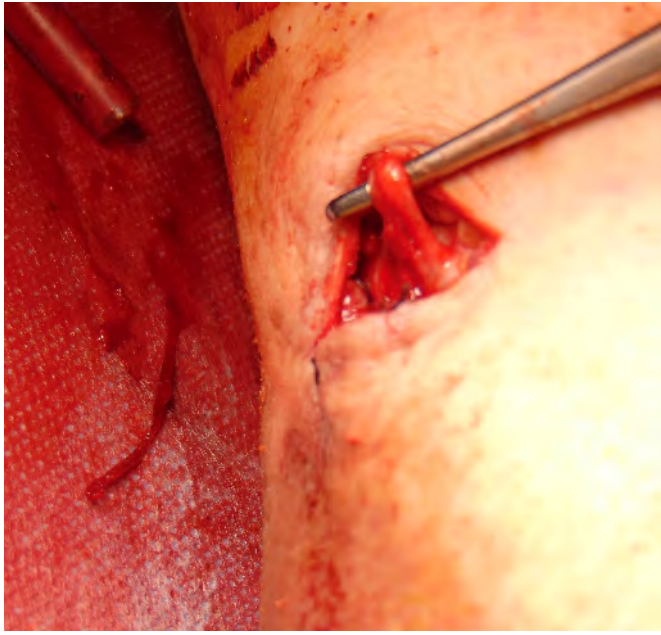


Fig. 15
Surgical exposure and ligation of a perforating vein

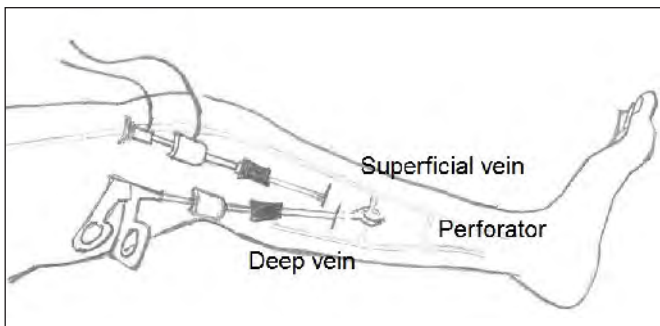


Fig. 16
Endoscopic perforator ligation (schematic representation)

Duplex-guided foam sclerotherapy of perforators has shown good results in studies and should be preferred as a possible treatment if the skin condition is poor (19, 20).

Conclusion

Perforating veins are a feature of the lower extremity and present a challenge in the diagnosis and treatment of chronic venous insufficiency. The pathophysiological significance of a perforating vein can be investigated by careful duplex diagnosis. The perforating veins can form a point of incompetence, but more often serve as drainage for venous recirculation.

Conflict of interest

The authors declare that there are no conflicts of interest.

Ethical guidelines

No studies in humans or animals were conducted for the manuscript.

References

- Gloviczki P. Handbook of venous disorders. 3rd ed. London: Edward Arnold 2009.
- Van Limborgh J, Hage E. Anatomical features of those perforating veins of the leg which frequently or infrequently become incompetent. In May R, Partsch H, Staubesand J. Perforating veins. München: Urban&Schwarzenberg 1981, 49–59.
- Caggiati A, Bergan J, Gloviczki P, Jantet G, Wendell-Smith C, Partsch H. Nomenclature of the veins of the lower limbs: an international interdisciplinary consensus statement. *J Vasc Surg* 2002; 36: 416–422.
- Mendoza E. Duplexsonographie der oberflächlichen Beinvenen. 2nd ed. Springer-Verlag GmbH 2013.
- Klein-Weigel P, Biedermann H, Fraedrich G. The role of perforating vein dissection in the treatment of venous ulceration – myth and evidence. *Vasa* 2002.
- Recek C, Karisch E, Gruber J. Veränderungen der Perforansvenen und tiefen Unterschenkelvenen nach Beseitigung des Saphena-Refluxes. *Phlebologie* 2000; 29(02): 37–40.
- Blomgren L, Johansson G, Dahlberg-Akerman A, Thermanius P, Bergqvist D. Changes in superficial and perforating vein reflux after varicose vein surgery. *J Vasc Surg* 2005; 42(2): 315–320.
- Gohel M, Barwell J, Earnshaw J, Heather B, Mitchell D, Whyman M, et al. Randomized clinical trial of compression plus surgery versus compression alone in chronic venous ulceration (ESCHAR study) – haemodynamic and anatomical changes. *Br J Surg* 2005; 92(3): 291–297.
- Fitridge R, Dunlop C, Raptis S, Thompson M, Leppard P, Quigley F. A prospective randomized trial evaluating the haemodynamic role of incompetent calf perforating veins. *Aust N Z J Surg* 1999; 69: 214–216.
- Hach W, Hach-Wunderle V, Nestle W. Die Insuffizienz der Cockett-Vv.-perforantes und die operative Behandlung. *Gefäßchirurgie* 2000; 5: 130–137.
- Kluess H, Noppeney T, Breu F, Ehresmann U, Gerlach H, Hermanns H, et al. Leitlinie zur Diagnostik und Therapie der Krampfadererkrankung. *Phlebologie* 2004.
- Bassi G. Klinische Bedeutung insuffizienter Vv. Perforantes. In May R, Partsch H, Staubesand J. *Venae perforantes*. München: Urban&Schwarzenberg 1981: 110–113.
- Bjorndal R. Die Zirkulation in insuffizienten Vv. Perforantes der Wade bei venösen Störungen. In May R, Partsch H, Staubesand J. *Venae perforantes*. München: Urban&Schwarzenberg 1981: 71–88.
- Hauer G. Operationstechnik der endoskopischen subfascialen Discision der Perforansvenen. *Chirurg* 1987; 58: 172–175.
- Hauer G, Nasralla F, Wisser I, Schneidemann G. Zur endoskopischen Perforansdissektion und Fasziotomie. *Gefäßchirurgie* 1997; 2: 222–226.
- Linton R. The post-thrombotic ulceration of the lower extremity: its etiology and surgical treatment. *Ann Surg* 1953; 138: 415–432.
- Perälä J, Rautio T, Biancorie F, Ohtonen P, Wiik H, Heikkinen T et al. Radiofrequency endovenous obliteration versus stripping of the long saphenous vein in the management of primary varicose veins; 3-year outcome of a randomized study. *Ann Vasc Surg* 2005; 19: 1–4.
- Proebstle T, Herdemann S. Early results and feasibility of incompetent perforator vein ablation by endovenous laser treatment. *Dermatol Surg* 2007; 33: 162–168.
- Kishore R, Sankar T, Anandi A, Nedunchezian S. A Prospective Study in Comparison of Ambulatory Phlebectomy and Duplex Guided Foam Sclerotherapy in the Management of Varicosities with Isolated Perforator Incompetence. *Indian J Surg* 2016; 78(5): 356–363.
- Dillavou E, Harlander-Locke M, Labropoulos N, Elias S, Ozsvath K. Current state of the treatment of perforating veins. *J Vasc Surg Venous Lymphat Disord* 2016; 4(1): 131–135.