Appearance of an inverted appendix on virtual colonoscopy

UCTN

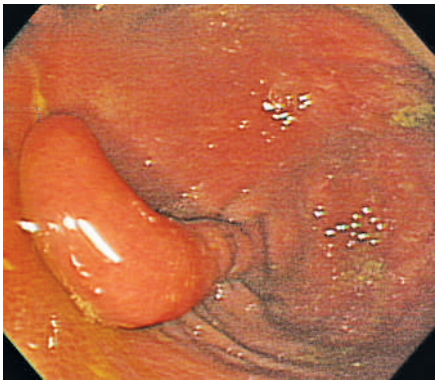

Figure **1** A 55-year-old woman with systemic lupus erythematosus, who had been followed up regularly for 7 years, visited our hospital complaining of chronic abdominal fullness, constipation, and stringy stools. She had a history of a total hysterectomy for uterine prolapse at the age of 38. At colonoscopy we found a 3-cm-long tubular structure, with normal-appearing mucosa, in the cecum; histopathological examination showed colonic mucosa with mild inflammation. A diagnosis of inverted appendix was made.

Figure **2** Virtual colonoscopy performed immediately after colonoscopy revealed a three-dimensional tubular structure, similar to that seen on colonoscopy. Inverted appendix should be considered in the differential diagnosis of cecal polyps.

A.-L. Chou[1], C.-W. Lin[2], K.-C. Tseng[1]

[1] Department of Internal Medicine, Buddhist Dalin Tzu Chi General Hospital, Chiayi, Taiwan

[2] Department of Radiology, Buddhist Dalin Tzu Chi General Hospital, Chiayi, Taiwan

Endoscopy_UCTN_Code_CCL_1AD_2AC
Endoscopy_UCTN_Code_CCL_1AD_2AJ

Corresponding Author

K.-C. Tseng, M.D.

Department of Internal Medicine
Buddhist Dalin Tzu Chi General Hospital
2 Min Sheng Road
Dalin
Chiayi
Taiwan
Fax: +886-5-2648006
E-mail: dennis0.tseng@msa.hinet.net

This document was downloaded for personal use only. Unauthorized distribution is strictly prohibited.

DOI: 10.1055/s-2006-925378