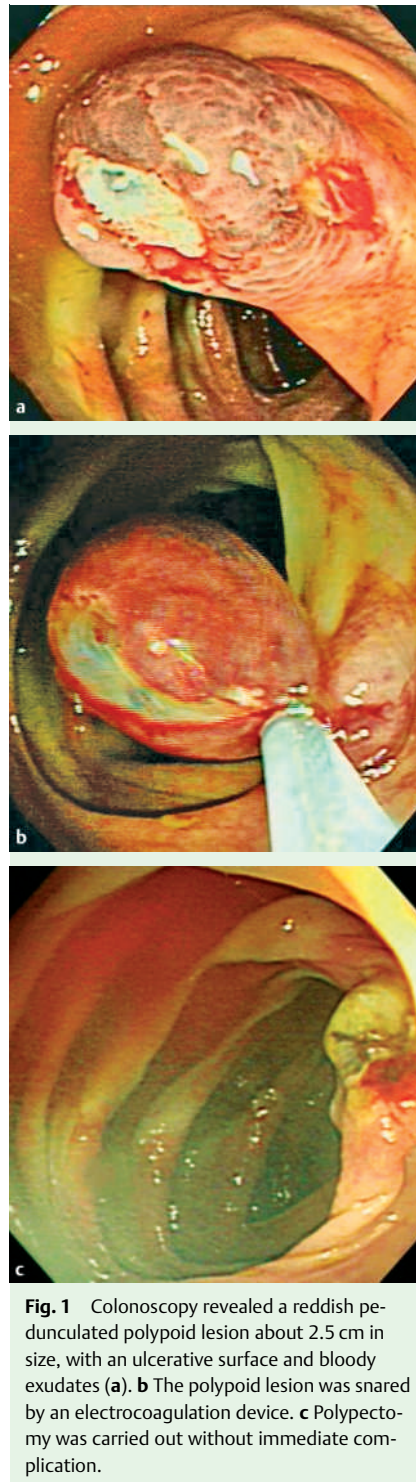


## Successful endoscopic polypectomy for colonic vascular ectasia presenting as pedunculated polypoid lesion

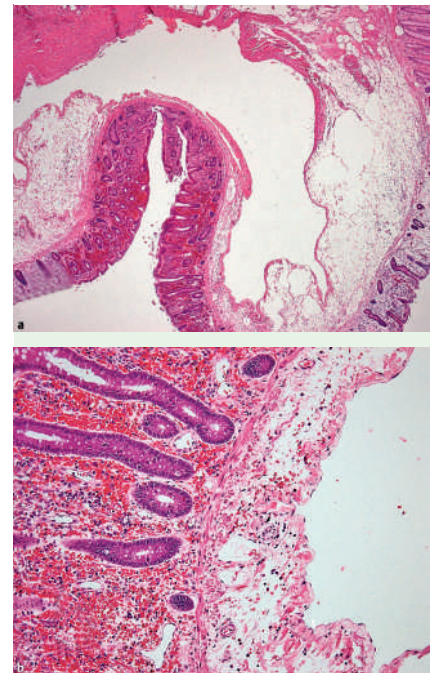
Colonic vascular ectasia is a potential and frequent cause of lower intestinal bleeding in the elderly. Recent advances in colonoscopy have discovered colonic vascular ectasia with increasing frequency. Colonic vascular ectasia often presents as multiple reddish, slightly elevated, mucosal lesions. It may be treated at colonoscopy with laser photocoagulation, heat probe, electrocoagulation, and argon plasma coagulation [1–4]. We present a case of an unusual pedunculated polypoid colonic ectasia that was successfully treated with endoscopic polypectomy.

A healthy 69-year-old man underwent colonoscopy because of recent anal discomfort and frequent abdominal fullness. Laboratory tests did not reveal anemia or positive fecal blood test. Colonoscopy revealed a soft, reddish pedunculated polypoid lesion, about 2.5 cm in diameter, with superficial ulceration and some bloody exudates at the ascending colon. Endoscopic polypectomy for suspected malignancy was carried out without complication (▶ Fig. 1). Histopathologic evaluation of the resection specimen showed edematous submucosa with an obvious dilated vein lined by endothelial cells. Some dilated capillaries were also found in the mucosa (▶ Fig. 2). Colonic vascular ectasia was diagnosed. At 1-year follow-up, the patient was uneventful. The typical endoscopic appearance of colonic vascular ectasia was often reported to be a slightly elevated reddish mucosal lesion. Pedunculated polypoid morphology of colonic vascular ectasia is extremely rare. This case suggests that colonic vascular ectasia could present as a single, asymptomatic, pedunculated lesion with an ulcerative surface. Furthermore, the lesion can be safely removed by endoscopic polypectomy with electrocoagulation snare.

Endoscopy\_UCTN\_Code\_CCL\_1AD\_2AC



**Fig. 1** Colonoscopy revealed a reddish pedunculated polypoid lesion about 2.5 cm in size, with an ulcerative surface and bloody exudates (a). b The polypoid lesion was snared by an electrocoagulation device. c Polypectomy was carried out without immediate complication.



**Fig. 2** a Histopathologic finding of the resection specimen showed an obvious dilated vein lined by endothelial cells in the submucosal layer (hematoxylin and eosin [H & E] stain,  $\times 20$ ). b Dilated capillaries were also noted in the mucosal layer (H & E stain,  $\times 110$ ).

I. T. Lin<sup>1</sup>, W. H. Chang<sup>1,4</sup>, S. C. Shih<sup>1,4</sup>,  
S. C. Lin<sup>1</sup>, Y. J. Chen<sup>3</sup>, H. Y. Wang<sup>1</sup>,  
C. H. Chu<sup>1,4</sup>, T. E. Wang<sup>1,4</sup>, T. C. Liou<sup>1,4</sup>,  
L. R. Shyung<sup>1</sup>, M. J. Bair<sup>2</sup>

<sup>1</sup> Division of Gastroenterology,  
Department of Internal Medicine,  
Mackay Memorial Hospital, Taipei,  
Taiwan

<sup>2</sup> Division of Gastroenterology,  
Department of Internal Medicine,  
Taitung branch of Mackay Memorial  
Hospital, Taitung, Taiwan

<sup>3</sup> Department of Pathology, Mackay  
Memorial Hospital, Taipei, Taiwan

<sup>4</sup> Mackay Medicine, Nursing and  
Management College, Taipei, Taiwan

## References

- 1 Tada Y, Okamura S, Okita Y et al. Vascular ectasia of the colon treated by argon plasma coagulation: report of a case. *Dig Endosc* 2001; 13: 37–40
- 2 Kakushima N, Fujishiro M, Yahagi N et al. An unusual case of polypoid angiodysplasia. *Endoscopy* 2004; 36: 379
- 3 Fu KI, Fujimori T. Bleeding angiodysplasia in the duodenum. *N Engl J Med* 2006; 354: 283
- 4 da Silva LE, Borros MS, Tafner E et al. Endoscopy treatment of colon vascular ectasia during bleeding with injection of adrenaline solution at 1:10000 and monopolar electrocoagulation: an alternative approach. *Arq Gastroenterol* 1995; 32: 31–34

## Bibliography

**DOI** 10.1055/s-2007-966407  
*Endoscopy* 2007; 39: 253–254  
© Georg Thieme Verlag KG Stuttgart · New York ·  
ISSN 0013-726X

## Corresponding author

### **M. J. Bair, MD**

Division of Gastroenterology  
Department of Internal Medicine  
Taitung branch of Mackay Memorial Hospital  
1 Lane 303  
Changsha Street  
Taitung  
Taiwan  
Fax: +886-89-321240  
a5963@ttms.mmh.org.tw