Endoscopic ultrasound-guided pancreaticogastrostomy reconstruction

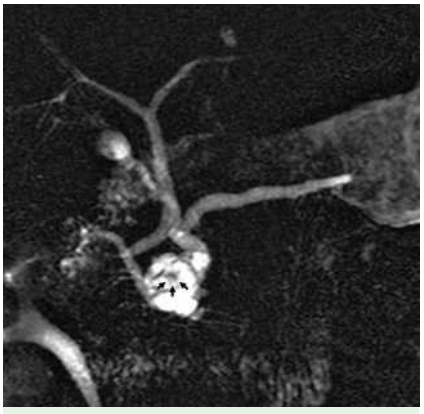

Figure 1 Magnetic resonance cholangiopancreatographic view showing the dilated branch of the pancreatic duct and a mural nodule in the dilated duct (arrow).

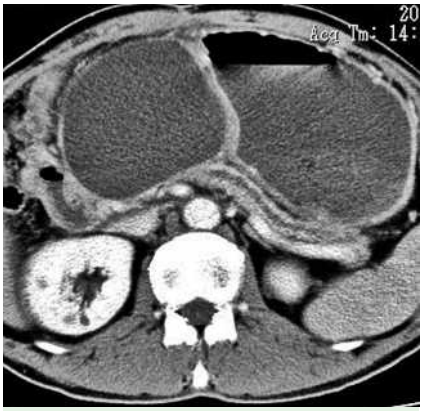

Figure 2 Computed tomographic view showing a pancreatic pseudocyst that developed 3 months after the surgical resection and pancreaticogastrostomy.

Figure 3 Computed tomographic view, showing the dilated main pancreatic duct 6 months after drainage of the pancreatic pseudocyst.

Figure 4 Fluoroscopic image showing a guide wire in the dilated duct, complete obstruction of proximal duct, outflow of the contrast through the cystogastrostomy stent, and placement of a guide wire into the distal pancreatic duct. The arrows show the previous drainage stent of the pancreatic pseudocyst.

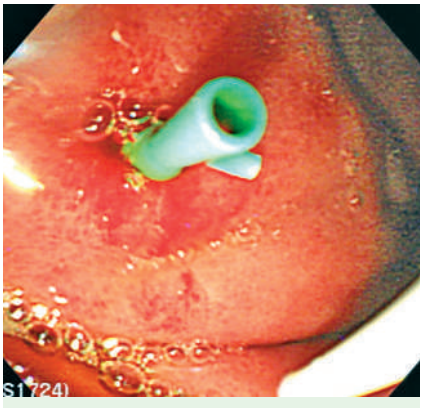

Figure 5 Endoscopic view of the stent inserted into the pancreatic duct.

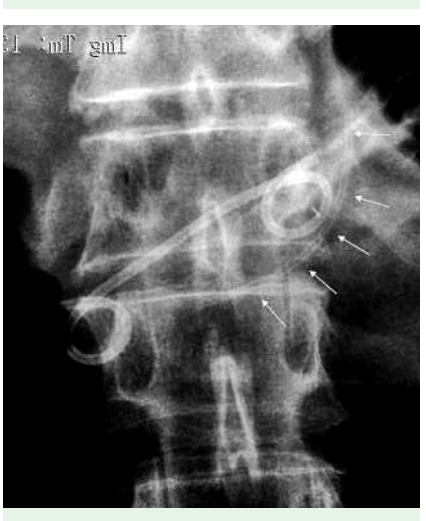

Figure 6 Fluoroscopic image showing placement of the stent through the gastropancreatic fistula (arrows). The tip of the stent was positioned in the proximal duct.

Severe stenosis and obstruction of a pancreaticogastrostomy anastomosis sometimes occurs after surgical pancreatic resection and pancreaticogastrostomy, resulting in abdominal pain and aggravation of diabetes as a result of ductal hypertension [1]. Endoscopic ultrasound-(EUS-)guided pancreaticogastrostomy has been reported as a method for reducing ductal hypertension in patients with chronic pancreatitis. We report a patient who underwent EUS-guided reconstruction of a pancreaticogastrostomy with gastropancreatic stent placement, which rapidly improved his symptoms [2, 3].

A 65-year-old man who had a branch duct type of intrapapillary mucinous neoplasm (IPMN) (▶ **Figure 1**) underwent a duodenum-preserving pancreatic head resection and pancreaticogastrostomy anastomosis. Forty-five days later, he developed a pancreatic pseudocyst (▶ **Figure 2**), which was drained under EUS guidance. Although computed tomography 6 months later showed that the pseudocyst had disappeared, the scan showed dilatation of the main pancreatic duct (▶ **Figure 3**). Decompression of the pancreatic duct was required to relieve his abdominal pain and reduce his hyperglycemia. Because the main pancreatic duct could not be drained by endoscopic retrograde pancreatography, EUS-guided pancreaticogastrostomy reconstruction was performed. An echo endoscope (GF-UC240 P-AL5; Olympus, Tokyo, Japan) was introduced into the stomach, and a 19-gauge needle (Echo-Tip; Wilson-Cook, Winston-Salem, North Carolina, USA) was used to puncture the main pancreatic duct and create a gastropancreatic fistula. We initially attempted to pass a 0.035-inch guide wire (Microvasive Endoscopy, Boston Scientific Corporation, Natick, Massachusetts, USA) through the stenotic anastomosis, but the guide wire could not be passed through the anastomosis (▶ **Figure 4**). A 6-Fr (Soehendra Biliary Dilation Catheters, Wilson-Cook, Winston-Salem, North Carolina, USA) dilator was advanced over the guide wire to dilate the gastropancreatic fistula, and then a 5-Fr, 5-cm-long pancreatic stent (Geenen Pancreatic Stent Set, Wilson-Cook, Winston-Salem, North Carolina, USA) was advanced over the wire and through the gastropancreatic fistula. The stent was placed in the pancreatic duct with the tip positioned in the proximal duct (▶ **Figure 5**, ▶ **Figure 6**). The patient's abdominal pain was rapidly relieved and his hyperglycemia had improved 1 month later.

Endoscopy_UCTN_Code_TTT_1AS_2AD

H. Sakamoto[1], M. Kitano[1], T. Komaki[1], Y. Takeyama[2], M. Kudo[1]

[1] Department of Gastroenterology and Hepatology, Kinki University School of Medicine, Osaka, Japan

[2] Department of Surgery, Kinki University School of Medicine, Osaka, Japan

References

1 *Amano H, Takada T, Ammori BJ et al.* Pancreatic duct patency after pancreaticogastrostomy: long-term follow-up study. Hepatogastroenterology 1998; 45: 2382 – 2387

2 *Francois E, Kahalen M, Giovannini M et al.* EUS-guided pancreaticogastrostomy. Gastrointest Endosc 2002; 56: 128 – 133

3 *Gress F, Ikenberry S, Sherman S et al.* Endoscopic ultrasound-directed pancreatography. Gastrointest Endosc 1996; 44: 736 – 739

Bibliography

DOI 10.1055/s-2007-966150

Endoscopy 2007; 39: E70 – E71

ISSN 0013-726X

Corresponding author

M. Kitano, MD

Division of Gastroenterology and Hepatology
Department of Internal Medicine
Kinki University School of Medicine
377-2 Ohno-Higashi
Osaka-Sayama 589-8511
Japan
Fax: +81-72-367-2880
m-kitano@med.kindai.ac.jp