Depressed-type early adenocarcinoma of the terminal ileum

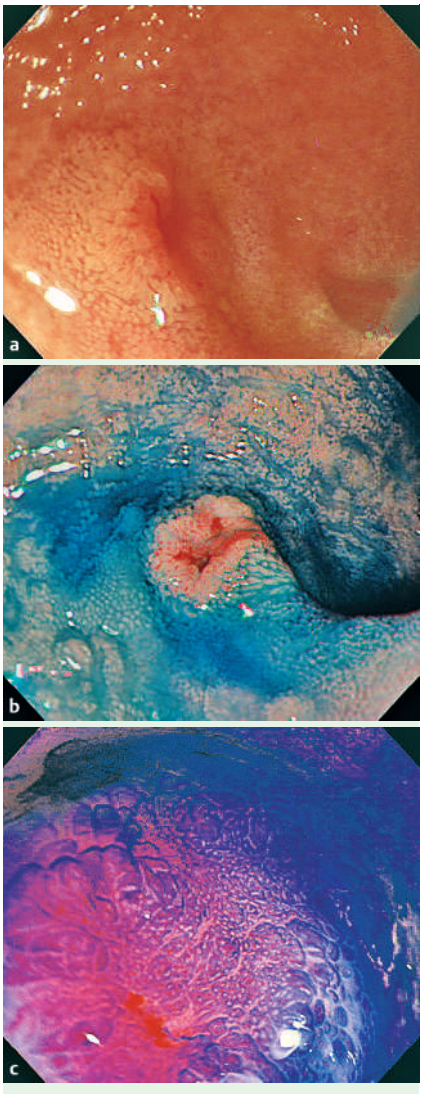

Fig. 1 **a** Conventional endoscopic view showed a shallow depressed lesion in the terminal ileum. **b** Chromoendoscopic view with indigo carmine dye showed a star-shaped demarcation line of the depressed lesion. **c** Magnifying endoscopic view with crystal violet staining showed regular arrangement of small round and tubular pit patterns.

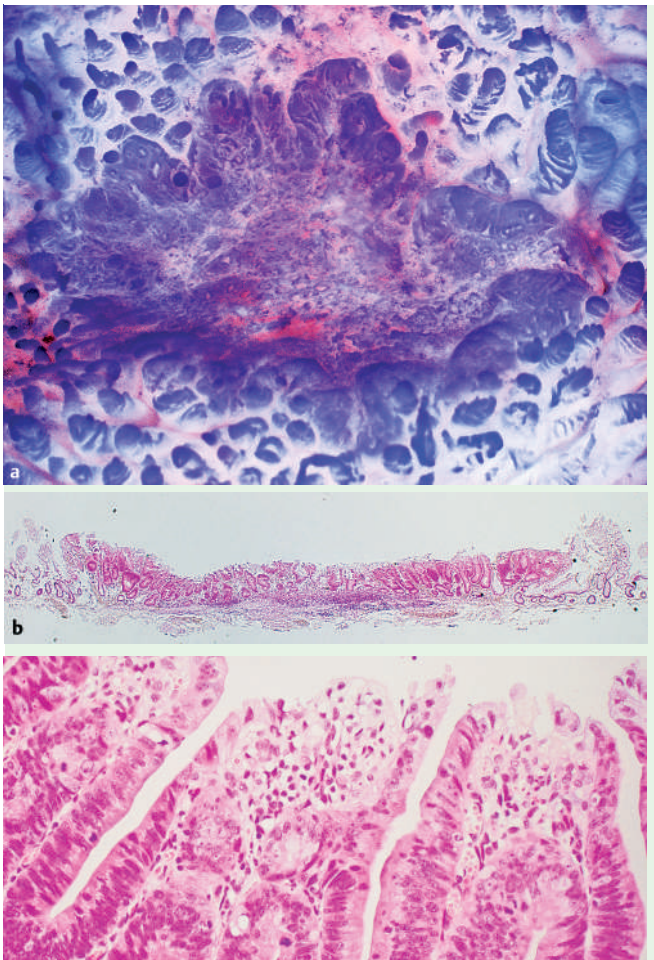

Fig. 2 **a** Stereomicroscopic view showed a star-shaped depressed lesion with marginal elevation. **b** Histopathologic cross section revealed an intramucosal depressed neoplasm with lamina propria invasion (H & E, original magnification × 10). **c** High-power view revealed well-differentiated adenocarcinoma (H&E, original magnification × 200).

Video 1

Video clip shows conventional and magnifying endoscopic features of depressed type adenocarcinoma of the terminal ileum, and procedure of endoscopic mucosal resection.

Depressed-type neoplasm of the jejunum and the ileum has not yet been recognized. To the best of our knowledge, this is the first case of depressed-type primary adenocarcinoma of the ileum.

A 62-year-old man underwent total colonoscopy. A small reddish depressed lesion with marginal elevation, 5 mm in diameter, was detected in the terminal ileum (▶ **Fig. 1 a**). A chromoendoscopic view with indigo carmine dye showed a star-shaped demarcation line of the depressed lesion (▶ **Fig. 1 b**). A magnifying endoscopic view with crystal violet staining showed small round and tubular pit patterns (▶ **Fig. 1 c**). With these findings, we diagnosed intramucosal neoplasm.

An endoscopic mucosal resection was performed, and the resected lesion measured 5 × 4 mm. Stereomicroscopic view showed a star-shaped, depressed lesion with marginal elevation (▶ **Fig. 2 a**). A histopathologic cross section revealed an intramucosal depressed neoplasm with lamina propria invasion (▶ **Fig. 2 b**). A high-power view revealed well-differentiated adenocarcinoma (▶ **Fig. 2 c**). Cancer-cell nuclei were positive in p53 im-

This document was downloaded for personal use only. Unauthorized distribution is strictly prohibited.

munohistochemical staining. A polymerase chain reaction-single strand conformation polymorphism (PCR-SSCP) study of p53 genes revealed some mutations of exon 6, 7, and 8. K-ras codon 12 mutations (PCR-restriction fragment length polymorphism [RFLP]) were not observed.

Morphological appearance was classified as type 0-IIc in the Paris endoscopic classification [1], and mimicked a depressed-type colorectal cancer advocated by Kudo [2]. It had been reported that K-ras mutations were absent in depressed-type colorectal cancers [3,4]. It was reported that rates of p53 positivity in depressed-type colorectal neoplastic lesions were higher in carcinomas and high-grade neoplasms than in low-grade neoplasms [5]. Therefore the characterizations of the genetic change, such as p53 and K-ras, were mimicking depressed-type colorectal cancer.

Acknowledgement

Our deep appreciation goes to Professor T. Fujimori, PhD, and S. Fujii, PhD, from the Department of Pathology of Dokkyo University, for their cooperation on pathological diagnosis.

Endoscopy_UCTN_Code_CCL_1AC_2AC

K. Hotta, A. Tomori, T. Oyama, Y. Miyata
Department of Gastroenterology, Saku Central Hospital, Nagano, Japan

References

1 The Paris endoscopic classification of superficial neoplastic lesions. Esophagus, stomach and colon: November 30 to December 1, 2002. Gastrointest Endosc 2003; 58: S3 – S43
2 *Kudo S.* Endoscopic mucosal resection of flat and depressed type of early colorectal cancer. Endoscopy 1993; 25: 455 – 461
3 *Saito K, Arai K, Mori M.* p53 overexpression and K-ras codon 12 mutations in submucosal invasive depressed-type colorectal cancer. Oncol Rep 2000; 7: 741 – 744
4 *Kaneko K, Kurahashi T, Makino R et al.* Pathological features and genetic alterations in colorectal carcinomas with characteristics of nonpolypoid growth. Br J Cancer 2004; 91: 312 – 318
5 *Hayakawa M, Shimokawa K, Kusugami K et al.* Clinicopathological features of superficial depressed-type colorectal neoplastic lesions. Am J Gastroenterol 1999; 94: 944 – 949

Bibliography
DOI 10.1055/s-2007-966145
Endoscopy 2007; 39: E231 – E232
© Georg Thieme Verlag KG Stuttgart · New York ·
ISSN 0013-726X

Corresponding author
K. Hotta, MD
Department of Gastroenterology
Saku Central Hospital
197 Usuda
Saku, Nagano 384-0301
Japan
Fax: +81-267-82-3025
kinichi1@janis.or.jp

This document was downloaded for personal use only. Unauthorized distribution is strictly prohibited.