

Dieulafoy's Lesion of the Duodenum; Successful Endoscopic Therapy

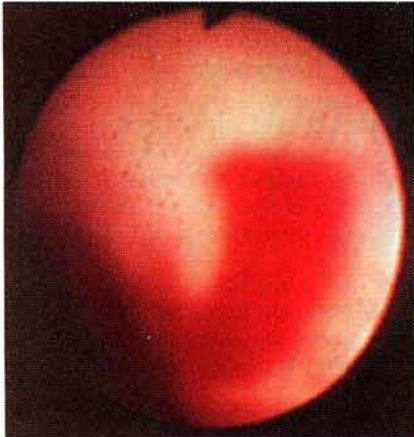


Figure 1: Active oozing of bright red blood from a vessel in the duodenal bulb. On washing there was no evidence of surrounding ulceration.

Dieulafoy's disease is probably an unrecognised rather than a rare cause of massive upper gastrointestinal bleeding (1). The lesion is most often found in the proximal stomach, has also been reported in the jejunum (2,3), and rarely in the duodenum (4,5).

A 55-year-old man with atrial fibrillation and valvular heart disease, well maintained on digoxin and warfarin, was admitted as an emergency because of melaena. There was no history of previous gastrointestinal haemorrhage, alcohol abuse or non-steroidal anti-inflammatory drug therapy. On admission the patient was not shocked. The Hb was 7.7 g/dl with a prothrombin ratio (INR) of 2.8. He was transfused 2 units of fresh frozen plasma and an upper endoscopy was performed. Endoscopy revealed active oozing of bright red blood from a vessel in the duodenal bulb (Figure 1). Initial haemostasis was achieved with injection of 1:100,000 adrenaline into and around the bleeding point; the lesion was subsequently treated by Nd: Yag laser photocoagulation. A total of 14

units of packed cells was transfused during his admission. Warfarin was restarted six days after endoscopic therapy and the patient did not rebleed over five months of follow-up. We initially treated our patient with injection therapy, as we believe that initial haemostasis is best achieved with adrenaline in non variceal bleeding. Laser photocoagulation was then given to achieve permanent haemostasis. The excellent result of endoscopic therapy in this case suggests that endoscopic intervention should be the first line of treatment, surgery being reserved for cases where endoscopic therapy fails.

C. P. Choudari, K. R. Palmer*

Gastrointestinal Unit, Western General Hospital
Edinburgh EH4 2XU
United Kingdom

References

1. *Veldhuyzen van Zanten SJ, Bartelsman JF, Schipper ME et al.*: Recurrent massive hematemesis from Dieulafoy vascular malformation. A review of 101 cases. *Gut* 1986; 27: 213–222.
2. *Boix J, Humbert P, Fernandez-Llamazares J et al.*: Dieulafoy's malformation. *Dig. Dis. Sci.* 1988; 33: 1496–1497.
3. *Matuchansky C, Babin P, Abadie JC et al.*: Jejunal bleeding from a solitary large submucosal artery. *Gastroenterology* 1978; 75: 110–113.
4. *McClave SA, Goldschmid S, Cunningham JT et al.*: Dieulafoy's cirroid aneurysm of the duodenum. *Dig. Dis. Sci.* 1988; 33: 801–805.
5. *Goldenberg SP, DeLuca VA, Marignani P*: Endoscopic treatment of Dieulafoy's lesion of the duodenum. *Am. J. Gastroenterol.* 1990; 85: 452–454.

Acknowledgements

The authors thank Mr I. B. Macleod, Royal Infirmary, Edinburgh for permission to report on this patient.