Endoscopic Therapy Using Monopolar and Bipolar Snare with a High-Frequency Current in Patients with a Pacemaker

Endoscopic therapy using a high-frequency current is considered to be unsuitable for patients with a pacemaker, as the pacemaker may be affected by the external current and magnetic field (1–4).

In this study, we obtained favorable results without complications using endoscopic therapy with a monopolar or bipolar snare in five patients with a pacemaker; these included one case of common bile duct stones, two cases of gastric polyps, and two cases of colon polyps.

Electromagnetic interference with the pacemaker was reduced to a minimum in the following ways: (1) The electric current was applied for 1–2 second periods at intervals of several seconds. (2) To use monopolar snare, the axis between the snare and the return electrode was adjusted so that it was perpendicular to the surface on which the pacemaker was located. (3) A bipolar snare was used to eliminate electromagnetic interference.

Case 1: A 58-year-old woman. An endoscopic image of case 1 is shown in Figure **1**. The calculi were removed by lithotriptor after electro-shock therapy by making a small incision.

Case 2: A 76-year-old man. Polypectomies of six colon polyps were performed with a monopolar and bipolar snare, in the fixed mode (DOO mode) and demand mode (DVI mode). Electrocardiogram recordings in case 2 during polypectomy are shown in Figure **2**. No failure of pacing or sensing, and no changes in rhythm were observed after endoscopic therapy in any case.

These procedures for endoscopic therapy should be useful, as there are increasing numbers of patients with a pacemaker in our aging societies.

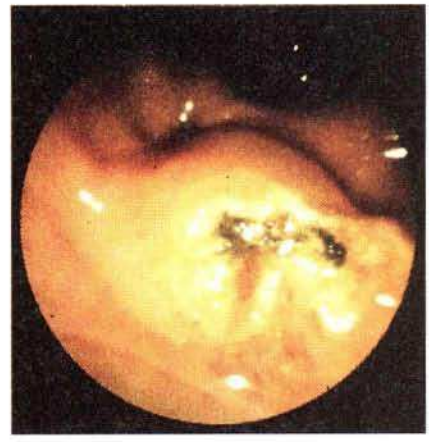

Figure 1 Endoscopic image following endoscopic sphincterectomy. As the distance between the duodenal papilla and the electrode was only about 15 cm, the place of attachment for the return electrode was shifted to the right lumbar region to reduce the effect of the high-frequency current on the pacemaker as much as possible.

References

1 *Toyoshima T:* Electromagnetic interference in cardiac pacemakers. Card. Pacemak. Electrophysiol. 1988; 4: 276–278.
2 *Lichter I, Borrie J, Miller WM:* Radiofrequency hazards with cardiac pacemakers. Br. Med. J. 1956; 1: 1513–1518.
3 *Omote T, Namiki A, Dohi S,* et al: A case of cardiac arrest caused by electrocautery during surgical pacemaker implanting. Jpn. J. Anesth. 1981; 10: 1126–1129.
4 *Awano K, Kiyama H, Koyama K,* et al.: Patients with a pacemaker in whom R on T was observed using an electric knife. Clin. Anesth. 1985; 2: 181–183.

S. Ito[1], H. Shibata[1], T. Okahisa[1], S. Okamura[1], S. Wada[1], M. Yano[1], T. Saijyo[1], H. Honda[1], H. Hayashi[1], I. Shimizu[1], K. Ii[2]
[1] Second Department of Internal Medicine and
[2] First Department of Pathology, School of Medicine
University of Tokushima, 2-50, Kuramoto-cho
Tokushima 770, Japan

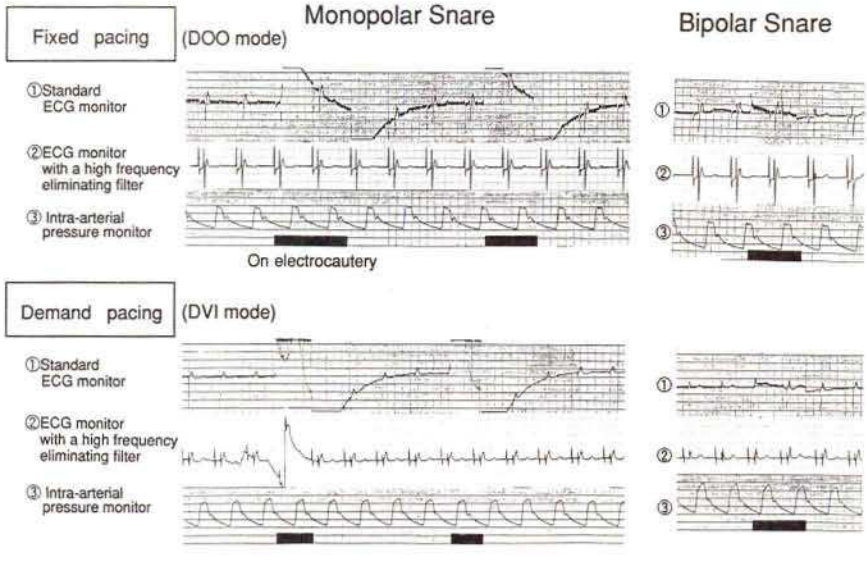

Figure 2: Electrocardiograms of case 2 during polypectomy. The monitor shows mixed noises, but no interference with the pacemaker can be recognized.

This document was downloaded for personal use only. Unauthorized distribution is strictly prohibited.