

Giant Polyposis Ulcerative Colitis Imitating Colonic Carcinoma: Two Cases

Two patients presented with inflammatory bowel disease, but endoscopic and radiologic examinations revealed giant polyposis which was difficult to differentiate from a tumor. A total colectomy was performed in each patient leading to cure of the disease.

Case 1. A 34-year-old patient, whose sister died from carcinoma of the colon, had been experiencing weight loss and recurrent rectal bleeding over the past three years. Colonoscopy showed a giant polypoid tumor with ulceration, multiple small polyps in the rectum and nothing unusual in the rest of the colon (Figure 1). A barium enema showed multiple large polyps in the rectosigmoid region which could not be differentiated from carcinoma. Repeated colonic biopsies showed inflammatory bowel disease with no evidence of malignancy. The results of a small bowel enema, were normal. The patient was treated with Sulfasalazopyrine and steroid enemas but continued to lose weight and was referred for total colectomy. After surgery he gained weight and continued to do very well "off treatment".

Case 2. A 34-year-old patient, diagnosed one year previously with ulcerative colitis who was receiving medical treatment, presented with diarrhea which contained mucous and blood. An examination showed anemia, high ESR and a low albumin level. On colonoscopy a polypoid mass was seen at the rectosigmoid junction almost obstructing the lumen. Multiple biopsies showed ulcerating polypoid mucosa and no evidence of malignancy. A CT scan of abdomen revealed a large heterogenous rounded mass compatible with a rectosigmoid neoplasm (Figure 2). The patient underwent a total colectomy with ileorectal anastomosis. Macroscopic examination of the bowel showed multiple giant polyposis involving all parts of the colon. A histologic examination showed inflammatory hyperplastic polyps secondary to ulcerative colitis with no evidence of malignancy. At an 8-month follow-up the patient was well, receiving no treatment.

The incidence of pseudopolyps in patients with ulcerative colitis is 10–22% (1,2) and a giant polyposis/pseudotumour is a well recognised complication (3). Two to four percent of patients with inflammatory bowel disease are at increased risk for developing adenocarcinoma (4). This is usually preceded by dysplasia, and occasionally the differentiation between adenocarcinoma and dysplasia in post inflammatory polyps is difficult (5). In our patients the colonic mass behaved clinically, endoscopically and radiologically as a tumour of the colon despite the negative superficial histologic results. We had no way to ensure that there was no occult malignancy within those lesions other than to resort to surgery. The post surgical specimens revealed giant polyposis pseudotumours. When the first patient continued to lose weight, he was worried as his sister died of carcinoma of the colon. The second patient had an aggressive disease, and it is well recognised that inflammatory polyps bear no relation to the duration of the disease.

References

1. *Jalan KN, Sircus W, Walker RJ, et al.*: Pseudopolyposis in ulcerative colitis. *Lancet* 1969; 2: 555–559.
2. *Teague RH, Read AE*: Polyposis in ulcerative colitis. *Gut* 1975; 16: 792–795.

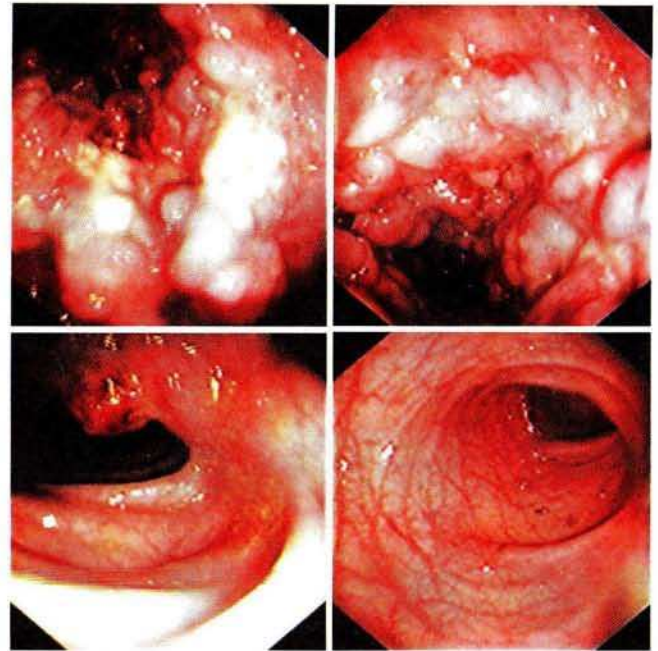


Figure 1: Colonoscopy showing a giant polypoid lesion encircling the rectum, another polypoid lesion and normal mucosa in between.

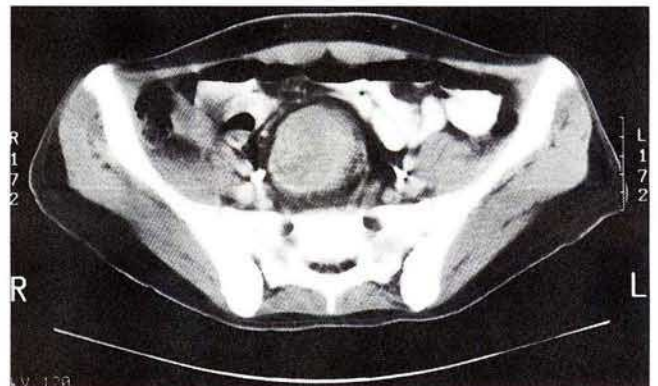


Figure 2: CT scan of pelvis showing a large heterogenous mass in the rectosigmoid region almost obstructing the bowel lumen.

3. *Buck JL, Dachman AH, Sobin LH*: Polypoid and pseudopolypoid manifestation of inflammatory bowel disease. *Radiographics* (United States) 1991; 11 (2): 293–304.
4. *Gyde SN, Prior D, Allen RN, et al.*: Colorectal cancer in ulcerative colitis. A cohort study of primary referral from 3 centres. *Gut* 1988; 29: 206–217.
5. *Kusunoki M, Nishigami T, Yanagi H, et al.*: Occult cancer in localized giant pseudopolyposis. *Amer J Gastroenterology* 1992; 87 (3): 379–381.

*M. A. Al Karawi*¹, *M. H. Gali*¹, *A. R. Mohamed*¹, *A. Haleem*²

¹ Department of Gastroenterology, and

² Department of Pathology, Armed Forces Hospital, Riyadh, Saudi Arabia

Corresponding Author

M. A. Al Karawi, M.D.
Armed Forces Hospital
PO Box 7897
Riyadh 11159
Saudi Arabi
Fax: 4790073