

Cystic Duct Remnant Duodenal Fistulization as a Cause of Misconceived Endoscopic Sphincterotomy and the Consequent Massive Bleeding

Biliary-enteric fistulas are rare, and only seven reports of cystic duct remnant (CDR) enteric fistulization have appeared in literature (1,2). If such a fistula is misinterpreted as the ampulla of Vater during the endoscopic sphincterotomy procedure causing massive bleeding (as in the presented case), this raises many questions. Should the endoscopist be aware of such an unpredictable situation? Should we expect more CDR complications after endoscopic cholecystectomies?

In our case an 80-year-old male patient with jaundice who had previously undergone a cholecystectomy (more than ten years ago) was urgently admitted to the surgical department following an endoscopic sphincterotomy due to common bile duct stones. During the endoscopic procedure, a "sphincterotomy" at the opening of the biliary enteric fistula was attempted. Massive bleeding, which could not be managed, occurred. The patient was immediately and successfully treated surgically (Figure 1). In the reported cases of CDR fistulization, two patients were over 60-years old, and our patient was 80-years old. It is believed that 90% of CDR enteric-fistulization cases are due to biliary calculi. The remaining cases of CDR enteric fistulas were due to secondary causes such as Chron's disease, neoplasm or peptic ulcer (2). The case presented here once again raises the question of the clinical importance of a CDR after cholecystectomy and in addition if and when CDR fistula should be expected or sought for? ERCP could show a significant CDR or common bile duct stones, and theoretically any fistula that may be present, but a fistula should be suspected. Considering the number of cholecystectomies performed worldwide and the number of reported complications, even the formation of cystic stump stones appears to be a relatively uncommon event (3). Although it has been suggested that an increasing frequency of laparoscopic cholecystectomies may result in more lengthy cystic ducts (1) and therefore there may be an increasing number of complications associated with a CDR, there is a substantial lack of evidence. However, the possibility of such a rare event should be kept in mind when treating elderly patients who underwent cholecystectomies several years ago and have persistent complaints with common bile duct stones.

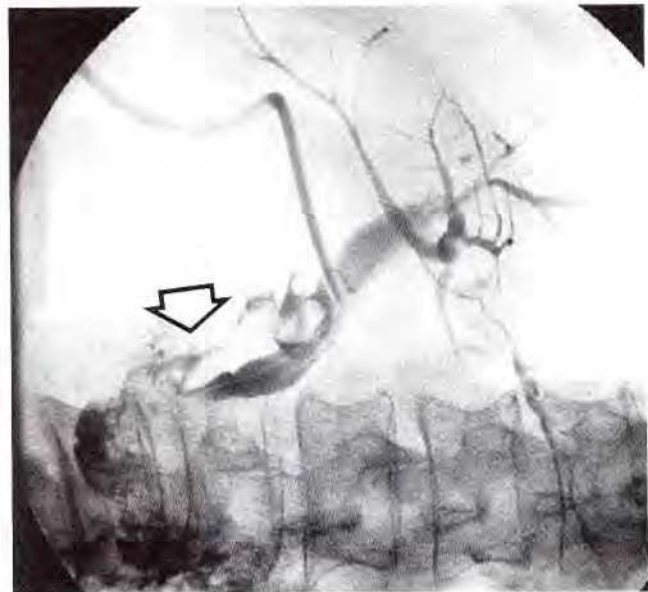


Figure 1: The arrow on the T tube radiogram performed eight days after operation denotes patent cystic duct remnant duodenal fistulization.

References

1. Woods MS, Farha GJ, Street DE: Cystic duct remnant fistulization to the gastrointestinal tract. *Surgery* 1992; 111: 101-104.
2. Rogy MA, Fugger R, Herbst F, Schulz F: Reoperation after cholecystectomy. The role of the cystic duct stump. *HPB Surg* 1991; 4: 129-135.
3. Bever KL, Marshall JB, Metzler MH, Elwing TJ: Endoscopic management of the retained cystic duct stones. *Am J Gastroent* 1991; 86: 232-234.

V Flis, M. Horvat

Departments of Vascular and Abdominal Surgery,
Teaching Hospital Maribor, Maribor, Slovenia

Corresponding Author

V. Flis, M.D.

Department of Vascular Surgery

Teaching Hospital Maribor

Ljubljanska 5

62000 Maribor

Slovenia

Fax: 3866235136