

## Endoscopic Treatment of Bleeding Fundic Varices with 50% Glucose Injection

Cardiac variceal bleeding in cirrhotic patients is a life-threatening event. We report here on a case of bleeding cardiac varices successfully treated by endoscopic injection using 50% glucose. A 70-year-old woman, with a history of hepatitis B-associated liver cirrhosis was admitted on 17 January 1994 with severe hematemesis. An emergency upper gastrointestinal endoscopy was carried out, showing no esophageal varices but a large blue tortuous cardiac varix with intermittent spurting (Figure 1). Ten milliliters of 50% glucose was injected into the cardiac varix with a 24-gauge needle. Near the bleeding point, a second injection using the same amount of 50% glucose was given as a paravariceal injection. The bleeding stopped. One week later, the endoscopy revealed cardiac varices (Figure 2) with a shallow ulcer in the injection area, and the varix appeared hardened when touched with the catheter tip. Another 20 ml of 50% glucose was injected around the varices, and no more bleeding was found after withdrawal of the needle. Six months after the treatment, endoscopy showed obliteration of the cardiac varix with residual scar formation (Figure 3) and some minor fundic vessels.

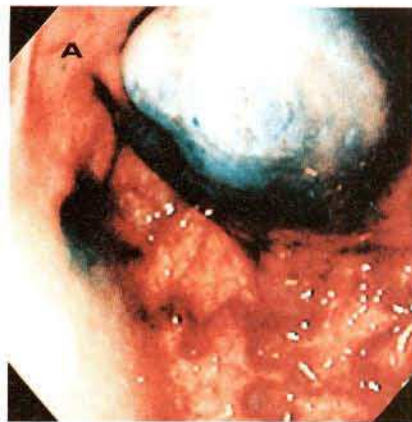
Gastric variceal sclerotherapy appears effective for acute variceal bleeding (1). According to Hosking's classification (2), the varices in our patient were type II gastric varices, and variceal ligation with gastric devascularization or a shunt operation have been advocated for these (2,3). We used the 50% glucose based on our experience in treating peptic ulcer hemorrhage from protruding vessels, with encouraging results (4). On reviewing the literature (1-3), it appears that 50% glucose has not previously been used in sclerotherapy for cardiac varices. According to Sadick (5), hypertonic saline (3% NaCl) for treating varicose and telangiectatic leg veins is a safe, widely available sclerosing agent that shows no evidence of causing any allergic hypersensitivity, and is associated with minimal ulceration. The fear that hypertonic saline might result in sodium retention in an advanced liver cirrhosis patient led us to use hypertonic glucose as a sclerosant. Large amounts (more than 10 ml) of 50% glucose introduced using the intravariceal and paravariceal injection method had both hemostatic and sclerosing effects in our patient. During seven months of follow-up, the patient did not experience recurrent cardiac variceal bleeding, or any other severe sclerotherapy complication. We feel that endoscopic sclerotherapy of cardiac variceal bleeding might also be carried out with hypertonic (50%) glucose, and this should be tested in further prospective trials.

*K.-Y. Chang, C.-S. Wu, P.-C. Chen*

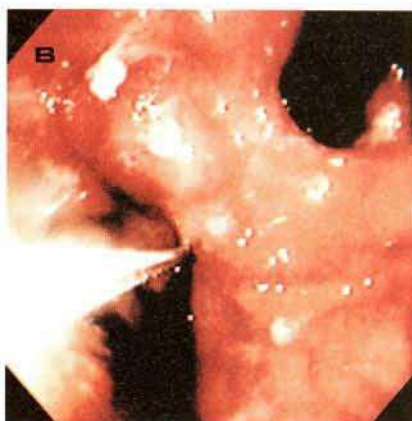Department of Hepatogastroenterology, Chang Gung Memorial Hospital, Lin Kou Medical Center, Taipei, Taiwan, Republic of China

### References

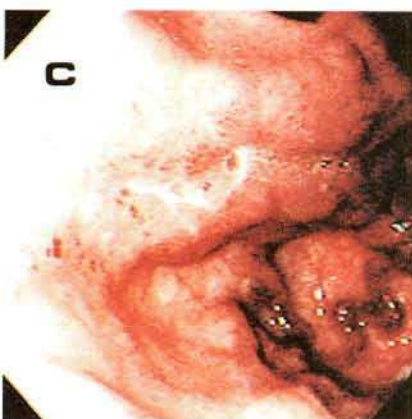
1. Trudeau W, Pindiville T: Endoscopic injection sclerosis in bleeding gastric varices. *Gastrointest Endosc* 1986; 32: 264-8.
2. Hosking SW, Johnson AG: Gastric varices: a proposed classification leading to management. *Br J Surg* 1988; 75: 195-196.
3. Sarin SK, Sachdev G, Nanda R, et al.: Endoscopic sclerotherapy in the treatment of gastric varices. *Br J Surg* 1988; 75: 747-50.



**Figure 1:** Large blue cardiac varix with intermittent spurting.



**Figure 2:** Cardiac varices with a shallow ulcer one week after 50% glucose sclerotherapy.



**Figure 3:** Only a residual cardiac ulcer scar with minor fundic vessels, six months later.

4. Lin HJ, Perng CL, Lee FY, et al.: Endoscopic injection for arrest of peptic ulcer hemorrhage: final results of a prospective, randomized comparative trial. *Gastrointest Endosc* 1993; 39: 15-9.
5. Sadick NS: Treatment of varicose and telangiectatic leg veins with hypertonic saline. *J Dermatol Surg Oncol* 1990; 16: 24-8.

### Corresponding Author

C.-S. Wu, M.D.  
 Department of Hepatogastroenterology  
 Chang Gung Memorial Hospital  
 199 Tung Hwa North Road  
 Taipei  
 Taiwan 10591  
 Republic of China  
 Fax: +886-3-3282824