

Superficial Esophageal Carcinoma Arising from the Diverticulum of the Esophagus

A 65-year-old male, who was entirely asymptomatic and in apparently good health, was referred to our hospital because of abnormal findings on a routine endoscopic examination. According to his past history, at the age of 35 years subtotal gastrectomy for gastric ulcer was carried out. A barium swallow demonstrated mild distortion of the esophageal lumen and a diverticulum on the left side of the upper esophagus (Figure 1). Endoscopically, a reddish and slightly depressed lesion was seen within the diverticulum. The lesion

was unstained by Lugol solution staining (Figure 2). We diagnosed a superficial carcinoma arising from the diverticulum of the esophagus. A total esophagectomy with wide lymph node dissection and posterior mediastinal colon interposition was performed. The pathologic specimen showed a moderately differentiated squamous cell carcinoma restricted to the submucosa and a true diverticulum containing all the layers of the esophagus. Chronic inflammation was seen in the lamina propria of the diverticulum; the closer the diverticu-

lum to the carcinoma, the more severe was the inflammation. The distance of superficial spread of depressed-type carcinoma was 2.5×2.0 cm. Metastasis was not recognized in the lymph nodes.

The association between esophageal intramural pseudodiverticulosis (1, 2) and carcinoma has been previously noted (3). Recently, only a few cases of carcinoma within a true diverticulum containing all the layers of the esophagus have been reported. An accumulation of food in the esophageal diverticulum causes secondary inflammation in the esophageal mucosa surrounding the diverticulum. Chronic inflammation, ulceration of the mucosa, and epithelial hyperplasia are important factors involved in the induction of the esophageal carcinoma. Carcinoma may develop in an area with severe chronic inflammation, repeated injury, or hyperplasia of the epithelium either within or close to the diverticulum.

H. Kimura¹, K. Konishi¹, Y. Tsukioka¹,
K. Muraoka¹, K. Yabushita¹, K. Maeda¹,
Y. Kuroda¹, M. Tsuji¹, A. Miwa²

¹ Dept. of Surgery

² Dept. of Pathology, Toyama Prefectural Central Hospital, Toyama, Japan

References

1. Gillissen A, Konturek J, Roos N, et al. Esophageal intramural pseudodiverticulosis: a characteristically unusual path to diagnosis. *Endoscopy* 1996; 28: 640.
2. Berter B, Dittler J-J, Wuttge-Hannig A, et al. Intramural pseudodiverticulosis of the esophagus: a case series. *Endoscopy* 1997; 29: 109–13.
3. Branko MP, Michael YMC, David WG, et al. Intramural pseudodiverticulosis of the esophagus: increased prevalence in patients with esophageal carcinoma. *AJR* 1995; 165: 1381–5.

Corresponding Author

H. Kimura, M.D.
Dept. of Surgery
Toyama Prefectural Central Hospital
202 078 Nishinagae
Toyama 930
Japan
Fax: + 81-764 220 667

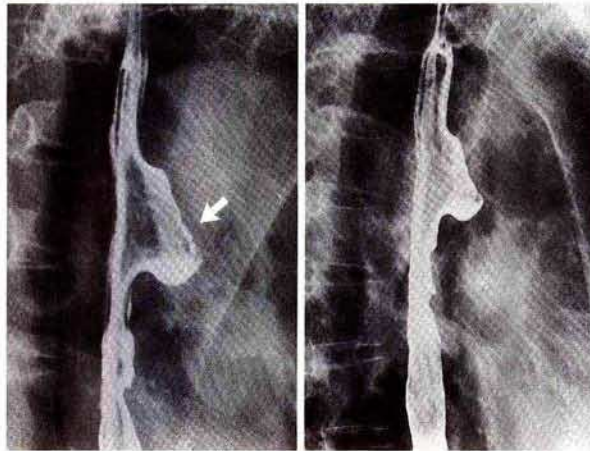


Figure 1: Esophagogram showing mild distortion of the esophageal lumen and a diverticulum on the left side of the upper esophagus. Minimal niche on the esophageal wall was detected within the diverticulum (arrow).

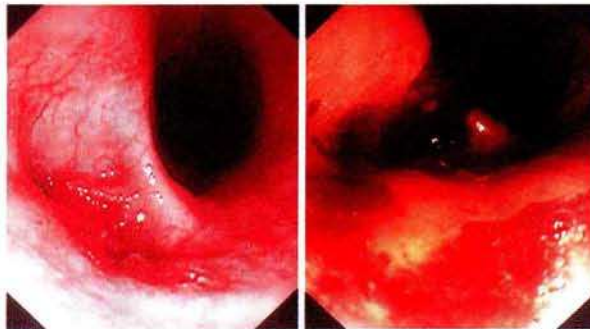


Figure 2: Endoscopic finding of a reddish and slightly depressed lesion was seen within the diverticulum (left). The lesion was unstained by Lugol solution staining (right).