

## Percutaneous Fixation of the Stomach to the Abdominal Wall in Patients with Percutaneous Gastrostomy

Percutaneous endoscopic gastrostomy (PEG) is recommended for intestinal feeding in patients with swallowing difficulties (1,2). One problem has been the tendency for tube extrusion from the stomach to the peritoneal cavity (3,4). The consequence may be severe peritonitis due to a leak from the stomach. We have used an Endo Close suturing device (Auto Suture, Denmark) to place two or three full thickness nonabsorbable sutures percutaneously through the abdominal and the gastric wall, to keep them in close contact in the postoperative period.

The patients were gastroscopied in the supine position under general anaesthesia by a standard forward-viewing gastroscopie. The stomach was distended and a PEG 24 gastrostomy tube (Wilson-Cook Medical Inc.) was inserted percutaneously in the epigastrium (Figure 1). The suture was tied over a small piece of plastic tube. Two or three sutures were placed as described and these sutures were left in place for at least four weeks. The technique has been used in two patients, with an uncomplicated postoperative course in both of them.

The technique for placement of the gastric tube using an endoscope was introduced by Gauderer et al. (5) and was used in our patients too. We have added a new simple procedure to keep the stomach and the abdominal wall in close contact. The procedure is simple, fast and does not require additional instruments except the disposable Endo Close suturing device. The described procedure is probably rarely needed, but can be a useful tool in specific cases.

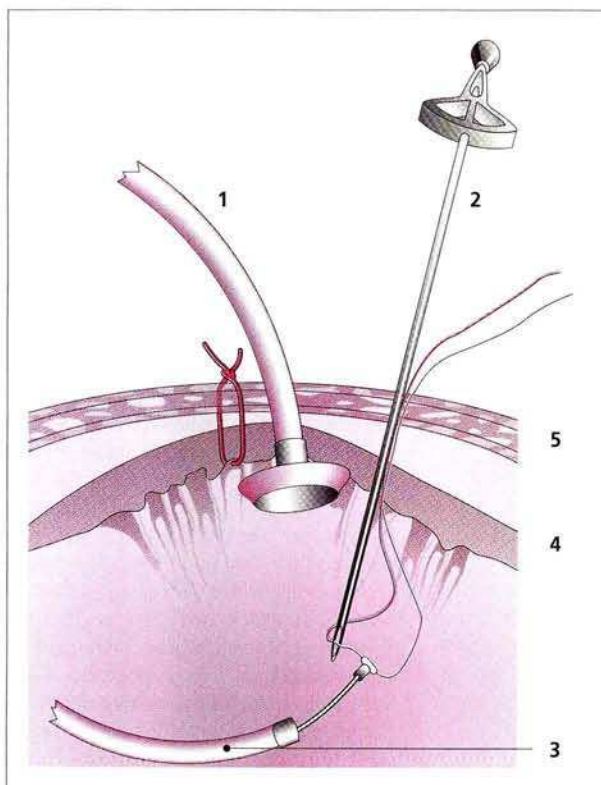
N. H. K. Jensen, M. Jønler, J. Kiil  
Dept. of Surgery, Viborg Hospital,  
Viborg, Denmark

### References

1. Zera RT, Nava HR, Fischer JI. Percutaneous endoscopic gastrostomy (PEG) in cancer patients. *Surg Endosc* 1993; 7: 304-7.
2. Mellinger JD, Ponsky JL. Percutaneous endoscopic gastrostomy: an overview for 1996. *Endoscopy* 1996; 28: 66-70.
3. Behrle KM, Dekovich AA, Ammon HV. Spontaneous tube extrusion following percutaneous endoscopic gastrostomy. *Gastrointest Endosc* 1989; 35: 56-8.
4. Ditesheim JA, Richards W, Sharp K. Fatal and disastrous complications following percutaneous endoscopic gastrostomy. *Am Surg* 1989; 55: 92-6.
5. Gauderer MWL, Ponsky JL, Izant RJ. Gastrostomy without laparotomy: a percutaneous endoscopic technique. *J Pediatr Surg* 1980; 15: 872-5.

### Corresponding Author

N. H. K. Jensen, M.D.  
Dept. of Surgery, Viborg Hospital  
8800 Viborg, Denmark  
Fax: +45-89273471



**Figure 1:** Percutaneous fixation of stomach to the abdominal wall using Endo Close suturing device (sideview); **1** gastrostomy tube, **2** Endo Close suturing device, **3** video gastroscopie, **4** stomach wall, **5** abdominal wall. The abdominal and gastric walls were punctured by an Endo Close suturing needle. A nonabsorbable suture (Ethibond 0, Ethicon) was attached to the needle while the stomach was kept in close contact with the abdominal wall by slight traction on the gastrostomy tube. The suture was grasped by the biopsy forceps and kept in place by the endoscopist. The needle was reinserted 1 cm from the first puncture site and the suture was caught by the Endo Close needle again and withdrawn.