

Color Doppler Endosonography of Esophageal Varices: Signal Enhancement After Intravenous Injection of the Ultrasound Contrast Agent Levovist

Duplex Doppler endosonographic transducers have opened up new opportunities in the evaluation of blood flow in esophageal varices (1–3). A new ultrasound contrast agent, Levovist (Schering), leads to a significant improvement in the detection and enhancement of color Doppler flow signals in several organs of the gut (4,5). We present here preliminary data on the combined use of color Doppler ultrasound and the ultrasound contrast agent Levovist. We report for the first time the detection of blood flow in esophageal varices that were not previously detectable using color Doppler endosonography without a contrast agent, and signal enhancement of the blood flow signals in esophageal varices that were previously detectable using endoscopic color Doppler ultrasound.

In five patients (four men, mean age 56 years, and one woman, age 40 years) with esophageal varices (one patient with grade I, one with grade II, two patients with grade III, and one patient with grade III varices, one week after sclerotherapy), endosonographic examination was carried out using a Pentax FG32-UA endoscope. The varices were examined by B-mode first, and then with color-coded Doppler ultrasound before and after intravenous injection of Levovist (Table 1). Prior to the application of the contrast agent, color flow signals could be detected in grade III varices only. After the application of Levovist, clear color flow signals were detected under the third echo-dense layer of the esophageal wall in patients with grade I and II varices, and in one patient a perforating vein was visualized (Figure 1). Color Doppler endosonography and ultrasound contrast agents can help to visualize blood flow in esophageal perforating veins and periesophageal vessels more clearly, and may provide new insights into the hemodynamics of portal hypertension.

H. Ernst, G. Nusko, E.G. Hahn, N. Heyder
Dept. of Medicine I, University of
Erlangen-Nuremberg, Erlangen, Germany

Patient	Grade of esophageal varices	CDE without contrast	CDE and Levovist 200 mg/ml	CDE and Levovist 300 mg/ml
1 M. J.	II	No flow signals	+*	+*
2 S. G.	III after sclerotherapy	No flow signals	No flow signals	No flow signals
3 O. U.	II–III	Flow signals	+*	+*
4 D. M.	I	No flow signals	*	+*
5 E. H.	III	Flow signals	+	+**

CDE: color Doppler endosonography.
0 No enhancement of color Doppler flow signals.
+ Enhancement of color Doppler flow signals.
* Additional flow signals in submucosal vessels.
** Additional flow in a perforating vein.

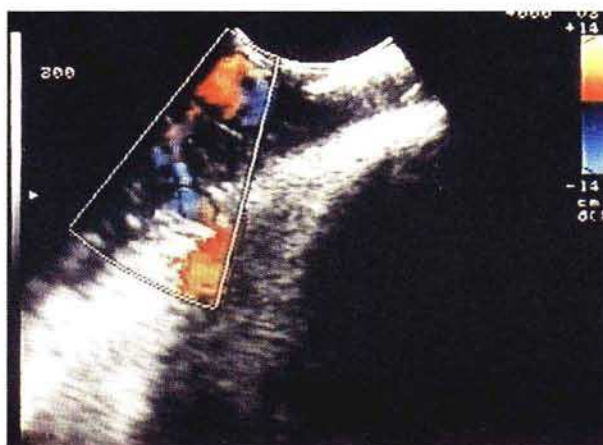
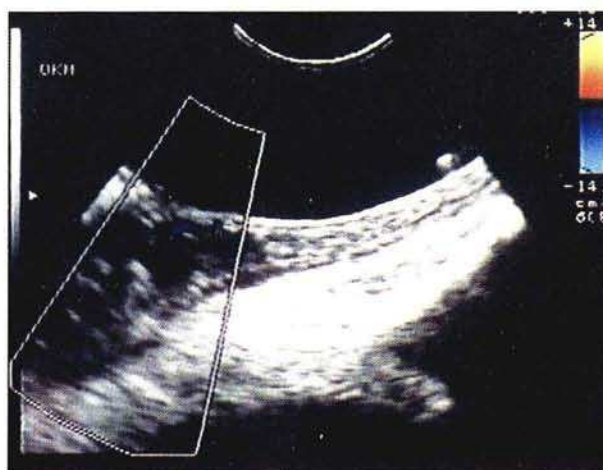


Table 1: Signal enhancement in color Doppler endosonography of esophageal varices.

Figure 1: Color Doppler endosonography with and without Levovist. **a** Color Doppler endosonography of Grade III varices without contrast agent.

Figure 1b: Color Doppler endosonography of Grade III varices after application of Levovist. There is enhancement of the color flow signals, and a perforating vein is visible.

References

- McCormack TT, Rose JD, Smith PM, et al. Perforating veins and blood flow in oesophageal varices. *Lancet* 1983; i: 1442–4.
- Kurtz W, Classen M. Messung des Blutflusses in Ösophagusvarizen mit einem endoskopischen Ultraschall-Doppler. *Dtsch Med Wochenschr* 1984; 10: 821–4.

- Bolondi L, Gaiani S, Zironi G, et al. Color Doppler endosonography in the study of portal hypertension. In: Heyder N, Hahn EG, Goldberg BB, editors. *Innovations in abdominal ultrasound*. Berlin: Springer, 1992: 61–9.
- Ernst H, Hahn EG, Balzer T, et al. Color Doppler ultrasound of liver lesions: signal enhancement after intravenous injection of the ultrasound contrast agent Levovist. *J Clin Ultrasound* 1996; 24: 31–5.

5. Schlieff R, Schürmann R, Niendorf HP. Saccharide-based ultrasound contrast media: basic characteristics and results of clinical trials. In: Heyder N, Hahn EG, Goldberg BB, editors. Innovations in abdominal ultrasound. Berlin: Springer, 1992: 1–7.

Corresponding Author

H. Ernst, M.D.
Dept. of Medicine IV, Charité
Schumannstrasse 20/21, 10117 Berlin
Germany
Fax: +49-30-2802-8978
E-mail: ernsthe@rz.charite.hu-berlin.de
