

Diffuse Involvement of the Gastrointestinal Tract with MALT Lymphoma

Gastrointestinal lymphomas are relatively rare tumors, representing 1–4% of primary gastrointestinal malignant neoplasms. The gastrointestinal tract is the most common site for extranodal lymphomas (1). The concept of mucosal-associated lymphoid tissue (MALT) has progressively developed during the past ten years in relation to the lymphoid component, mainly of B-cell derivation, observed in various organs and apparatus that do not correspond to peripheral sites of the immune system (2).

We report here the case of a 41-year-old man who presented with malaise, perspiration, weight loss, discomfort during bowel evacuation with tenesmus, dysuria, and lymph-node enlargement in the neck, both axillae, and the groin. Hyperplastic lymphoid tissue was noted on the hard palate. The physical examinations of the lung, heart, and abdomen were normal. There was a mild leukocytosis, with a shift toward myelocytosis, and signs of inflammatory syndrome were also present. The chest radiograph was normal. Ultrasound examination of the abdomen disclosed an enlarged stomach with giant folds, and an enlarged and steatotic liver, while the spleen, pancreas, and kidneys appeared normal. The retroperitoneal lymph nodes were enlarged, with an accompanying focal-type prostate enlargement. Gastrointestinal endoscopy disclosed thickened giant mucosal folds in the stomach (Figure 1), duodenal bulb, postbulbar region, and polypoid lesions in the first convolutions of the jejunum. Similar giant folds were found in the colonic mucosa of the rectum and sigmoid (Figure 2). Radiography of the small bowel revealed multiple filling defects in the jejunum and ileum.

The histopathology of the endoscopic biopsies of the stomach, small bowel, and rectosigmoid mucosa (fresh and paraffin-embedded material) showed lymphoepithelial lesions. At immunophenotyping, neoplastic cells expressing B-cell marker CD19 and lacking CD3, CD5, CD10 and CD23 markers were found (3,4). These findings suggested that the diffuse involvement of the mucosa was with B-cell lymphoma of the marginal zone (low-grade B-cell MALT lymphoma). Testing for *Helicobacter pylori* was negative. Similar lymphomatous infiltration was found in the specimens of the peripheral lymph

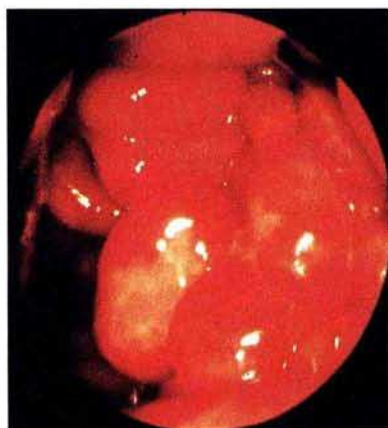


Figure 1: Thickened giant mucosal folds in the stomach.

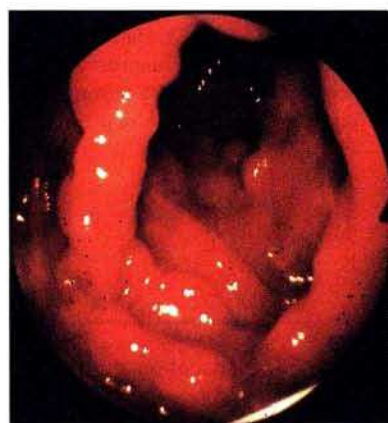

Figure 2: Giant mucosal folds in the colon.

nodes and in a transperineal biopsy of prostatic tissue (disseminated form of low-grade B-cell lymphoma, stage MALT-IV E).

Treatment with a LOPP chemotherapeutic regimen (chlorambucil (Leukeran), vin-

cristine (Oncovin), procarbazine, prednisone) was given in eight sessions. After eight courses, complete clinical and histological remission was achieved. The patient has been free of complaints for more than one year after the completion of treatment.

M. Uglješić¹, S. Janković², M. Petrović², N. Radošević², M. Marković¹

¹ Institute of Digestive Diseases

² Institute of Hematology, University Clinical Center, Belgrade, Yugoslavia

References

1. Talamonti SM, et al. Gastrointestinal lymphoma: a case for primary surgical resection. *Arch Surg* 1990; 125: 972–5.
2. Hernandez AJ, Sheehan WW. Lymphomas of the mucosa-associated lymphoid tissue: signet-ring cell lymphomas presenting in mucosal lymphoid organs. *Cancer* 1985; 55: 592–7.
3. Isaacson PG. Extranodal lymphomas: the MALT concept. *Verh Dtsch Ges Pathol* 1992; 76: 14–23.
4. Pileri S, et al. Malignant lymphomas of the gastrointestinal tract: a reappraisal on the basis of the newly proposed Revised European-American Lymphoma Classification. *Ital J Gastroenterol* 1994; 26: 405–18.

Corresponding Author

M. Uglješić, M.D., Ph.D.
Institute of Digestive Diseases
University Clinical Center
K. Todorovića 6
11000 Belgrade
Yugoslavia
Fax: +381-11-657887