

Selective Biliary Opacification through the Proximal Opening of a Sphincterotome Inserted into the Pancreatic Duct: A New Pitfall?

An awareness of unusual events that may occur during endoscopic retrograde cholangiopancreatography (ERCP) is important, as it helps the endoscopist to recognize the situation and therefore minimize the risks.

An 82-year-old woman presented with a typical cholangitis. An ERCP was carried out. A long, single-channeled sphincterotome (TW 1/19 ABS) was used directly. It twice entered the pancreatic duct, which was cautiously opacified. An injection during the third insertion selectively opacified the biliary duct, without any visible stone. In view of the context, a sphincterotomy was carried out, without any particular difficulty being experienced. A repeated failure to insert the balloon catheter into the bile duct, and its penetration in the pancreatic duct, led to a second, more careful, look at the films. In fact, the cannula had been in the pancreatic duct, opacified by the previously injected contrast, masking the sphincterotome. The final contrast injected had flowed through the proximal opening at the proximal end of the cutting wire, with the hole just facing the bile duct opening. The length between this hole and the distal one is 6 cm for this type of sphincterotome. The lack of distal flow was explained by the obstruction of the distal hole, impacted in the elbow of the Wirsung's duct. With this type of sphincterotome, the contrast leaves the channel mainly through the first proximal opening. After a film failed to show any perforation, the bile duct was cannulated, and a biliary sphincterotomy was carried out easily. The balloon retrieved a small stone. The patient's recovery was uneventful, and one year later she had no complaints.

The principal reason for this error was that the possibility was not considered that selective biliary opacification after a deep cannulation could be possible with the cannula somewhere outside of the bile duct.

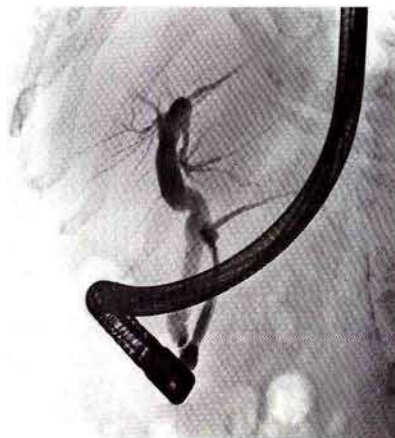


Figure 1: Selective opacification of the biliary duct through the proximal opening of the papillotome, which was inserted into the already opacified pancreatic duct. There is no pancreaticobiliary fistula.

Although the incident was not a serious one, it emphasizes the fact that selective opacification after a deep cannulation does not necessarily mean that the correct duct has been entered. So far as I am aware, this potential pitfall has not previously been reported; since this paper was first submitted, an associate has encountered a similar case. The use of double-lumen sphincterotomes could prevent the problem.

B. Maroy

Maison Médicale de Lunesse, L'Isle D'Espagnac, France

Corresponding Author

B. Maroy, M.D.

Maison Médicale de Lunesse

16340 L'Isle D'Espagnac

France

Fax: +33-5-45942500