

Endoscopic Management of Food-Filled Duodenal Diverticulum Mimicking a Pancreatic Tumour

Compression of the distal common bile duct by a juxtapapillary diverticulum is a well-recognized condition. We describe here a case in which a mass in the head of the pancreas was suggested by ultrasonography, and obstruction was relieved by a simple endoscopic technique.

A 64-year-old woman presented with jaundice and upper abdominal pain. Serum bilirubin was $52 \mu\text{mol/l}$, alkaline phosphatase 2413 U/l, aspartate transaminase 330 U/l, and alanine transaminase 392 U/l. The ultrasound examination revealed dilation of the common bile duct, of the intrahepatic ducts, and of a stone-free gallbladder (Figure 1). There was also an apparent mass in the region of the head of the pancreas (Figure 2). Attempted endoscopic retrograde cholangiopancreatography showed that the papilla was hidden in a large diverticulum that was packed with vegetable matter (Figure 3). Using a balloon catheter and tripod forceps, the diverticulum was cleared completely of debris, and this was followed by a gush of bile from a papilla that was still not visible. Due to concern about introducing infection into the biliary system or pancreas, no attempt was made to cannulate. After the procedure, the patient's liver biochemistry returned completely to

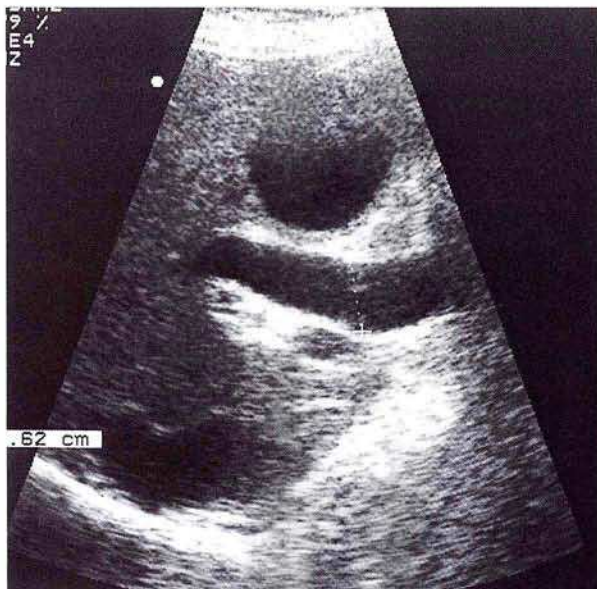

Figure 1: Dilation of the common bile duct.

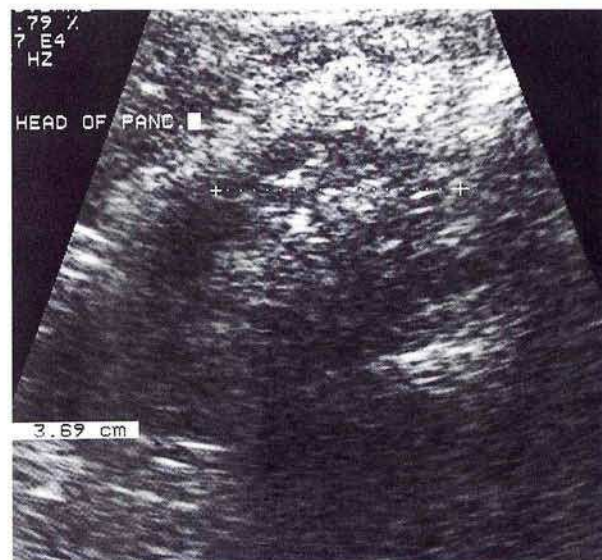

Figure 2: An apparent mass in the region of the head of the pancreas.

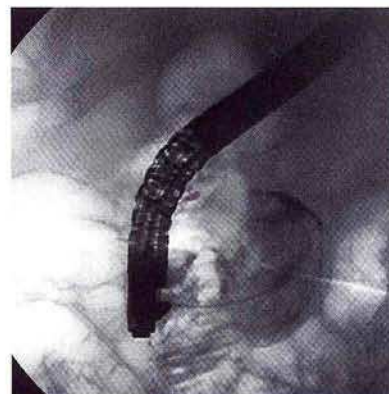


Figure 3: Injection of contrast into the diverticulum confirms packing with food matter.

normal, and a repeat ultrasound examination two weeks later showed normal-calibre ducts and no mass lesion. She declined further investigations, but has been well during six months of follow-up.

The present case shows that food matter within a duodenal diverticulum may mimic a pancreatic tumour, not only clinically but also on ultrasound. Although surgery will provide a definitive cure (1), endoscopic management (which we have not seen described previously) is simple, provides immediate relief of the obstruction, and may be sufficient treatment in frail, elderly patients (although recurrence is possible).

W. Dickey, M. Reilly

Dept. of Gastroenterology, Dept. of Radiology, Altnagelvin Hospital, Londonderry, Northern Ireland, United Kingdom

Reference

1. San Romain AL, Moreira VF, Garcia M, et al. Direct compression by a duodenal diverticulum causing common bile duct obstruction. *Endoscopy* 1994; 26: 334.

Corresponding Author

W. Dickey, M.D., Altnagelvin Hospital
Londonderry BT471SB, Northern Ireland
United Kingdom, Fax: +44-1504-611218