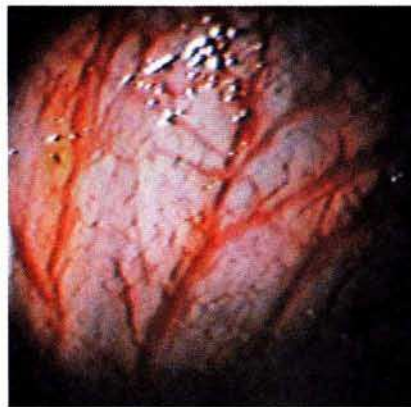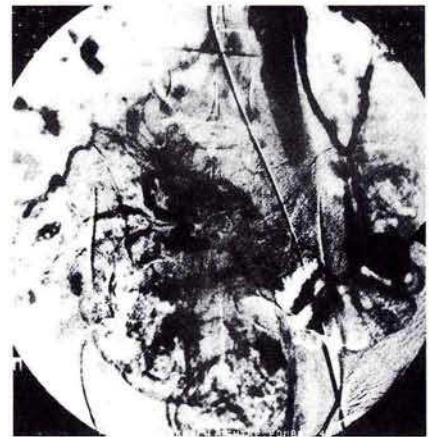


### Type 2 Arteriovenous Malformation of the Sigmoid Colon with Unusual Angiographic and Characteristic Histologic Appearances

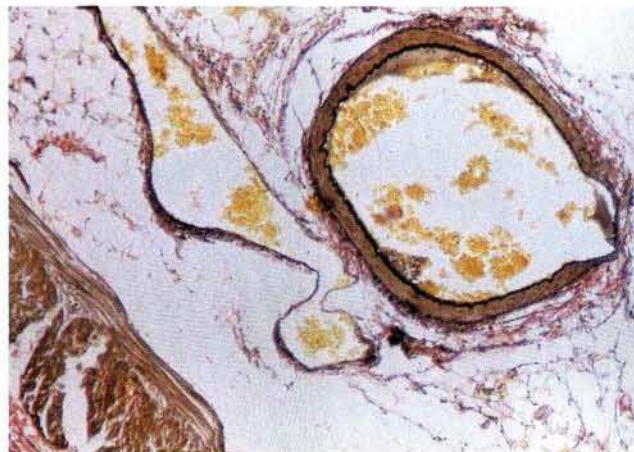Vascular anomalies of the gastrointestinal tract can cause obscure gastrointestinal bleeding. Their nomenclature and classification can be difficult. Whereas colonoscopy and angiography help in diagnosis (1), histology helps in classification (2,3). A 16-year-old boy presented with episodes of rectal bleeding from the age of one year, without bleeding from other mucous membranes and without systemic complaints. The family history was negative. He had been taking anticonvulsants since the age of two for grand mal epilepsy. Except for pallor, the clinical examination was normal. His haemoglobin was 8g/dl and coagulation parameters were normal. Colonoscopy demonstrated a circumferential leash of dilated, tortuous vascular channels in the sigmoid colon (Figure 1). Digital subtraction angiography revealed a contrast blush in the region of the sigmoid colon, with early opacification of a massively dilated inferior mesenteric vein (Figure 2). The patient underwent resection of the colonic malformation. Histology revealed dilated, thick-walled vascular channels (both arterial and venous) infiltrating the mucosa, submucosa, muscularis propria and serosa (Figure 3a and b). During the postoperative period the patient developed status epilepticus, to which he succumbed. Type 1 lesions (angiodysplasia) are acquired, occur in the elderly, are present in the cecum, right colon or terminal ileum, and are limited to the mucosa and submucosa. Type 2 arteriovenous malformations (AVMs) are congenital, affect the young, occur in the small bowel and involve all layers of the gut wall, having both arterial and venous components. Type 3 lesions (hereditary hemor-



**Figure 1:** Colonoscopic appearance – dilated tortuous abnormal vessels in sigmoid colon.



**Figure 2:** Digital subtraction angiography showing vascular blush (arrow head).



**Figure 3:** Histological appearance of vascular lesion: Van Gieson stain revealed both arterial and venous structures in the lesion.

rhagic telangiectasia) usually involve the entire gastrointestinal tract, with oral mucosal lesions and a positive family history. Type 4 lesions are acquired angiodysplasias seen with systemic disorders. Whereas angiodysplasias are predominantly submucosal venous channels which never infiltrate the muscular or serosal layers, telangiectasia can involve the full thickness of the bowel wall but never have an arterial component (3). Our patient had type 2

AVM with unusual angiographic and characteristic histological features. Isolated involvement of the sigmoid colon with a type 2 AVM is rare, with only a single similar report in the literature (4). It is important to differentiate the type of vascular anomaly in a given patient, as it has a bearing on the treatment.

S. G. Kulkarni<sup>1</sup>, P. S. Dhawan<sup>1</sup>,  
S. S. Shah<sup>1</sup>, R. Rananavare<sup>2</sup>, I. M. Vora<sup>3</sup>,  
K. Shankaran<sup>1</sup>, R. H. Kalro<sup>1</sup>  
<sup>1</sup> Dept. of Gastroenterology  
<sup>2</sup> Dept. of Radiology  
<sup>3</sup> Dept. of Pathology,  
BYL Nair Hospital and TN Medical  
College, Bombay, India

#### References

1. Richardson JD, Max MH, Flint LM, Schweisinger W, Howard M, Aust JB. Bleeding vascular malformations of the intestine. *Surgery* 1978; 84: 430–6.
2. Richardson JD. Vascular lesions of the intestines. *Am J Surg* 1991; 161: 284–93.
3. Mitsudo SM, Boley SJ, Brandt LJ, et al. Vascular ectasias of the right colon in the elderly: a distinct pathologic entity. *Hum Pathol* 1979; 10: 585–600.
4. Beteta Chinchilla CE, Ramirez Mayans JA, Mora Tiscareno MA, et al. Case report on AVM. *Rev Gastroenterol Mex* 1991; 56: 203–11.

#### *Corresponding Author*

P. S. Dhawan  
5/1 Mitra Kunj  
16 Pedder Road  
Bombay 400026  
India  
Fax: +91-022-3075243