
Endoscopic Management of a Retrogastric Abscess Complicating Laparoscopic Appendectomy

Intra-abdominal abscesses are life-threatening complications following surgery. Traditionally, two interventional strategies are considered: reoperation and radiological percutaneous drainage (1). However, the morbidity and mortality rates associated with reoperation are significant, and percutaneous puncture of a retrogastric abscess may be difficult. Endoscopic transmural abscess decompression offers a new opportunity in the management of gastric complications following surgery.

A case of retrogastric abscess is reported here, as an exceedingly rare complication of appendectomy which was successfully treated by endoscopic means. A 26-year-old man was subjected to a laparoscopic appendectomy several hours after the onset of the symptoms. During the first few days after surgery, symptomatic septicemia associated with abdominal pain developed. Computed tomography of the abdomen revealed a large heterogeneous mass, prob-

ably an abscess, in the retrogastric space. Due to the patient's poor general condition and the difficulty of access for effective percutaneous drainage, an endoscopic approach was chosen.

The abscess showed prominent compression and was covered by mosaic-type mucosa in the posterior wall of the stomach (Figure 1). The puncture was made using the diathermic needle at the site of maximal bulging. Thick, yellow pus was then released into the gastric lumen. The opening was then enlarged using a three-pronged polyp retrieval device (Figure 2). Immediate decompression was observed. There were no complications after the procedure. A check-up computed tomography five days later showed almost complete resolution of the abscess.

The modified technique used here is recognized for cystoenterostomy (2,3). Endoscopic transmural puncture and drainage of

pancreatic pseudocysts is now regarded as a fairly safe method, with the most common complications, bleeding and perforation, occurring in 5–10% of cases (4). It is also highly effective, with a success rate of 90% (4). The method has already been applied for decompression of a transgastric abscess associated with postoperative pancreatic duct leakage (5). Endoscopic creation of a fistula between the abscess and the gastric lumen can therefore be regarded as a safe and effective method of managing surgical complications.

J. F. Rey¹, A. Budzynska²

¹ Dept. of Hepatology and Gastroenterology, Institut Arnault Tzanck, Saint-Laurent du Var, France

² Dept. of Gastroenterology, Silesian Medical Academy, Katowice, Poland

References

1. Schoeffel U, Haring R, Farthmann EH. Diagnose und Behandlungsstrategie intraabdomineller Abszesse. *Zentralbl Chir* 1993; 118: 303–8.
2. Kozarek RA, Brayko CM, Harlan J, et al. Endoscopic drainage of pancreatic pseudocyst. *Gastrointest Endosc* 1985; 31: 322–8.
3. Gerolami R, Giovannini M, Laugier R. Endoscopic drainage of a pancreatic pseudocyst guided by endosonography. *Endoscopy* 1997; 29: 106–8.
4. Cremer M, Devière J, Engelholm L. Endoscopic management of cysts and pseudocysts in chronic pancreatitis: long-term follow-up after 7 years of experience. *Gastrointest Endosc* 1989; 35: 1–9.
5. Sarzen CD. Endoscopic management of pancreatic duct leak complicated by retrogastric abscess. *Am J Gastroenterol* 1995; 90: 2039–41.

Corresponding Author

J. F. Rey, M.D.
 Dept. of Hepatology
 and Gastroenterology
 Institut A. Tzanck
 Av. du Dr. Maurice Donat
 06700 Saint-Laurent du Var
 France
 Fax: + 33-4-9307-5158
 E-mail: jean-francois.rey@wanadoo.fr

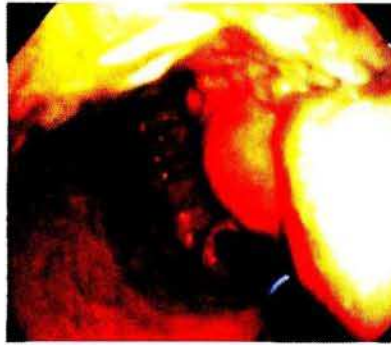


Figure 1: The large abscess, presenting with prominent, double bulges of compression of the posterior wall of the stomach.

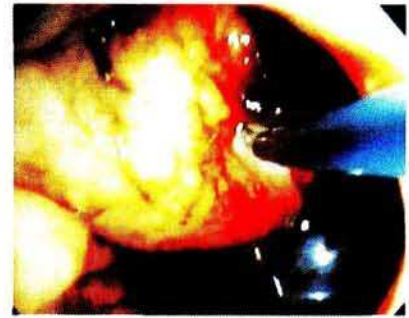

Figure 2: Decompression of the abscess using a three-pronged retrieval device to enlarge the opening.