

## Interventional EUS: Difficult pancreaticobiliary access

M. Giovannini, Ch. Pesenti, E. Bories, F. Caillol  
Endoscopic unit, Paoli-Calmettes Institute 232 Bd St-Marguerite,  
13273 Marseille Cedex 9 FRANCE

### Introduction

Endoscopic biliary stenting is the most common method to treat obstructive jaundice. But in 3–12% of cases, selective cannulation of the major papilla failed and surgery or percutaneous biliary drainage is required. But percutaneous drainage needed dilated intrahepatic biliary ducts and the rate of complications reach 20% of cases including peritoneal bleeding. A new technique of biliary drainage using EUS and EUS guided puncture of the bile duct (common bile duct or left hepatic duct) is now possible.

Using EUS guidance and dedicated accessories it's now possible to create bilio or pancreatico-digestive anastomosis.

### EUS guided bilio-digestive anastomosis

Endoscopic biliary stenting is the most common method to treat obstructive jaundice. But in 3–12% of cases, selective cannulation of the major papilla failed and surgery or percutaneous biliary drainage is required. But percutaneous drainage needed dilated intrahepatic biliary ducts and the rate of complications reach

**Correspondence:** M. Giovannini · Endoscopic unit · Paoli-Calmettes Institute 232 Bd St-Marguerite · 13273 Marseille Cedex 9 · FRANCE · E-mail: [hdjchir@marseille.fnclcc.fr](mailto:hdjchir@marseille.fnclcc.fr)

**Bibliography:** Endoscopy 2006; 38 (S1): S93–S95 © Georg Thieme Verlag KG Stuttgart · New York · ISSN 0013-726X · DOI 10.1055/s-2006-946665

20% of cases including peritoneal bleeding. A new technique of biliary drainage using EUS and EUS guided puncture of the common bile duct (CBD) or the left hepatic duct (segment 3) is now possible.

### Technique of EUS guided biliary drainage

Using therapeutic EUS scope, CBD was punctured with a 5F needle-knife under EUS guidance and a cholangiography was obtained. The metallic part of the needle-knife was removed and a 00.35 inch guide wire was introduced in the CBD. On the guide wire a 6.5F Sohendra dilator (Wilson-Cook corporation) was placed in the CBD and allowed the placement through the duodenum of a 10F plastic stent or a covered metallic expandable stent.

### Technique of EUS guided hepatico-gastrostomy (Fig. 1)

By using an interventional echoendoscope, the dilated left hepatic duct (segment III) was well visualized. HGE was then performed under combined fluoroscopic and ultrasound guidance, with the tip of the echoendoscope positioned such that the inflated balloon was in the middle part of the small curvature of the stomach. A needle (19 G, Echotipp Ultrasound Needle, EUSN-19-T, Cook Ireland Ltd., Limerick, Ireland) was inserted transgastrically into the distal part of the left hepatic duct and contrast medium was injected. Opacification demonstrated a dilated biliary ducts to the complete obstruction. The needle was exchanged over a guidewire (0.02 inch diameter, Terumo Europe, Leuven, Belgium) for a 6.5F diathermic sheath (prototype Cysto-Gastro set, Endo-Flex, Voerde, Germany), which was then used to enlarge the channel between the stomach and the left hepatic duct. The sheath was introduced by using cutting current. After exchange over a guidewire (TFE-coated 0.035 inch diameter, Cook Europe, Bjaeverskov, Denmark), a 8.5 F, 8-cm-long hepatico-gastric stent) or a covered metallic expandable stent (Boston-scientific, 8 cm length) was positioned. As observed by fluoroscopy, contrast emptied from the stent into the stomach.

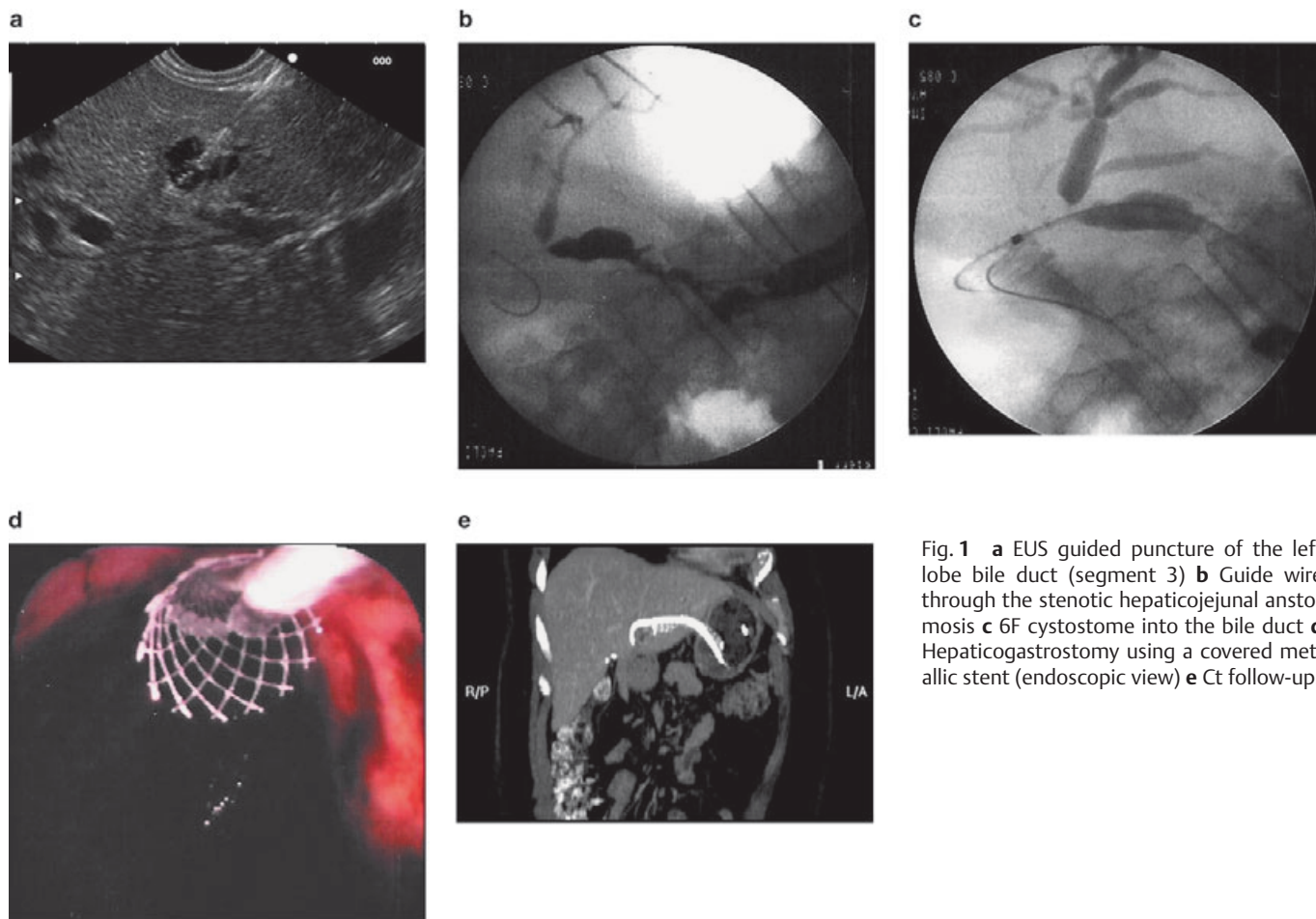
To prevent bile leakage you can leave through the metallic stent a 6 or 7F naso-biliary drain in aspiration during 48 hours.

### Place of the bilio-digestive anastomosis guided by EUS in comparison with ERCP

ERCP is still today the Gold Standard technique for the drainage of an obstructive jaundice due to a pancreatic cancer. Success rate of biliary stenting using ERCP is around 80–85% but sometime ERCP failed to cannulate selectively the papilla or failed to reach the papilla in case of duodenal obstruction.

These new techniques of biliary drainage using EUS guidance could be an alternative to percutaneous procedures or to Surgery.

The problem with the percutaneous techniques of biliary drainage is the high rate of complication (bleeding, peritoneal bile leakage) around 12 to 20% of the cases and the morbidity and the mortality of Surgery for such palliative procedures are respectively of 35–50% and 10–15%.



**Fig. 1** **a** EUS guided puncture of the left lobe bile duct (segment 3) **b** Guide wire through the stenotic hepaticojejunal anastomosis **c** 6F cystostome into the bile duct **d** Hepaticogastrostomy using a covered metallic stent (endoscopic view) **e** Ct follow-up.

For probably, these new techniques of biliary drainages will be in the future an alternative to Surgery and percutaneous biliary drainage.

Regarding the data in the literature, we have found two studies concerning the hepaticogastrostomy guided by EUS. The first was published by Burmeister et al. about 4 cases [1]. Four cases of successful EUS-guided-cholangio-drainage are presented in which the major papilla could not be cannulated at ERCP. For puncture of the intrahepatic or extrahepatic bile duct, a modification of the one-step technique for the drainage of pancreatic pseudocysts was used. Stent insertion was successful in 3 of the 4 patients. In these 3 patients cholestasis resolved promptly. The second was our work about 2 patients using plastic stents in one case and an expandable covered metallic stent in the second case [2].

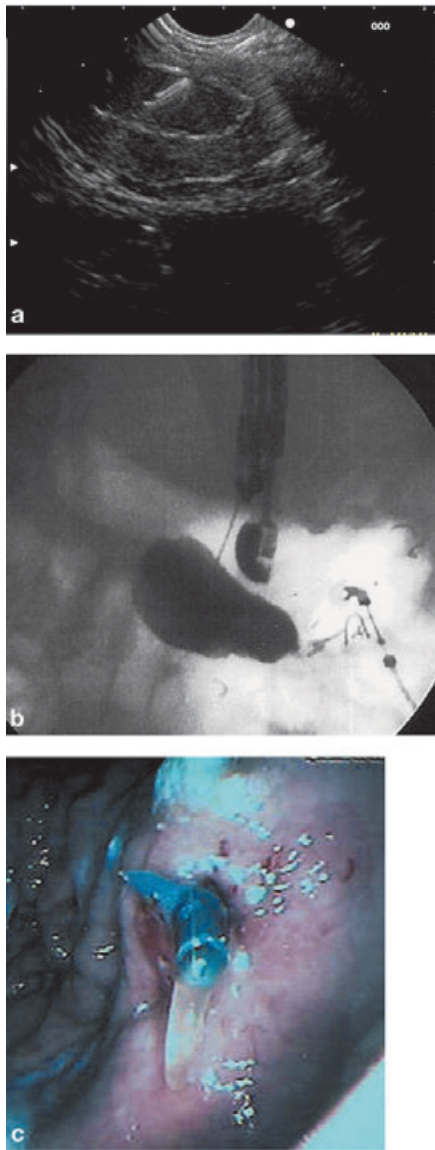
Concerning the common bile duct drainage, there are also 2 studies. The first was published in 2001 about one case of biliary stenting using the echoendoscope [3]. The second is more recent using therapeutic echoendoscope to perform EUS guided “rendez-vous” technique. EUS-guided transgastric or transduodenal needle puncture and guidewire placement through obstructed pancreatic ( $n = 4$ ) or bile ( $n = 2$ ) ducts was attempted in 6 patients [4]. Efforts were made to advance the guidewire antegrade across the papilla or surgical anastomosis. If guidewire passage was successful, rendezvous ERCP with stent placement was performed immediately afterward. EUS-guided duct access and in-

traductal guidewire placement was accomplished in 5 of 6 cases, with successful traversal of the obstruction, and rendezvous ERCP, with stent placement in 3 of 6 cases (two biliary, one pancreatic). The procedure was clinically effective in all successful cases (two patients with malignant obstructive jaundice, one with relapsing pancreatitis after pancreaticoduodenectomy). There was one minor complication (transient fever) but no pancreatitis or duct leak after successful or unsuccessful procedures. EUS is a feasible technique for allowing rendezvous drainage of obstructed biliary or pancreatic ducts through native papillae or anastomoses after initially unsuccessful ERCP.

#### EUS guided pancreatico-gastrostomy (Fig. 2)

The pain associated with chronic pancreatitis (CP) is caused, at least in part, by ductal hypertension. Both surgical and endoscopic treatments can relieve pain by improving ductal drainage. Endoscopic drainage requires transpapillary access to the pancreatic duct during ERCP.

The development of interventional EUS has provided better access to the region of the pancreas. Just as pancreatic fluid collections, such as pseudocysts, can be successfully drained from the stomach or duodenum by endoscopic cystenterostomy or cystogastrostomy, the same technique could be used to access a dilated pancreatic duct in cases in which the duct cannot be drained by conventional ERCP because of complete obstruction.



**Fig. 2** a EUS puncture of a dilated pancreatic duct (stenosis due to post-traumatic acute pancreatitis) b Opacification of the duct c pancreaticogastrostomy using a 8.5 F plastic stent.

### Technique

By using an interventional echoendoscope, the dilated MPD was well visualized. EPG was then performed under combined fluoroscopic and ultrasound guidance, with the tip of the echoendoscope positioned such that the inflated balloon was in the duodenal bulb while the accessory channel remained in the antrum. A needle (19 G, Echotipp Ultrasound Needle, EUSN-19-T, Cook Ireland Ltd., Limerick, Ireland) was inserted transgastrically into the proximal pancreatic duct and contrast medium was injected. Opacification demonstrated a dilated MPD proximal to the complete obstruction. The needle was exchanged over a guidewire (0.02 inch diameter, Terumo Europe, Leuven, Belgium) for a 6.5F diathermic sheath (prototype Cysto-Gastro set, EndoFlex, Voerde, Germany), which was then used to enlarge the channel between the stomach and MPD. The sheath was introduced by using cutting current. After exchange over a guidewire (TFE-coated 0.035 inch diameter, Cook Europe, Bjaeverskov, Denmark), a 6F, 8-cm-long pancreaticogastric stent (cut from a 6F nasobiliary catheter, Cook Europe) was positioned. There was no bleeding from the puncture site. As observed by fluoroscopy, contrast emptied from the stent into the stomach.

### Discussion

The results of the first series of patients published are much too preliminary in nature to recommend wider use of EPG, which in any case should be restricted to tertiary centers specializing in biliopancreatic therapy. Nevertheless, the possibility of draining the MPD into the digestive tract through an endoscopically created fistula, with patency maintained by stent placement, might be interesting as an alternative method of drainage without the complication of stent occlusion that is associated with transpapillary drainage. In conclusion, pancreatic ductal hypertension, as reflected by duct dilation, is a cause of pain in some patients with CP. Although endoscopic ductal decompression is useful in such cases, conventional ERCP occasionally fails to obtain access to the targeted dilated duct. EUS-guided pancreaticogastrostomy in 4 patients is described here as a new method of ductal decompression in selected cases [5]. Further evaluation of this technique including longer-term follow-up of patients is warranted.

### Conclusion

Therapeutic EUS as EUS guided pancreaticogastrostomy and hepatico-gastrostomy can represent today an alternative to Surgery when the endoscopic procedures failed. But, in the future dedicated accessories for such procedures will be needed.

### References

- Burmester E, Niehaus J, Leineweber T, Huetteroth T. EUS-cholangiodrainage of the bile duct: report of 4 cases. *Gastrointest Endosc* 2003 Feb; 57 (2): 246–251
- Giovannini M, Dotti M, Bories E, Moutardier V, Pesenti C, Danisi C, Delpero JR. Hepaticogastrostomy by echo-endoscopy as a palliative treatment in a patient with metastatic biliary obstruction. *Endoscopy* 2003 Dec; 35 (12): 1076–1078
- Giovannini M, Pesenti Ch, Rolland AL, Mouardier V, Delpero JR. Endoscopic ultrasound guided bilioduodenal anastomosis: a new technique for biliary drainage. *Endoscopy* 2001; 33: 898–900
- Mallery S, Matlock J, Freeman ML. EUS-guided rendezvous drainage of obstructed biliary and pancreatic ducts: Report of 6 cases. *Gastrointest Endosc* 2004 Jan; 59 (1): 100–107
- Francois E, Kahaleh M, Giovannini M, Matos C, Dviere J. EUS-guided pancreaticogastrostomy. *Gastrointest Endosc* 2002 Jul; 56 (1): 128–123