

Chronic pancreatitis: Focal pancreatitis or cancer? Is there a role for FNA/biopsy? Autoimmune pancreatitis

M. J. Levy¹, M. J. Wiersema², S. T. Chari¹

¹ Division of Gastroenterology and Hepatology, Mayo Clinic, 200 First Street SW, Rochester, MN 55905

² Indiana Medical Associates, 2512 E Dupont Road, Suite 110, Fort Wayne, IN 46825

EUS and tissue sampling to distinguish focal pancreatitis from pancreatic carcinoma

EUS imaging has become routine for evaluation of pancreatic masses because of the staging information provided and ability to obtain a tissue diagnosis. However, distinction of pancreatic carcinoma from other malignant and benign pancreatic disorders, in particular focal chronic pancreatitis is particularly difficult. Efforts to increase the accuracy of sonographic imaging have included ultrasound contrast administration [1,2] and use of a self-learning computer program for image analysis. [3] Early results offer promise as to their utility as an adjunctive measure to improve diagnostic accuracy. However, further study is needed to clarify the role of these techniques before general use can be advocated. Until then these techniques should be regarded as investigational.

The addition of fine needle aspiration (FNA) and cytologic review improves evaluation of pancreatic masses providing a sensitivity of ~80–90%, specificity of ~95–100%, and accuracy of ~90–95% [4–10]. While FNA is a valuable tool in some, it may not be necessary in all. Although EUS FNA safely provides a high diagnostic accuracy in pancreatic cancer patients [8,11,12], measures should be taken to eliminate unnecessary pancreatic biopsy and to minimize the risk in those whom FNA is indicated. EUS findings most significantly impact clinical decision making in patients with equivocal computed tomography (CT) findings as defined by uncertain presence of a mass and/or potential resectability. EUS is used to verify the presence or absence of a mass and for locoregional staging. When EUS detects unresectable disease then FNA allows a tissue diagnosis. In patients with an apparent resectable mass on CT, EUS appears to maintain a useful role in searching for occult hepatic [13] and/or distant nodal metastases [14], either of which precludes surgery for curative intent. It is in patients with a presumed resectable tumor on PPCT and EUS that the need for a preoperative tissue diagnosis is most debated. There are several potential advantages and disadvantage of pursuing a tissue diagnosis in this setting.

Correspondence: Michael J. Levy, M.D. · Director of Endoscopic Ultrasound · Mayo Clinic · Division of Gastroenterology and Hepatology · 200 First Street SW · Rochester, MN 55905 · Phone: (507) 266-6931 · Fax: (507) 266-3939 · E-mail: levy.michael@mayo.edu

Bibliography: Endoscopy 2006; 38 (S1): S30–S35 © Georg Thieme Verlag KG Stuttgart · New York · ISSN 0013-726X · DOI 10.1055/s-2006-946648

Potential disadvantages in pursuing a tissue diagnosis include:

- 1.) The false negative rate of 15–20% that results from pancreatitis and associated inflammation or fibrosis, sampling error, bloody aspirates and errors of cytological interpretation [7,15,16]. A negative biopsy leaves great uncertainty as to whether it represents a true negative or false negative finding, particularly in those with a high clinical suspicion. Therefore a negative result seldom influences the decision to proceed to surgery.
- 2.) The risk for complications including pancreatitis, bleeding, and tumor seeding of the peritoneum and/or needle tract [11,15,17–19]. Although relatively infrequent (~1–2%), their occurrence may delay, complicate, or even preclude surgical intervention. For this reason, many surgeons avoid biopsy of any pancreatic mass that appears potentially resectable.

Potential advantages for pursuing a tissue diagnosis include:

- 1.) Confirmation of a ductal carcinoma so patients may receive neoadjuvant chemotherapy and/or radiation therapy prior to surgery.
- 2.) The ability to identify an islet cell tumor, lymphoma, small cell carcinoma, metastatic disease, as well as non-malignant processes such as autoimmune or non-specific chronic pancreatitis. Patients with these disorders typically benefit from alternate management strategies [20,21]. Use of clinical, laboratory, non-invasive imaging, and EUS appearance may offer clues as to the presence of these alternate diagnoses and guide biopsy in this setting.
- 3.) Many prefer a preoperative tissue diagnosis due to the associated morbidity and mortality of pancreatic surgery and risk of resecting a benign mass. Some would argue that despite the poorer outcomes in some centers, clinical decision-making should be the same. This opinion, however, must be balanced by the affect on physicians and patients who experience poor operative outcomes following resection of what is later realized to be a benign lesion.
- 4.) Provision of additional information that may assist in preoperative patient and family counseling and selection of therapy. During patient counseling, the differential diagnosis and management options are explained to the patient as well as the ~5% chance of resecting a benign process [22]. Patients are informed as to the need for resection regardless of the underlying pathology. This approach spares unnecessary biopsy. However, patient concerns often do necessitate EUS FNA and allow focusing the preoperative discussion on the therapy of a known malignancy.

When the decision is made to pursue a tissue diagnosis, steps may be taken to optimize the technique to increase diagnostic accuracy and to minimize the need and risk of pancreatic biopsy including:

- 1.) Availability of an onsite cytotechnologist or cytopathologist [7,15,16], which improves the diagnostic sensitivity by ~10% compared to performing a predetermined number of biopsies [23].

2.) Prioritizing the sequence of EUS FNA by directing initial biopsies to sites most significantly impacting tumor stage and patient management [24,25]. This may be achieved through sequential biopsy of: 1.) suspected liver metastases, 2.) malignant appearing mediastinal lymph nodes, 3.) ascitic fluid, 4.) malignant appearing “distant” abdominal lymph nodes, 5.) a malignant appearing local lymph nodes, and then 6.) pancreatic FNA if malignancy is not present in the other sites. This approach avoids need for pancreatic FNA in 10–20% of patients [7,15,19,26–28].

3.) Needle caliber. Limited data support the contention that large caliber (19-gauge) standard needles as well as trucut biopsy needles enhance diagnostic sensitivity [29,30] and potentially after fewer needle passes [31]. Also, EUS TCB enable diagnosis of pathologic states that are difficult to diagnose using FNA alone including AIP, lymphoma, and vascular tumors [30,32]. However, these needles are more difficult to use and have an uncertain safety profile.

4.) Special stains and molecular markers. Diagnosis may be aided by use of special stains for neuroendocrine tumors, flow cytometry for lymphoma, and IgG4 staining for AIP. Initial data support the utility of molecular markers such as *p53* gene mutation [33], *K-ras* mutation [34–36], telomerase activity [35], MUC1 and MUC 2 analysis [37], digital image analysis [38], and fluorescence in situ hybridization [38]. These markers may help distinguish benign from malignant tumors when applied to tissue samples or pancreatic fluid. Although results are encouraging and offer promise as an adjunctive measure to improve diagnostic accuracy, their use is still investigational. Further study is needed to clarify the role of these techniques before their use can be widely advocated.

Summary

EUS provides high resolution imaging and guides biopsy often allowing distinction of benign from malignant pancreatic masses when other studies are unable to make this distinction. Controversy centers mostly on appropriate patient selection for FNA. For many patients with a pancreatic mass lesion, there is a clear role for attempted tissue diagnosis and for many others, the role is uncertain and FNA is discouraged. No one approach suits all patients or physicians. FNA findings often do serve as a useful piece of the diagnostic puzzle and may tip the scales in favor of resection or careful observation for those in whom the diagnosis, resectability, and/or operability are in question. In addition, much of the reluctance for pancreatic biopsy lingers from prior uncertainty regarding the safety of EUS FNA, which based on recent reports appears to be an overstated concern. However, the perceived need to obtain a tissue diagnosis in all patients is discouraged. Instead practice patterns should be guided by patient desires and operability, the wishes of the consulting physicians, local expertise, and one’s practice settings. It is also important that each endosonographer be aware of the performance characteristics of EUS, percutaneous, and surgical biopsy in their center. Diagnostic sensitivities and specificities lower than those reported in the literature further reduce the value of FNA and argue against pancreatic biopsy. The overriding consideration must be the potential impact of FNA results on clinical decision making, prognosis, and management. When biopsies are deemed necessary, we should employ methods for acquiring FNA samples

shown to reduce the need for pancreatic biopsy, to enhance diagnostic accuracy, and improve safety.

II. EUS and tissue sampling to evaluate autoimmune pancreatitis

Despite the established diagnostic accuracy of EUS FNA in most settings, certain neoplasms such as gastrointestinal stromal tumors and lymphoma are often difficult to diagnose by cytologic review [7,23,39]. In addition, well differentiated tumors, tumors with substantial desmoplasia and vascular tumors may be difficult to diagnose using cytology alone [7]. The diagnosis of autoimmune pancreatitis requires a larger specimen than can be provided by FNA alone.

To overcome limitations of needles only allowing cytologic review, large caliber cutting biopsy needles have been developed that acquire samples that allow preservation of tissue architecture and histologic examination [40–47]. Biopsies with these needles have been conducted via several routes including percutaneous (with conventional ultrasound or computed tomography guidance), intraluminal (transanal, transrectal, transvaginal, and transjugular), and surgical (laparoscopic and open) [47–56]. Studies have demonstrated the safety and accuracy of trucut biopsy for diagnosing solid lesions arising in soft tissue, breast, lung, lymph node, pancreas, liver, kidney, adrenal, spleen, prostate, and other sites [47–49,55,57–59]. A trucut biopsy needle has been designed to operate with an echoendoscope (Quick-Core, Wilson-Cook, Winston-Salem, North Carolina). A disposable 19-gauge needle with a tissue tray and sliding sheath permits a histologic core to be obtained. A standard spring-loaded mechanism is employed within the handle to permit automated procurement of biopsy specimens. Our recently described experience with EUS TCB initially in swine [60] and later in humans [61] demonstrated the safety of this device for acquiring histologic tissue representative of the target organs or neoplasm.

Most consider cytologic examination of EUS FNA specimens to be insufficient for diagnosing AIP due to the small sample and lack of tissue architecture. EUS TCB acquires core specimens that preserve tissue architecture and permit histologic review and diagnosis of AIP. Histopathologic features vary, but the most common finding is fibrosis and an intense inflammatory cell infiltrate comprised mostly of lymphocytes and plasma cells usually surrounding medium and large size interlobular ducts accompanied by an obliterative phlebitis predominantly involving venules. Although characteristic histologic findings exist, until recently it has been impractical to use histology to definitively establish the diagnosis preoperatively. What follows is an update to our previously reported experience using EUS and tissue sampling in patients with AIP [32,62].

Mayo experience

To date, 14 patients with a final diagnosis of AIP have undergone EUS TCB with a disposable 19-gauge trucut needle (QuikCore, Wilson-Cook, Winston-Salem, NC), 10 of whom also underwent EUS FNA. The criteria for the diagnosis of AIP were based on a previously established combination of clinical presentation, patient outcome, laboratory findings, and imaging studies [63–

65]. The mean age was 63 years (range 29–85) and 10 were males. A total of 39 TCBS (2.8 biopsies/patient, range 1–4) were obtained from the pancreatic neck, body, and/or tail region. In addition 53 FNAs (5.3 passes/patient, range 2–12) were obtained from ten of the patients. FNA was not performed in all patients due to the earlier experience of failed diagnosis following FNA. The findings of TCB were considered “diagnostic” when either: 1.) histologic review identified an intense lymphoplasmacytic infiltrate surrounding both pancreatic duct branches and venules, or 2.) IgG4 staining detected moderate (10–30 cells/hpf) or severe (> 30 cells/hpf) staining of plasma cells. The findings of TCB were considered “strongly suggestive” when either: 1.) histologic review identified an intense lymphoplasmacytic infiltrate without focal involvement of the pancreatic duct branches and venules, or 2.) IgG4 staining detected mild (< 10 cells/hpf) staining of plasma cells. Using these criteria, TCB specimens were considered “diagnostic” or “strongly suggestive” in 8/14 and 4/14 patients, respectively. (Fig. 1) Histology revealed only nonspecific changes of chronic pancreatitis in two patients, despite acquisition of an adequate specimen. EUS FNA was performed in 10 of the 14 patients and although adequate material was obtained, the findings were interpreted as normal pancreatic tissue with no pathology identified in either patient. Other than mild transient abdominal pain (n = 1) no complications were identified.

The inability to exclude malignancy led to initial consideration of pancreatic resection. EUS TCB findings alone led to histologic confirmation of AIP thereby obviating the need for resection in 8 patients. EUS TCB and pathologic examination revealed findings strongly suggestive of AIP in 4 patients that when considered along with the HISORT [Histology, Imaging, Serology, other Organ involvement, and Response to steroid therapy] criteria led to medical management. In two patients, although the EUS TCB was not diagnostic of AIP, it did demonstrate the non-specific finding of chronic pancreatitis. In the latter patients, other features were present that led to close observation and medical therapy. All patients were initially treated with Prednisone 40 mg/d for 3 months (1–5 months) with clinical resolution

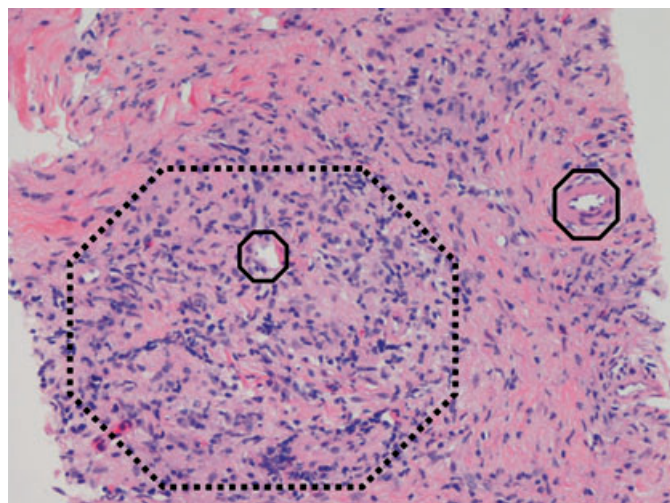


Fig. 1 Demonstration of an intact artery found at the right of the image. In addition, an intense infiltration by lymphocytes and histiocytes results in near complete obliteration of the vein shown at the left of the image.

and normalization of liver chemistries. Three patients are in the initial phase of steroid therapy. All patients have experienced a benign course without evidence of malignancy.

Discussion

Autoimmune pancreatitis is a rare but increasingly recognized disorder of unclear pathogenesis and pathophysiology. The term is applied to patients presenting with pancreatic manifestations of what is now recognized as a systemic disorder. AIP is otherwise referred to as chronic inflammatory sclerosis of the pancreas, sclerosing pancreatitis, pancreatitis showing the narrowing appearance of the pancreatic duct (PNPD), sclerosing pancreatochoolangitis, duct destructive chronic pancreatitis, and lymphoplasmacytic sclerosing pancreatitis. Although most patients are between 55–60 years at the time of diagnosis, the diagnosis may be made at the age extremes [63,64]. There is a male predominance (2:1) except when the disease is associated with other autoimmune disorders [63,64].

Prospectively evaluated criteria do not exist for establishing the presence of AIP and most rely on a combination of clinical, laboratory, and imaging findings to make the diagnosis [63–66]. Two classification schemes have been established that rely on a spectrum of findings to establish the diagnosis. The Japanese Pancreas Society established the first set of criteria (Table 1) that in order to diagnose AIP requires: 1) diffuse pancreatic enlargement, and 2) diffuse, irregular main pancreatic duct narrowing. Diagnosis also requires any of the following: 1.) increased immunoglobulin G (IgG) level, 2.) presence of autoantibodies (antinuclear antibody or rheumatoid factor), and/or 3.) fibrosis and lymphoplasmacytic infiltration within tissue specimens.

Creation of the Japanese criteria was an important step in the diagnosis and management of patients with AIP. However, adoption of their criteria requires performance of sometimes unnecessary interventions such as mandatory pancreatography. Also, evolving or new discoveries such as diagnostic histologic criteria [65], atypical imaging findings [67], specific elevation of IgG4 subclass [68], other organ involvement [69] and response to steroids [70] are not considered by the Japanese criteria. Therefore, their criteria are insufficient to recognize the full disease spectrum thereby limiting diagnostic sensitivity. These limitations led Chari and colleagues [66] to establish the HISORT Criteria that rely on Histology, Imaging, Serology, other Organ involvement, and Response to steroid therapy. Incorporation of these criteria into a diagnostic algorithm has been shown to enhance diagnostic sensitivity without sacrificing specificity.

There are growing data supporting the utility of EUS imaging and tissue acquisition for addressing these new criteria to aid AIP di-

Table 1 Japanese Pancreas Society Criteria for Autoimmune Pancreatitis

1. Diffuse pancreatic enlargement
2. Diffusely irregular MPD narrowing
3. Increased IgG (total)
4. Autoantibodies (antinuclear antibody or rheumatoid factor)

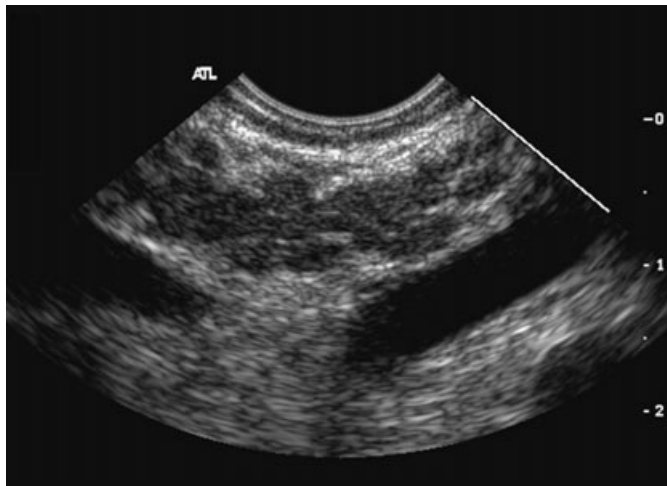


Fig. 2 Characteristic endoscopic ultrasound finding of autoimmune pancreatitis demonstrating diffuse (sausage-shape) pancreatic enlargement with a hypoechoic, coarse, patchy, heterogeneous appearance.

agnosis [32,62]. The most characteristic EUS finding is diffuse (sausage-shape) pancreatic enlargement with a hypoechoic, coarse, patchy, heterogeneous appearance. (Fig. 2) However, there may be significant overlap between the appearance of AIP and other pancreatic disorders. EUS may also reveal an isolated or multiple mass lesions that can mimic “unresectable” ductal carcinoma. Other less common EUS features include glandular atrophy, calcification, cystic spaces, features of non-specific chronic pancreatitis, or even a normal gland. Unfortunately, there are no pathognomonic EUS findings for AIP. Furthermore, while there are a few characteristic features of AIP, none have proven useful in isolation to diagnose AIP and presence in other pancreatic disorders is common. The lack of pathognomonic features and diverse spectrum of EUS findings limits the utility of EUS imaging alone. This has driven the pursuit of safe methods for obtaining tissue to enhance diagnostic accuracy.

Diagnostic uncertainty often exists, in particular for patients with “tumefactive” autoimmune pancreatitis in which the disease is manifest by a mass-like lesion that may lead to biliary obstruction when in the pancreatic head and can be mistaken for pancreatic cancer [71–73]. As a result, many patients undergo unnecessary surgical intervention for a benign lesion that tends to have a fluctuating course often with complete resolution of all manifestations, including jaundice, with or without immunosuppressive therapy as demonstrated in our series [64,70]. In addition, even in patients in whom the diagnosis of AIP can confidently be made without surgery, the natural history and ideal timing of immunosuppressive therapy are uncertain. As a result, new diagnostic modalities are needed that allow safe and accurate diagnosis and monitoring of AIP. The recently introduced EUS TCB device may satisfy these requirements.

There are few data concerning the use of EUS FNA for establishing the diagnosis of AIP and most consider FNA and cytology inadequate for diagnosis. While cytologic specimens can be examined for lymphocytes and plasma cells, their presence in other disorders limits specificity risking mismanagement of an unrecognized pancreatic carcinoma. Tissue samples collected via

Table 2 HISORT Criteria for Autoimmune Pancreatitis

Category	Criteria
A. Histology	1. Diagnostic (any one): a) Pancreatic histology showing periductal lymphoplasmacytic infiltrate with obliterative phlebitis (LPSP) b) Lymphoplasmacytic infiltrate with abundant (> 10 cells/hpf) IgG4 positive cells in the pancreas 2. Supportive (any one) a) Lymphoplasmacytic infiltrate with abundant (> 10 cells/hpf) IgG4 positive cells in involved extra-pancreatic organ b) Lymphoplasmacytic infiltrate with fibrosis in the pancreas
B. Imaging	Typical imaging features: 1. CT/MR: diffusely enlarged gland with delayed (rim) enhancement 2. ERCP: Diffusely irregular, attenuated main pancreatic duct Atypical Imaging Features*: Pancreatitis, focal pancreatic mass, focal pancreatic duct stricture, pancreatic atrophy, pancreatic calcification
C. Serology	Elevated serum IgG4 level (normal 8–140 mg/dl)
D. Other Organ involvement#	Hilar/intrahepatic biliary strictures, persistent distal biliary stricture, Parotid/lacrimal gland involvement, Mediastinal lymphadenopathy, Retroperitoneal fibrosis
E. Response to steroid therapy	Resolution/marked improvement of pancreatic/extrapancreatic manifestation with steroid therapy

FNA lack preservation of tissue architecture which most pathologists consider necessary for diagnosis.

In our experience, in none of the 9 patients undergoing EUS FNA was the diagnosis of AIP possible with FNA alone. However, in the 14 patients in whom tissue was acquired with EUS TCB, histologic review and/or IgG4 immunostaining was diagnostic (n = 8), strongly suggestive (n = 4), or revealed nonspecific features of chronic pancreatitis (n = 2). For each of the patients, including the patients with only nonspecific findings of chronic pancreatitis, the results of the EUS TCB altered the planned management. Patients underwent medical therapy with corticosteroid administration and were spared surgical intervention.

Summary

The lack of pathognomonic imaging features, considerable variation in pancreatic imaging, and diverse spectrum of clinical disease highlight the need for safe measures for acquiring core tissue specimens to enhance the diagnostic accuracy of AIP. Our initial experience supports the assumption that tissue obtained with EUS TCB is sufficient to allow adequate histologic review to diagnose AIP. The findings are useful in guiding management and may prevent misdiagnosis of pancreatic carcinoma risking lost opportunity for potentially curative resection while avoiding unnecessary surgical interventions for those with AIP. While these findings clearly indicate the ability of EUS TCB to establish the diagnosis of AIP, the limited number of patients evaluated prohibits any determination of sensitivity, specificity or safety in this setting.

We favor EUS TCB for patients with a compatible clinical presentation in whom there is diagnostic uncertainty when the finds are likely to alter management. However, future study is needed in

this cohort of patients to establish the: 1) performance characteristics of EUS and tissue sampling and intraductal ultrasound, 2) safety of EUS guided tissue sampling and intraductal ultrasound, and the 3) possible role of ultrasound contrast and power Doppler.

References

- 1 Koito K et al. Inflammatory pancreatic masses: differentiation from ductal carcinomas with contrast-enhanced sonography using carbon dioxide microbubbles. *Am J Roentgenol* 1997; 169 (5): 1263–1267
- 2 Becker D et al. Echo-enhanced color- and power-Doppler EUS for the discrimination between focal pancreatitis and pancreatic carcinoma. *Gastrointestinal Endoscopy* 2001; 53 (7): 784–789
- 3 Norton ID et al. Neural network analysis of EUS images to differentiate between pancreatic malignancy and pancreatitis. *Gastrointestinal Endoscopy* 2001; 54: 625–629
- 4 Snady H, Cooperman A, Siegel J. Endoscopic ultrasonography compared with computed tomography with ERCP in patients with obstructive jaundice or small peri-pancreatic mass. *Gastrointestinal Endoscopy* 1992; 38 (1): 27–34
- 5 Muller MF et al. Pancreatic tumors: evaluation with endoscopic US, CT, and MR imaging. *Radiology*, 1994; 190 (3): 745–751
- 6 Akahoshi K et al. Diagnosis and staging of pancreatic cancer by endoscopic ultrasound. *British Journal of Radiology* 1998; 71 (845): 492–496
- 7 Wiersema MJ et al. Endosonography-guided fine-needle aspiration biopsy: diagnostic accuracy and complication assessment. *Gastroenterology* 1997; 112 (4): 1087–1095
- 8 Suits J, Frazee R, Erickson RA. Endoscopic ultrasound and fine needle aspiration for the evaluation of pancreatic masses. *Archives of Surgery* 1999; 134 (6): 639–42; discussion 642–643
- 9 Williams DB et al. Endoscopic ultrasound guided fine needle aspiration biopsy: a large single centre experience. *Gut* 1999; 44 (5): 720–726
- 10 Varadarajulu S, Tamhane A, Eloubeidi MA. Yield of EUS-guided FNA of pancreatic masses in the presence or the absence of chronic pancreatitis.[see comment]. *Gastrointestinal Endoscopy* 2005; 62 (5): 728–736; quiz 751
- 11 Gress F et al. EUS-guided fine-needle aspiration of the pancreas: evaluation of pancreatitis as a complication. *Gastrointestinal Endoscopy* 2002; 56 (6): 864–867
- 12 Harewood GC, Wiersema MJ. Endosonography-guided fine needle aspiration biopsy in the evaluation of pancreatic masses. *American Journal of Gastroenterology* 2002; 97 (6): 1386–1391
- 13 tenBerge J et al. EUS-guided fine needle aspiration of the liver: indications, yield, and safety based on an international survey of 167 cases. *Gastrointestinal Endoscopy* 2002; 55 (7): 859–862
- 14 Chang KJ et al. The clinical utility of endoscopic ultrasound-guided fine-needle aspiration in the diagnosis and staging of pancreatic carcinoma. *Gastrointestinal Endoscopy* 1997; 45 (5): 387–393
- 15 Chang KJ et al. Endoscopic ultrasound-guided fine-needle aspiration. *Gastrointestinal Endoscopy* 1994; 40 (6): 694–699
- 16 Gress FG et al. Endoscopic ultrasound-guided fine-needle aspiration biopsy using linear array and radial scanning endosonography. *Gastrointestinal Endoscopy* 1997; 45 (3): 243–250
- 17 Warshaw AL. Implications of peritoneal cytology for staging of early pancreatic cancer. *American Journal of Surgery* 1991; 161 (1): 26–29; discussion 29–30
- 18 Paquin SC et al. A first report of tumor seeding because of EUS-guided FNA of a pancreatic adenocarcinoma. *Gastrointestinal Endoscopy* 2005; 61 (4): 610–611
- 19 Faigel DO et al. Endoscopic ultrasound-guided real-time fine-needle aspiration biopsy of the pancreas in cancer patients with pancreatic lesions. *Journal of Clinical Oncology* 1997; 15 (4): 1439–1443
- 20 Cappell MS et al. Lymphoma predominantly involving the pancreas. *Digestive Diseases & Sciences* 1989; 34 (6): 942–947
- 21 Namieno T et al. Diagnostic features on images in primary small cell carcinoma of the pancreas. *American Journal of Gastroenterology* 1997; 92 (2): 319–322
- 22 van Gulik TM et al. Incidence and clinical findings of benign, inflammatory disease in patients resected for presumed pancreatic head cancer.[see comment]. *Gastrointestinal Endoscopy* 1997; 46 (5): 417–423
- 23 Erickson RA, Sayage-Rabie L, Beissner RS. Factors predicting the number of EUS-guided fine-needle passes for diagnosis of pancreatic malignancies. *Gastrointestinal Endoscopy* 2000; 51 (2): 184–190
- 24 Chang KJ. Maximizing the yield of EUS-guided fine-needle aspiration. *Gastrointestinal Endoscopy* 2002; 56 (4 Suppl): S28–34
- 25 Prasad P et al. Detection of occult liver metastases during EUS for staging of malignancies. *Gastrointestinal Endoscopy* 2004; 59 (1): 49–53
- 26 Hahn M, Faigel DO. Frequency of mediastinal lymph node metastases in patients undergoing EUS evaluation of pancreaticobiliary masses. *Gastrointestinal Endoscopy* 2001; 54 (3): 331–335
- 27 Binmoeller KF, Rathod VD. Difficult pancreatic mass FNA: tips for success. *Gastrointestinal Endoscopy* 2002; 56 (4 Suppl): S86–91
- 28 Afify AM et al. Endoscopic ultrasound-guided fine needle aspiration of the pancreas. Diagnostic utility and accuracy. *Acta Cytologica* 2003; 47 (3): 341–348
- 29 Binmoeller KF et al. Endoscopic ultrasound-guided, 18-gauge, fine needle aspiration biopsy of the pancreas using a 2.8 mm channel convex array echoendoscope. *Gastrointestinal Endoscopy* 1998; 47 (2): 121–127
- 30 Levy MJ et al. Preliminary experience with an EUS-guided trucut biopsy needle compared with EUS-guided FNA. *Gastrointestinal Endoscopy* 2003; 57 (1): 101–106
- 31 Levy MJ et al. Comparison of endoscopic ultrasound-guided trucut biopsy (EUS-TCB) to endoscopic ultrasound-guided fine needle aspiration (EUS-FNA) (Abstract W1228). *Gastrointestinal Endoscopy* 2003; 57 (5): AB244
- 32 Levy MJ et al. EUS-guided trucut biopsy in establishing autoimmune pancreatitis as the cause of obstructive jaundice. *Gastrointestinal Endoscopy* 2005; 61 (3): 467–472
- 33 Ebert M, Schandl L, Schmid RM. Differentiation of chronic pancreatitis from pancreatic cancer: recent advances in molecular diagnosis. *Digestive Diseases* 2001; 19 (1): 32–36
- 34 Pugliese V et al. Pancreatic intraductal sampling during ERCP in patients with chronic pancreatitis and pancreatic cancer: cytologic studies and k-ras-2 codon 12 molecular analysis in 47 cases. *Gastrointestinal Endoscopy* 2001; 54 (4): 595–599
- 35 Myung SJ et al. Telomerase activity in pure pancreatic juice for the diagnosis of pancreatic cancer may be complementary to K-ras mutation. *Gastrointestinal Endoscopy* 2000; 51 (6): 708–713
- 36 Takahashi K et al. Differential diagnosis of pancreatic cancer and focal pancreatitis by using EUS-guided FNA. *Gastrointestinal Endoscopy* 2005; 61 (1): 76–79
- 37 Chhieng DC et al. MUC1 and MUC2 expression in pancreatic ductal carcinoma obtained by fine-needle aspiration. *Cancer* 2003; 99 (6): 365–371
- 38 Levy MJ et al. Prospective evaluation of digital image analysis (DIA) and fluorescence in situ hybridization (FISH) during EUS and ERCP. *Gastrointestinal Endoscopy* 2005; 61 (5): A289
- 39 Ribeiro A et al. EUS-guided fine-needle aspiration combined with flow cytometry and immunocytochemistry in the diagnosis of lymphoma. *Gastrointestinal Endoscopy* 2001; 53 (4): 485–491
- 40 Piccinino F et al. Complications following percutaneous liver biopsy. A multicentre retrospective study on 68,276 biopsies. *Journal of Hepatology* 1986; 2 (2): 165–173
- 41 Kovalik EC et al. No change in complication rate using spring-loaded gun compared to traditional percutaneous renal allograft biopsy techniques. *Clinical Nephrology* 1996; 45 (6): 383–385
- 42 Brandt KR et al. CT- and US-guided biopsy of the pancreas. *Radiology* 1993; 187 (1): 99–104
- 43 Welch TJ et al. CT-guided biopsy: prospective analysis of 1,000 procedures. *Radiology* 1989; 171 (2): 493–496
- 44 Harrison BD et al. Percutaneous Trucut lung biopsy in the diagnosis of localised pulmonary lesions. *Thorax* 1984; 39 (7): 493–499
- 45 Ingram DM, Sheiner HJ, Shilkin KB. Operative biopsy of the pancreas using the Trucut needle. *Australian & New Zealand Journal of Surgery* 1978; 48 (2): 203–206
- 46 Lavelle MA, O'Toole A. Trucut biopsy of the prostate. *British Journal of Urology* 1994; 73 (5): 600
- 47 Ball AB et al. Diagnosis of soft tissue tumours by Tru-Cut biopsy. *British Journal of Surgery* 1990; 77 (7): 756–758
- 48 Zinzani PL et al. Ultrasound-guided core-needle biopsy is effective in the initial diagnosis of lymphoma patients. *Haematologica* 1998; 83 (11): 989–992

- ⁴⁹ Hatada T et al. Diagnostic value of ultrasound-guided fine-needle aspiration biopsy, core-needle biopsy, and evaluation of combined use in the diagnosis of breast lesions. *Journal of the American College of Surgeons* 2000; 190 (3): 299–303
- ⁵⁰ Radhakrishnan V. Transrectal Tru-cut biopsy of the prostate using a protective sheath. *British Journal of Urology* 1994; 73 (4): 454
- ⁵¹ Rodriguez LV, Terris MK. Risks and complications of transrectal ultrasound guided prostate needle biopsy: a prospective study and review of the literature. *Journal of Urology* 1998; 160 (6 Pt 1): 2115–2120
- ⁵² Durup Scheel-Hincke J et al. Laparoscopic four-way ultrasound probe with histologic biopsy facility using a flexible tru-cut needle. *Surgical Endoscopy* 2000; 14 (9): 867–869
- ⁵³ Indinnimeo M et al. Trans anal full thickness tru-cut needle biopsies in anal canal tumors after conservative treatment. *Oncology Reports* 1998; 5 (2): 325–327
- ⁵⁴ Sada PN et al. Transjugular liver biopsy: a comparison of aspiration and trucut techniques. *Liver* 1997; 17 (5): 257–259
- ⁵⁵ Chau TN et al. Transjugular liver biopsy with an automated trucut-type needle: comparative study with percutaneous liver biopsy. *European Journal of Gastroenterology & Hepatology* 2002; 14 (1): 19–24
- ⁵⁶ Tweedle DE. Peroperative transduodenal biopsy of the pancreas. *Gut* 1979; 20 (11): 992–996
- ⁵⁷ Johnson CD et al. Cystic pancreatic tumors: CT and sonographic assessment. *AJR. American Journal of Roentgenology* 1988; 151 (6): 1133–1138
- ⁵⁸ Nyman RS et al. Yield and complications in ultrasound-guided biopsy of abdominal lesions. Comparison of fine-needle aspiration biopsy and 1.2-mm needle core biopsy using an automated biopsy gun. *Acta Radiologica* 1995; 36 (5): 485–490
- ⁵⁹ Bocking A et al. Cytologic versus histologic evaluation of needle biopsy of the lung, hilum and mediastinum. Sensitivity, specificity and typing accuracy. *Acta Cytologica* 1995; 39 (3): 463–471
- ⁶⁰ Wiersema MJ et al. Initial experience with EUS-guided trucut needle biopsies of perigastric organs. *Gastrointestinal Endoscopy* 2002; 56 (2): 275–278
- ⁶¹ Levy MJ et al. Preliminary experience with an EUS-guided trucut biopsy needle compared with EUS-guided FNA. *Gastrointestinal Endoscopy* 2003; 57: 101–106
- ⁶² Zhang L et al. Pancreatic IgG4 stain for diagnosing autoimmune pancreatitis (AIP) and for distinguishing AIP subtypes. *Gastroenterology* 2005; 128: A474
- ⁶³ Pearson RK et al. Controversies in clinical pancreatology: autoimmune pancreatitis: does it exist. *Pancreas* 2003; 27 (1): 1–13
- ⁶⁴ Okazaki K, Chiba T. Autoimmune related pancreatitis. *Gut* 2002; 51 (1): 1–4
- ⁶⁵ Kloppel G et al. Autoimmune pancreatitis: pathological, clinical, and immunological features. *Pancreas* 2003; 27 (1): 14–19
- ⁶⁶ Chari ST et al. Autoimmune pancreatitis: diagnosis using histology, imaging, serology, other organ involvement and response to steroids. 2006 p. Pending Publication
- ⁶⁷ Wakabayashi T et al. Clinical and imaging features of autoimmune pancreatitis with focal pancreatic swelling or mass formation: comparison with so-called tumor-forming pancreatitis and pancreatic carcinoma. *American Journal of Gastroenterology* 2003; 98 (12): 2679–2687
- ⁶⁸ Hamano H et al. High serum IgG4 concentrations in patients with sclerosing pancreatitis.[see comment]. *New England Journal of Medicine* 2001; 344 (10): 732–738
- ⁶⁹ Kamisawa T, Egawa N, Nakajima H. Autoimmune pancreatitis is a systemic autoimmune disease. *American Journal of Gastroenterology* 2003; 98 (12): 2811–2812
- ⁷⁰ Kojima E et al. Autoimmune pancreatitis and multiple bile duct strictures treated effectively with steroid. *Journal of Gastroenterology* 2003; 38 (6): 603–607
- ⁷¹ Yadav D et al. Idiopathic tumefactive chronic pancreatitis: clinical profile, histology, and natural history after resection. *Clinical Gastroenterology & Hepatology* 2003; 1 (2): 129–135
- ⁷² Kamisawa T et al. Clinical difficulties in the differentiation of autoimmune pancreatitis and pancreatic carcinoma. *American Journal of Gastroenterology* 2003; 98 (12): 2694–2699
- ⁷³ Taniguchi T et al. Autoimmune pancreatitis detected as a mass in the head of the pancreas without hypergammaglobulinemia, which relapsed after surgery: case report and review of the literature. *Digestive Diseases & Sciences* 2003; 48 (8): 1465–1471