

Colonoscopy was performed in a 65-year-old man for the investigation of obscure gastrointestinal blood loss. A 7-mm sessile polyp was found 40 cm above the anus. During polypectomy the patient noticed a short sensation in his bowels. Because the endoscopic aspect of the very small polypectomy site seemed deeper than normal, two clips were positioned over the polypectomy site in the same session. Some 30 minutes after completion of the procedure, the patient noticed swelling of his scrotum (Figure 1). A plain abdominal radiograph showed free abdominal air and subcutaneous emphysema (Figure 2). The subcutaneous emphysema increased further over the next few hours, so it was decided to perform a laparotomy.

During laparotomy, the surgeon was guided by intraoperative endoscopy to the site in the middle of the descending colon where the clips had been positioned. Leakiness of the colon was tested by inflating air into the colon while the surgeon was inspecting the colon, which was submerged in saline solution. No air bubbles could be seen and the procedure was finished without any "repair" of the colon. The patient made an uneventful recovery.

Pneumoscrotum has been described as a rare complication of endoscopic procedures such as esophagoscopy, gastroscopy, endoscopic retrograde cholangiopancreatography, and colonoscopy. Pneumoscrotum occasionally occurs following retroperitoneal perforation and can also be combined with intraperitoneal air leakage. In all five cases of pneumoscrotum occurring after colonoscopy that have been reported in the literature, the patients were managed conservatively [1–5]. Because of the considerable increase in the amount of subcutaneous emphysema in this patient, we decided to operate, but this turned out to be an unnecessary procedure. The immediate closure of the defect with endoscopic clip placement might in fact have been the essential procedure in this patient. Reallo-

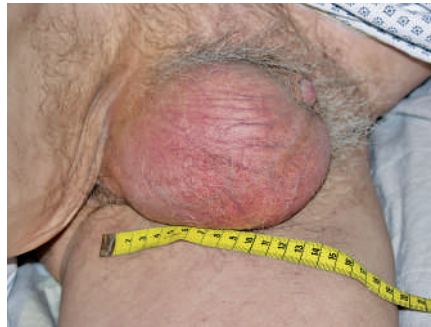


Figure 1 Pneumoscrotum 1 hour after the colonoscopic polypectomy.

cation of air from the peritoneal cavity to the subcutaneous tissue might have contributed to the increase in emphysema.

Endoscopy\_UCTN\_Code\_CPL\_1AJ\_2AC

**F. Graepler<sup>1</sup>, U. M. Lauer<sup>1</sup>, M. S. Horger<sup>2</sup>, R. Ladurner<sup>3</sup>, M. Gregor<sup>1</sup>**

<sup>1</sup> Department of Internal Medicine I, University Hospital Tübingen, Tübingen, Germany

<sup>2</sup> Department of Radiology, University Hospital Tübingen, Tübingen, Germany

<sup>3</sup> Department of Surgery, University Hospital Tübingen, Tübingen, Germany.

## References

- 1 Fishman EK, Goldman SM. Pneumoscrotum after colonoscopy. *Urology* 1981; 18: 171–172
- 2 Humphreys F, Hewetson KA, Dellipiani AW. Massive subcutaneous emphysema following colonoscopy. *Endoscopy* 1984; 16: 160–161
- 3 Carlsen CU, Andreassen KH. Benign pneumoperitoneum and scrotal emphysema after colonoscopy. *Ugeskr Laeger* 1992; 154: 1785–1786
- 4 Goerg KJ, Duber C. Retroperitoneal, mediastinal and subcutaneous emphysema with pneumothorax after colonoscopy. *Dtsch Med Wochenschr* 1996; 121: 693–696
- 5 Fu KI, Sano Y, Kato S et al. Pneumoscrotum: a rare manifestation of perforation associated with therapeutic colonoscopy. *World J Gastroenterol* 2005; 11: 5061–5063

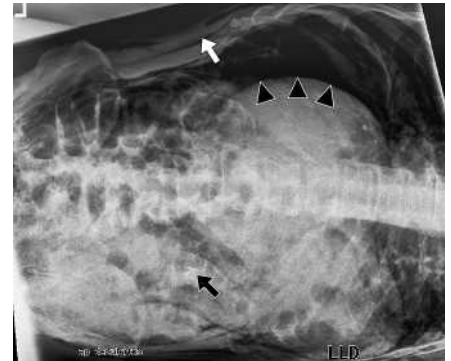


Figure 2 Abdominal radiograph taken in the left-lateral position 2 hours after polypectomy, showing two clips at the polypectomy site (black arrow), subcutaneous emphysema (white arrow), and intra-abdominal air between the left abdominal wall and the liver (arrowheads).

## Corresponding author

**F. Graepler, MD**

Department of Internal Medicine I  
University Hospital Tübingen  
Otfried-Müller-Str. 10  
D-72076 Tübingen  
Germany

Fax: +49-7071-29 4630

Email: florian.graepler@uni-tuebingen.de