

A 59-year-old woman with advanced cervical carcinoma presented to us with intractable vomiting, 8 weeks after receiving cisplatin chemotherapy. Upper gastrointestinal endoscopy revealed mild duodenitis and an obstructive adhesion in the distal duodenum (Figure 1). The adhesion was disrupted by the passage of the endoscope and the patient's symptoms promptly resolved.

Endoscopy_UCTN_Code_CCL_1AB_2AZ_3AC

M. Storr, B. Göke, H. M. Diepolder

Department of Medicine II,
Klinikum Grosshadern,
Ludwig-Maximilians-University of
Munich, Munich, Germany.

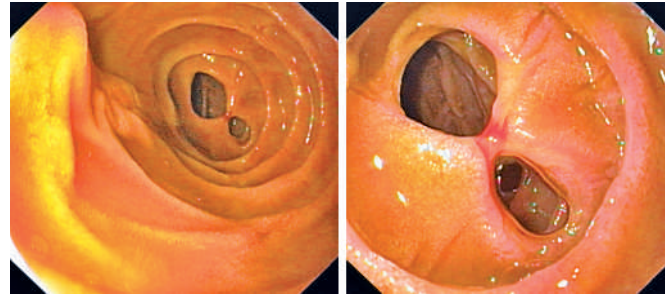


Figure 1 Endoscopic views of the obstructive duodenal adhesion at the distal end of the descending part of the duodenum that had formed secondary to duodenitis.

Corresponding Author

M. Storr, M.D.

Department of Medicine II
Klinikum Grosshadern
Ludwig-Maximilians-University of
Munich
Marchioninistraße 15
81377 Munich
Germany
Fax: +49-89-7095-5281
E-mail: martin.storr@med.
uni-muenchen.de