

Endoscopic ultrasound-guided Trucut needle biopsy (EUS-TNB) is new technique for evaluation and diagnosis of gastrointestinal stromal tumors [1–3]. We report here a patient who developed significant delayed-onset bleeding as a complication of EUS-TNB of a gastric stromal tumor.

A 50-year-old woman was referred to our hospital for evaluation of a 3-cm submucosal mass at the gastric cardia. Gastric endosonography performed using a curved linear-array echo endoscope (GF-UCT240; Olympus Optical Co., Tokyo, Japan) revealed a well-circumscribed, heterogenous, echo-poor mass, 30 mm × 26 mm in size, arising from the fourth sonographic layer. Two passes were made into the tumor with a 19-gauge Trucut needle (Quick-Core, Wilson-Cook, Winston-Salem, North Carolina, USA) to obtain a 9-mm-long tissue core (Figure 1). There was no immediate bleeding. Check endoscopy at 24 hours also did not reveal any local bleeding. The histopathological and immunohistochemical findings were consistent with a diagnosis of gastric stromal tumor.

Nine days later, the patient had developed tarry stools and her hemoglobin had dropped to 3.9 g/dl. She required transfusion of 8 units of packed red cells. Urgent endoscopy revealed arterial spurting from an ulcer overlying the submucosal tumor. Bleeding was stopped temporarily by clipping, but surgical resection was required subsequently. Histological examination of the resection specimen revealed a large-caliber artery in the submucosal layer near the ulcer, a picture analogous to rupture of a Dieulafoy lesion (Figure 2).

Until now, only one case of immediate bleeding after EUS-TNB of a gastrointestinal stromal tumor has been reported and in that patient hemostasis was achieved

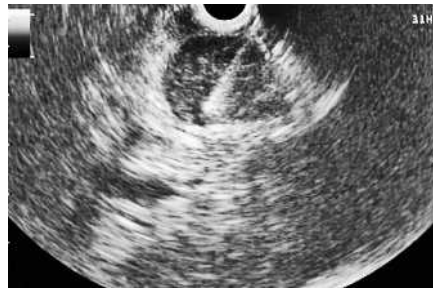

Figure 1 Endoscopic ultrasound image of the gastric stromal tumor, showing the Trucut needle after firing of the cutting sheath.

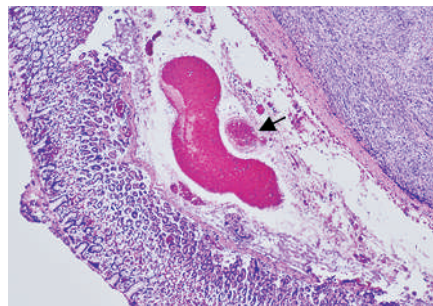


Figure 2 Histological view of the resection specimen. The arrow indicates a large-caliber artery in the submucosal layer near the ulcer (hematoxylin and eosin stain, × 200 magnification).

by epinephrine injection [3]. The EUS Trucut needle has a 20-mm tissue tray with an outer cutting sheath. In the EUS-TNB specimen we took from our patient, no atrophic changes were seen in the gastric epithelium obtained along with the tumor tissue. We speculate that a post-biopsy mucosal defect might have evolved into a deep ulcer in the acid-competent stomach, and that this led to delayed erosion of the underlying submucosal artery. Newer devices with a shorter needle length should be designed for such small lesions. The routine use of acid suppressant drugs after biopsy may also decrease the risk of delayed bleeding.

Endoscopy\_UCTN\_Code\_CPL\_1AL\_2AB

H. Inoue<sup>1</sup>, N. Mizuno<sup>1</sup>, A. Sawaki<sup>1</sup>, K. Takahashi<sup>1</sup>, M. Aoki<sup>1</sup>, V. Bhatia<sup>1</sup>, K. Matuura<sup>2</sup>, T. Tabata<sup>3</sup>, K. Yamao<sup>1</sup>

<sup>1</sup> Department of Gastroenterology, Aichi Cancer Center Hospital, Nagoya, Japan

<sup>2</sup> Department of Gastroenterology, Nagoya Red Cross Second Hospital, Nagoya, Japan

<sup>3</sup> Department of Surgery, Nagoya Red Cross Second Hospital, Nagoya, Japan.

## References

- 1 Yadav D, Levy MJ, Schwartz D et al. EUS-guided trucut biopsy for diagnosis of an esophageal stromal tumor: case report. *Gastrointest Endosc* 2003; 58: 457–460
- 2 Ribeiro A, Vernon S, Ouitela P. EUS-guided trucut biopsy with immunohistochemical analysis of a gastric stromal tumor. *Gastrointest Endosc* 2004; 60: 645–648
- 3 Varadarajulu S, Fraig M, Schmulewitz N et al. Comparison of EUS-guided 19-gauge Trucut needle biopsy with EUS-guided fine-needle aspiration. *Endoscopy* 2004; 36: 397–401

## Corresponding author

K. Yamao, M.D.

Department of Gastroenterology  
Aichi Cancer Center Hospital  
1-1 Kanokoden  
Chikusa-ku  
Nagoya 464-8681  
Japan

Fax: +81-052-7642967

E-mail: kyamao@aichi-cc.jp