

# Endoscopic ultrasound-guided rescue of an uncovered self-expanding metallic stent causing biliary obstruction

# UCTN

Removal of a malpositioned uncovered Wallstent (Boston Scientific, Natick, Massachusetts, USA) can be extremely difficult, time-consuming, and associated with the occurrence of complications [1]. Stent extraction using standard polypectomy snare or rat-tooth forceps is often unsuccessful [1]. Alternatively stent removal can be accomplished by piecemeal extraction of individual stent filaments [1–4]. We present a case in which drainage of the biliary system, obstructed by a Wallstent wedged to the hilum, was achieved by endoscopic ultrasound (EUS)-guided puncture of the left intrahepatic bile duct followed by rendezvous endoscopic retrograde cholangiography (ERC).

A 57-year-old man with metastatic cholangiocarcinoma, who had undergone a previous ERC with placement of an uncovered biliary Wallstent, was referred to us for evaluation of persistent jaundice (bilirubin 58 mg/dl). A repeat ERC showed complete occlusion of the Wallstent, with some contrast spilling into the right biliary system and complete obstruction of the left system (Figure 1 a).

After multiple unsuccessful attempts at advancing a guide wire through the stent, the duodenoscope was exchanged for a linear-array echo endoscope (Olympus America, Melville, New York, USA), that was used to identify the dilated bile ducts within the left hepatic lobe and to puncture them using a 19-gauge needle. After bile had been aspirated and contrast injected to opacify the biliary system, a 0.035-inch Jagwire (Boston Scientific) was inserted through the needle and advanced antegradely across the mesh of the Wallstent, the hilar stricture, and into the duodenum (Figure 1 b). A rendezvous ERC was finally performed, with placement of a 6 cm long, 6 mm wide Zilver stent (Wilson-Cook Medical, Winston-Salem, North Carolina, USA) through the meshes of the Wallstent (Figure 1 c). Serum bilirubin levels were completely normalized 10 weeks after the procedure.

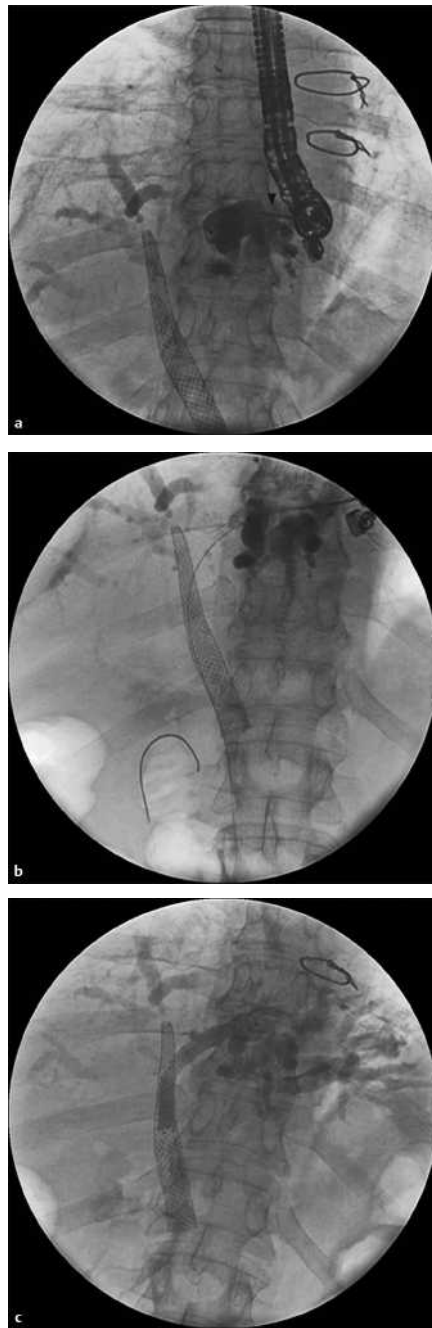


Figure 1 Fluoroscopic views of the procedure. **a** Endoscopic ultrasound (EUS)-guided transhepatic contrast injection with a 19-gauge needle (arrow), and the malpositioned uncovered Wallstent with its proximal end wedged into the hilum. **b** The guide wire was inserted from the left hepatic duct through the stent and into the duodenum. **c** The Zilver stent was placed through the mesh of the Wallstent.

We have reported here an illustrative case of EUS-guided rendezvous biliary drainage; this approach can be considered as a valid alternative to the percutaneous transhepatic route when a malpositioned SEMS, not amenable to endoscopic removal, is the cause of obstruction.

Endoscopy\_UCTN\_Code\_TTT\_1AR\_2AZ  
Endoscopy\_UCTN\_Code\_TTT\_1AS\_2AD  
Endoscopy\_UCTN\_Code\_CPL\_1AK\_2AD

## A. Larghi, I. Waxman

Section of Endoscopy and Therapeutics and the Cancer Research Center, The University of Chicago, Chicago, Illinois, USA.

## References

- 1 Kahaleh M, Tokar J, Le T et al. Removal of self-expandable metallic Wallstents. *Gastrointest Endosc* 2004; 60: 640–644
- 2 Ahmed A, Keeffe EB, Imperial JC. A novel technique for endoscopic removal of expandable biliary Wallstent. *Gastrointest Endosc* 1999; 50: 279–281
- 3 Egan LJ, Baron TH. Endoscopic removal of an embedded biliary Wallstent by piecemeal extraction. *Endoscopy* 2000; 32: 492–494
- 4 Levy MJ, Wiersema MJ. Endoscopic removal of a biliary Wallstent with a suture-cutting device in a patient with primary pancreatic lymphoma. *Endoscopy* 2002; 34: 835–837

## Corresponding author

### I. Waxman, M.D.

The University of Chicago  
Section of Gastroenterology  
5758 S. Maryland Avenue, MC 9028  
Chicago, Illinois 60637  
Fax: +1-773-834-7209  
E-mail: iwaxman@medicine.bsd.uchicago.edu

Published online: 2006  
DOI: 10.1055/s-2006-944653