

# Embedded mummified hookworm as a cause of bleeding from the duodenal bulb

# UCTN

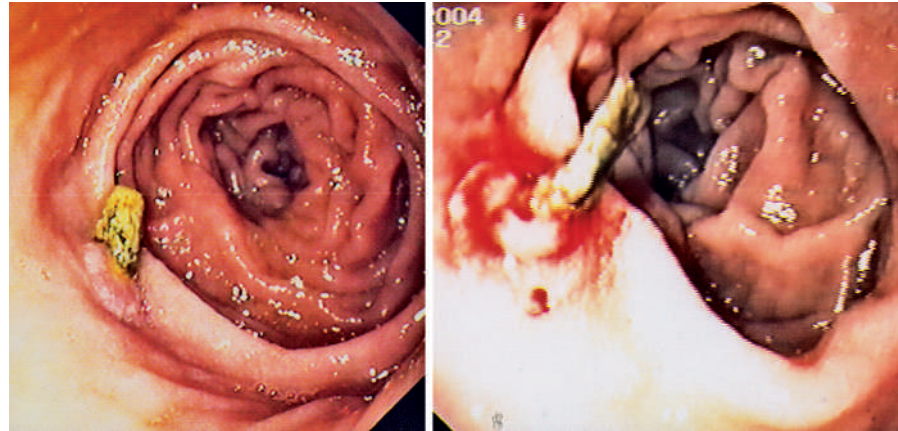


Figure 1 An 81-year-old man underwent esophagogastroduodenoscopy to investigate iron-deficiency anemia. A speculum-like foreign body, embedded in a mucosal protuberance, was seen in the duodenal bulb. The inner margin of the polyp-like lesion was ulcerated. The whole lesion was removed using a polypectomy snare (Video 1).

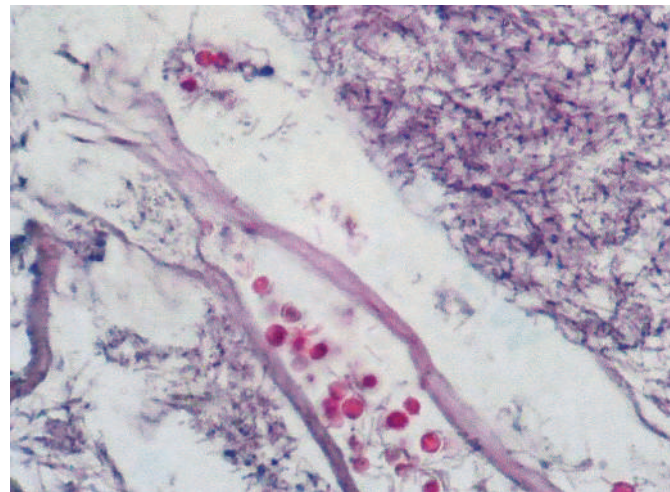


Figure 2 Histopathological examination showed this lesion to be a mummified female hookworm (*Ancylostoma duodenale*), containing numerous eggs, though the original tissue formation of the worm was not detectable. No hookworm eggs were detected in the stool.

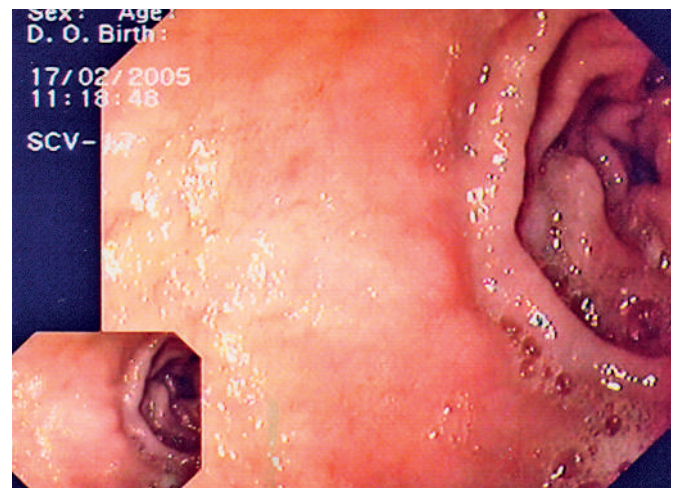


Figure 3 Endoscopy 4 months later showed normal duodenal mucosa. We suggest that this represented a late complication of previous hookworm infection, with the lifeless and mummified remnant of the hookworm causing chronic mucosal injury with bleeding ulceration. Endoscopic removal of the unusual structure resulted in complete mucosal and clinical recovery.

I. Rácz<sup>1</sup>, A. Szabó<sup>1</sup>, M. Goda<sup>2</sup>, É. Magyar<sup>3</sup>

<sup>1</sup> Department of Gastroenterology, Petz Aladár County and Teaching Hospital, Győr, Hungary

<sup>2</sup> Department of Pathology, Petz Aladár County and Teaching Hospital, Győr, Hungary

<sup>3</sup> Department of Pathology, Central National Medical Institute, Budapest, Hungary

Endoscopy\_UCTN\_Code\_CCL\_1AB\_2AZ\_3AZ

Video

online content including video sequences viewable at:

[www.thieme-connect.de/ejournals/abstract/endoscopy/doi/10.1055/s-2006-944652](http://www.thieme-connect.de/ejournals/abstract/endoscopy/doi/10.1055/s-2006-944652)

DOI: 10.1055/s-2006-944652