

Peutz–Jeghers syndrome is a rare autosomal dominant disease that is characterized by hamartomatous gastrointestinal polyposis and mucocutaneous pigmentation [1]. One report proposed that solitary Peutz–Jeghers-type hamartomatous polyps in patients with no other features of Peutz–Jeghers syndrome were likely to represent a separate disease entity from classic Peutz–Jeghers syndrome [2]. The solitary Peutz–Jeghers-type hamartoma of the duodenum is extremely rare in comparison with Peutz–Jeghers syndrome. We describe two such cases.

Patient 1 was an 87-year-old Japanese woman. She presented at our hospital complaining of epigastric discomfort. Upper gastrointestinal endoscopy revealed a pedunculated polyp, 1.8 cm in diameter and with a long stalk, in the second portion of the duodenum (Figure 1). Patient 2 was a 56-year-old Japanese man. He was noted to have a high serum level of carcinoembryonic antigen. Upper gastrointestinal endoscopy was performed to screen for gastrointestinal malignancy, and this examination revealed a pedunculated and lobulated polyp in the second portion of the duodenum, 1.2 cm in diameter (Figure 2).

Neither patient showed cutaneous pigmentation and we found no other gastrointestinal polyps on colonoscopy or on small-bowel follow-through examination in either patient; both patients had an unremarkable familial medical history. The surface of these polyps was normal in colour. Biopsy specimens revealed normal duodenal mucosa in both cases. These polyps were resected by endoscopic polypectomy. Histologically, both the polyps consisted of branching bundles of smooth-muscle fibers covered by hyperplastic duodenal mucosa (Figure 3).

We only found eight well-documented cases of solitary Peutz–Jeghers-type hamartoma of the duodenum in a review of the English-language literature [2–5]. The features we describe are characteris-

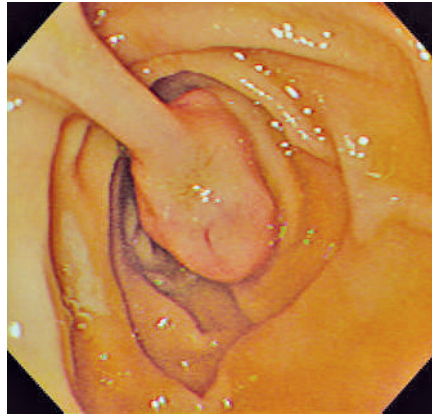


Figure 1 Upper gastrointestinal endoscopy in patient 1 revealed a pedunculated polyp with a long stalk in the second portion of the duodenum.

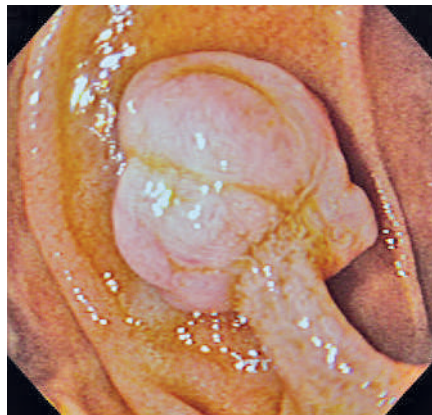

Figure 2 Upper gastrointestinal endoscopy in patient 2 revealed a pedunculated and lobulated polyp in the second portion of the duodenum.

tic of a Peutz–Jeghers polyp. The possibility of a solitary Peutz–Jeghers-type hamartoma should be considered in the differential diagnosis of a duodenal polyp.

Endoscopy\_UCTN\_Code\_CCL\_1AB\_2AZ\_3AB

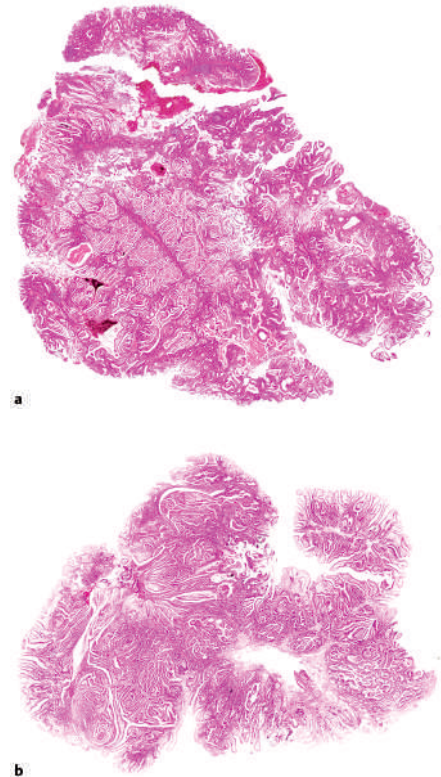


Figure 3 A low-power view of the resected duodenal polyp from patient 1 (a) and a similar view of the polyp from patient 2 (b), showing branching bundles of smooth-muscle fibers covered by hyperplastic duodenal mucosa in both cases (hematoxylin & eosin stain).

S. Itaba<sup>1</sup>, M. Namoto<sup>1</sup>, S. Somada<sup>1</sup>, K. Nakamura<sup>2</sup>, Y. Kumashiro<sup>3</sup>, N. Nakamura<sup>3</sup>, T. Yao<sup>3</sup>

<sup>1</sup> Department of Gastroenterology, Beppu Medical Center, Beppu, Oita, Japan

<sup>2</sup> Department of Medicine and Bioregulatory Science, Graduate School of Medical Sciences, Kyushu University, Fukuoka, Japan

<sup>3</sup> Department of Anatomic Pathology, Graduate School of Medical Sciences, Kyushu University, Fukuoka, Japan.

## References

- <sup>1</sup> Jeghers H, McKusick VA, Katz KH. Generalized intestinal polyposis and melanin spots of the oral mucosa, lips, and digits. *N Engl J Med* 1949; 241: 993–1005
- <sup>2</sup> Acea Nebril B, Taboada Filgueira L, Parajo Calvo A et al. Solitary hamartomatous duodenal polyp; a different entity: report of a case and review of the literature. *Surg Today* 1993; 23: 1074–1077
- <sup>3</sup> Ichiyoshi Y, Yao T, Nagasaki S et al. Solitary Peutz–Jeghers type polyp of the duodenum containing a focus of adenocarcinoma. *Ital J Gastroenterol* 1996; 28: 95–97
- <sup>4</sup> Oncel M, Remzi FH, Church JM et al. Course and follow up of solitary Peutz–Jeghers polyps: a case series. *Int J Colorect Dis* 2003; 18: 33–35
- <sup>5</sup> Kitaoka F, Shiogama T, Mizutani A et al. A solitary Peutz–Jeghers-type hamartomatous polyp in the duodenum: a case report including results of mutation analysis. *Digestion* 2004; 69: 79–82

## Corresponding author

### **K. Nakamura, M. D.**

Department of Medicine and  
Bioregulatory Science  
Graduate School of Medical Sciences  
Kyushu University  
Fukuoka 812-8582  
Japan  
Fax: +81-92-642-5287  
E-mail: knakamur@intmed3.med.  
kyushu-u.ac.jp