

Figure 1 Computed tomograms from patient 1 (a) and patient 2 (b), showing the pancreatic cysts.

Cystic lymphangioma of the pancreas is a rare, benign neoplasm classically diagnosed at surgery. We report here on two patients diagnosed using endoscopic ultrasound-guided fine-needle aspiration (EUS-FNA).

A 70-year-old man and a 63-year-old woman both underwent computed tomography (CT) scans for evaluation of nonspecific abdominal complaints. The physical examination and laboratory evaluation were unremarkable in both. The CT scans revealed a 4.6-cm cystic lesion in the head of the pancreas in the first patient and a 3.0-cm mass near the uncinate process in the second (Figure 1).

EUS was carried out in both patients. The first patient had a septated cystic lesion 4.6 × 2.7 cm in size in the pancreatic head (Figure 2a). The second patient had a septated cystic mass measuring 3.7 × 2.6 cm near the uncinate process (Figure 2b). The rest of the examination was normal in both patients (Figure 3). At FNA, a thin, milky fluid was aspirated in both cases (Figure 4). Laboratory analysis revealed a

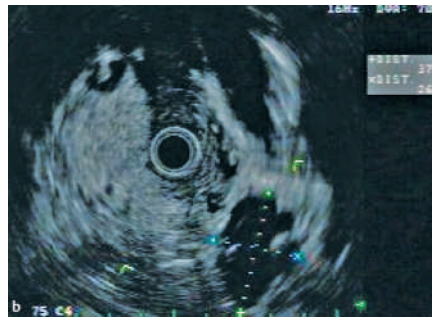
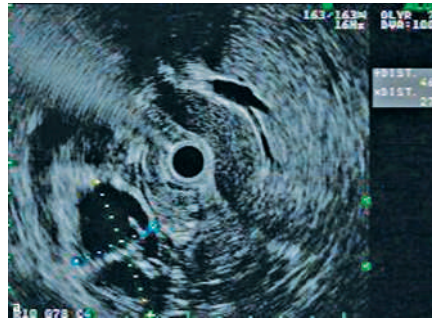


Figure 2 Radial endoscopic ultrasound images from patient 1 (a) and patient 2 (b), showing measurements of the septated cyst (cross-hairs).

triglyceride level of > 5000 mg/dl in both cases. No disease progression or complications such as cyst infections were evident after a follow-up period of 5 months. In both cases, the chylous aspirate with a markedly elevated triglyceride level was diagnostic.

Lymphangiomas are rare benign neoplasms that can arise in most organs. The largest reported series, including 10 surgical cases, suggested that they represent 0.2% of pancreatic neoplasms. Many patients have been asymptomatic, with the lesion being discovered incidentally on imaging studies [1].

Most previously reported cases have been diagnosed at surgery, since imaging examinations have not been sufficient to exclude malignancy. With EUS-FNA, many cystic neoplasms can now be reliably diagnosed without surgery [2–5]. Since lymphangiomas are generally believed to be benign, nonsurgical management may be reasonable if a definitive diagnosis is

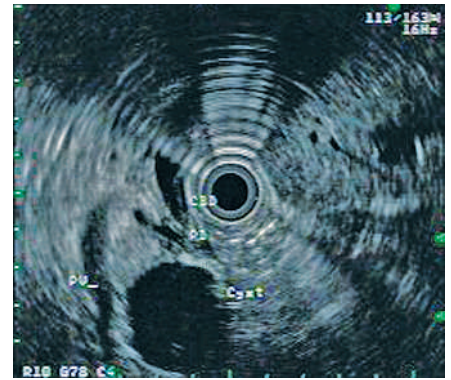


Figure 3 Radial endoscopic ultrasound image from patient 1, showing the cyst in relation to the common bile duct (CBD), pancreatic duct (PD) and portal vein (PV).

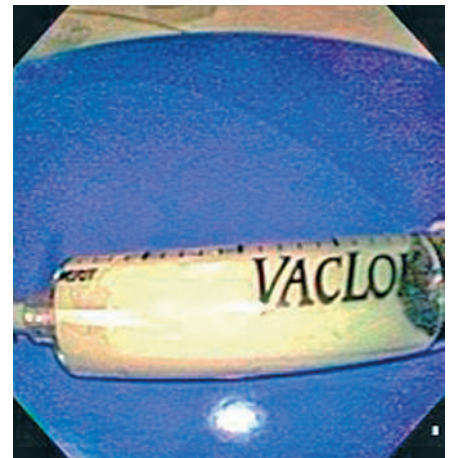


Figure 4 A syringe filled with the chylous cyst aspirate.

made [1]. In the absence of significant symptoms attributable to the cystic lymphangioma, surgical resection may be unnecessary.

Endoscopy\_UCTN\_Code\_CCL\_1AF\_2AZ\_3AB

**B. Applebaum, J. T. Cunningham**

Section of Gastroenterology,  
University of Arizona Medical Center,  
Tucson, Arizona, USA.

## References

- <sup>1</sup> Paal E, Thompson LD, Heffess CS. A clinicopathologic and immunohistochemical study of ten pancreatic lymphangiomas and a review of the literature. *Cancer* 1998; 82: 2150–2158
- <sup>2</sup> Brugge WR. The role of EUS in the diagnosis of cystic lesions of the pancreas. *Gastrointest Endosc* 2000; 52 (6 Suppl): S18–S22
- <sup>3</sup> Hernandez LV, Mishra G, Forsmark C et al. Role of endoscopic ultrasound (EUS) and EUS-guided fine needle aspiration in the diagnosis and treatment of cystic lesions of the pancreas. *Pancreas* 2002; 25: 222–228
- <sup>4</sup> Jacobson BC, Baron TH, Adler DG et al. ASGE guideline: the role of endoscopy in the diagnosis and the management of cystic lesions and inflammatory fluid collections of the pancreas. *Gastrointest Endosc* 2005; 61: 363–370
- <sup>5</sup> Song MH, Lee SK, Kim MH et al. EUS in the evaluation of pancreatic cystic lesions. *Gastrointest Endosc* 2003; 57: 891–896

## Corresponding author

### **B. Applebaum, M. D.**

Section of Gastroenterology  
University of Arizona Medical Center  
1501 N. Campbell Avenue  
Tucson, Arizona 85724

USA

Fax: +1-520-626-0826

E-mail: [bapplebaum@hotmail.com](mailto:bapplebaum@hotmail.com)