

A 55-year-old woman with a positive fecal occult blood test was investigated by upper endoscopy. This revealed an esophageal submucosal tumor, 18 cm from the incisors (Figure 1a). Endoscopic ultrasound confirmed that this lesion, which measured 10 mm × 10 mm, arose from the muscularis mucosae and involved only the submucosa. The tumor was removed by endoscopic resection, with initial marking by electrocautery and submucosal injection of 15 ml of normal saline mixed with indigo carmine and epinephrine. An endoscopic submucosal dissection was performed using a triangular-tip knife, an insulated-tip knife, and a Hook knife (Olympus, Tokyo, Japan) (Figure 1b, Video 1). Histological examination of the tumor confirmed that it was a leiomyoma. The patient was discharged from hospital 3 days after the endoscopic submucosal dissection procedure and she had an uneventful recovery.

Indications for surgical resection of esophageal leiomyoma include unremitting symptoms, increasing tumor size, ulceration of the tumor, or the need for a histological diagnosis [1,2]. Recently, thoracoscopy-assisted enucleation has proved feasible and this is associated with less postoperative pain and faster recovery [3].

Asymptomatic esophageal leiomyomas are commonly managed by observation. Endoscopic mucosal resection has recently emerged as an option for treating small esophageal leiomyomas, but the usefulness of conventional endoscopic mucosal resection is limited by the risk of perforation because the lifting effect of the submucosal injection may be hindered by the submucosal nature of the tumor [4]. An advantage of endoscopic submucosal dissection is that the dissection is performed within the submucosal plane, and enucleation of the tumor does not rely on lifting it. In our experience, different endoscopic knives suit different steps of the dissection: Hook and triangular-tip knives can be used for sharp submucosal

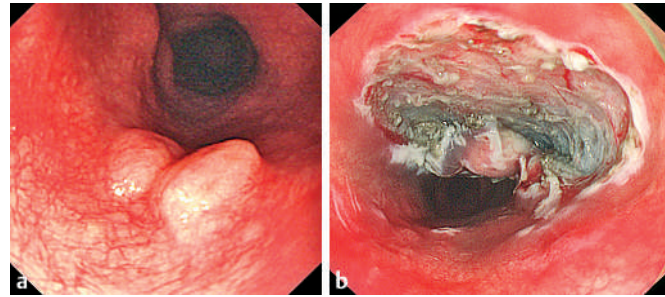


Figure 1 Esophageal leiomyoma, seen before treatment (a) and after near-complete resection using an endoscopic submucosal dissection technique (b).

dissection, while an insulated-tip knife is employed for circumferential incision. The magnifying power of the endoscope clearly identified the plane of dissection, which allowed for precise dissection and hemostasis. Our experience concurred with the findings of a study that showed that submucosal tumors arising from the muscularis mucosae can be removed completely by endoscopic submucosal dissection [5]. Although our patient was asymptomatic, endoscopic enucleation of her tumor offered her the advantage of having it safely resected without morbidity and before it become symptomatic.

Endoscopy_UCTN_Code_TTT_1AO_2AG

P. W. Y. Chiu, Y. T. Lee, E. K. W. Ng

Institute of Digestive Disease, The Chinese University of Hong Kong, Hong Kong.

References

- Shim CS, Jung IS. Endoscopic removal of submucosal tumors: preprocedure diagnosis, technical options, and results. *Endoscopy* 2005; 37: 646–654
- Lee LS, Singhal S, Brinster CJ et al. Current management of esophageal leiomyoma. *J Am Coll Surg* 2004; 198: 136–146
- Von Rahden BH, Stein HJ, Feussner H, Siewert JR. Enucleation of submucosal tumors of the esophagus: minimally invasive versus open approach. *Surg Endosc* 2004; 18: 924–930
- Chen JB, Kudzu T, Hishikawa E, Miyazaki S. Endoscopic resection of a large esophageal leiomyoma. *Endoscopy* 2002; 34: 428
- Park YS, Park SW, Kim TI et al. Endoscopic enucleation of upper-GI submucosal tumors by using an insulated-tip electro-surgical knife. *Gastrointest Endosc* 2004; 59: 409–415

Corresponding Author

P. W. Y. Chiu, FRCSEd

Division of Upper GI Surgery,
Department of Surgery
Prince of Wales Hospital
The Chinese University of Hong Kong
30–32 Ngan Shing Street
Shatin, N.T.
Hong Kong
Fax: +852-26377974
E-mail: pwychiu@netvigator.com

Video

Endoscopic resection of an esophageal submucosal leiomyoma by endoscopic submucosal dissection, using an insulated-tip knife, a triangular-tip knife, and an Olympus Hook knife.

online content including video sequences viewable at:

www.thieme-connect.de/ejournals/abstract/endoscopy/doi/10.1055/s-2006-944596

DOI: 10.1055/s-2006-944596