

Gallstone ileus occurs almost exclusively in the elderly and accounts for 25% of mechanical small-bowel obstructions in patients over the age of 65, with a mortality of 15% [1]. Surgery has been the treatment of choice, but has a mortality of 12–50% [1–4]. We report here an instance of successful colonoscopic removal of a gallstone obstructing the ileocaecal valve.

A 91-year-old nursing-home resident with dementia was admitted as an emergency with a 1-week history of lethargy, anorexia, constipation and abdominal distension. She was dehydrated and was assessed as having a Glasgow Coma Scale score of 9/15, which improved with fluid resuscitation. Her abdomen was distended and tympanic, with obstructive bowel sounds. There were no palpable masses. She had significant cardiac morbidity, and laboratory tests showed a leucocytosis and an elevated urea concentration at 11.2 mmol/l. A plain abdominal radiograph revealed grossly distended loops of large and small bowel. No air was seen in the biliary tree. No obstructing lesion was found on gastrograffin enema.

She was managed with nasogastric suction and intravenous fluids. Diagnostic colonoscopy was undertaken and a large gallstone was found to be impacted at the ileocaecal valve (Figure [1]). This was snared and retrieved using a large Olympus polypectomy snare. No other pathological abnormality was identified. The patient made a full recovery and was discharged back to the nursing home.

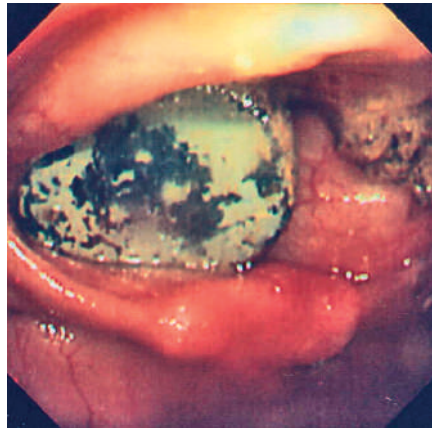


Figure 1 A gallstone impacted at the ileocaecal valve.

Early surgical intervention is the mainstay of treatment for gallstone ileus, regardless of the location of the stone [1]. Surgical treatment comprises enterolithotomy, with or without concurrent fistula repair and cholecystectomy. Both procedures carry significant morbidity and mortality [1–4]. In this case, colonoscopy confirmed the site and cause of small-bowel obstruction and allowed definitive treatment in a patient who was a high surgical risk. Colonoscopic retrieval may be technically possible, carries small risks compared with surgery, and requires a shorter period of rehabilitation.

This paper supports the need for a trial of colonoscopic retrieval of a gallstone impacted at the ileocaecal valve. There is little to be lost from attempting endoscopic removal and, potentially, much to be gained. It is possible that there is a role

for pre-procedure computed tomographic confirmation of the diagnosis.

**Competing interests:** Not declared

**E. L. Murray, M. Collie,  
D. W. Hamer-Hodges**

Department of Colorectal Surgery,  
Western General Hospital, Edinburgh,  
United Kingdom

## References

- 1 Reisner RM, Cohen JR. Gallstone ileus: a review of 1001 reported cases. *Am Surg* 1994; 60: 441–446
- 2 Clavien PA, Richon J, Burgan Set al. Gallstone ileus. *Br J Surg* 1990; 77: 737–742
- 3 Deitz GM, Standage DA, Pinson CW et al. Improving the outcome in gallstone ileus. *Am J Surg* 1986; 151: 572–576
- 4 Illuminati G, Bartolucci T, Leo Get al. Gallstone ileus: report of 23 cases with emphasis on factors affecting survival. *Ital J Surg Sci* 1987; 17: 139–325

## Corresponding Author

**E. L. Murray, M. D.**

The Colorectal Unit (Wards 23 and 24)  
Western General Hospital  
Crewe Road South  
Edinburgh EH4 2XU  
UK

Fax: +44-131-527-1018

E-mail: emmalouisemurray@hotmail.com