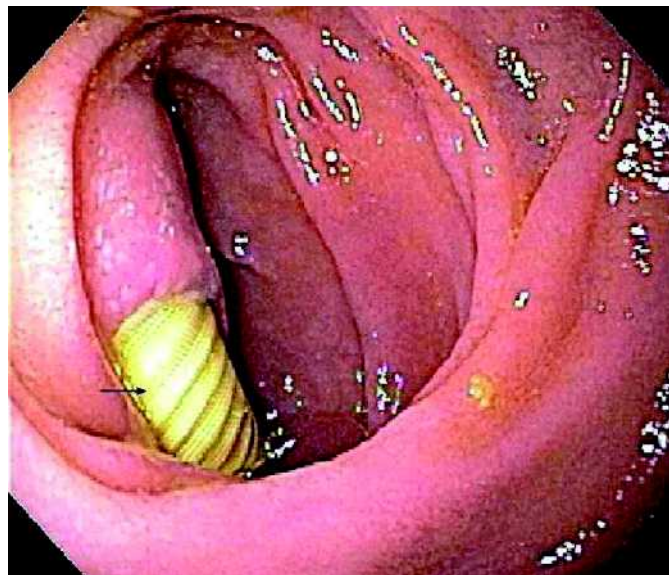


Formation of an Aortic Graft-Enteric Fistula 20 Years after Aortic Graft Placement



T. E. Yusuf, J. E. Clain
Division of Gastroenterology and
Hepatology, Mayo Clinic, Rochester,
Minnesota, USA

Corresponding Author

T. E. Yusuf, M.D.
Division of Gastroenterology
and Hepatology
Mayo Clinic
200 First Street sw
Rochester, Minnesota
55905 USA
Fax: +1-507-266-3939
E-mail: yusuf.tony@mayo.edu

Figure 1 An 80-year-old man presented with epigastric discomfort, melena, fever, and chills. He had a history of an aorto-bifemoral graft, placed for the treatment of claudication about 20 years prior to this presentation. Computed tomography of the abdomen revealed an air bubble in the graft and a small fluid collection around the graft. Blood cultures were positive for bacteremia and fungemia. Upper endoscopy was performed and the appearance was diagnostic of an aorto-duodenal fistula. A large area of ulceration which exposed a section of Dacron graft (arrow) was identified in the third portion of the duodenum. There was no evidence of active bleeding. The patient underwent excision of the infected aortic graft and repair of the aorto-enteric fistula, and was doing well at his 6-month follow-up.