

Endoscopic submucosal dissection techniques using an insulated-tip knife (IT knife) were introduced several years ago to allow en-bloc resection of early gastric cancers, since histological evaluations are essential in order to assess the risk of lymph-node metastasis [1,2]. However, the technique requires special skills and involves a prolonged procedural time. We have therefore developed a new type of dissection knife, termed the "hood-knife" (patent pending in Japan), which only requires a simple technique.

The novel, semitransparent hood covers one-third of the tip circumference, facilitating endoscopic hemostatic procedures while simultaneously allowing irrigation of the bleeding site [3]. The hood is easily placed on the tip of the endoscope, al-

though it has to be fitted to the right side of the endoscope. The hood-knife is made by drilling another side hole, in addition to the hole for the irrigation tube, into the cap portion of a transparent end hood. A snare forceps is glued to the exterior surface over the hole and attached using short tubes on the inside of the cap (Figure 1).

The endoscopic submucosal dissection procedure using the hood-knife is carried out as follows (Figure 2). Marking dots are made on the circumference of the target tumor, outlining the margin of the lesion. After injection of a saline solution into the submucosa, the tumor is separated from the surrounding normal mucosa by complete incision around the lesion using the IT knife. The endoscope is then with-

drawn, and the hood-knife is placed on the tip and fixed with tape. A grasping forceps is passed through the accessory channel, and the lesion is pushed away from the muscle layer. Submucosal exfoliation is carried out by sliding the hood-knife with coagulation current along the muscle layer. With this method, endoscopic submucosal dissection can be safely and easily carried out under direct vision.

Three specimens were resected in an animal model (pigs). The average diameter of the resected specimens was 30 mm, and the average time required for endoscopic dissection was 3 min. Another advantage of the hood-knife is that endoscopic submucosal dissection and endoscopic hemostasis can be carried out while simultaneously applying adequate irrigation [3–5].

K. Kume, M. Yamasaki, K. Kanda, I. Yoshikawa, M. Otsuki
Third Dept. of Internal Medicine, School of Medicine, University of Occupational and Environmental Health, Kitakyushu, Fukuoka, Japan.


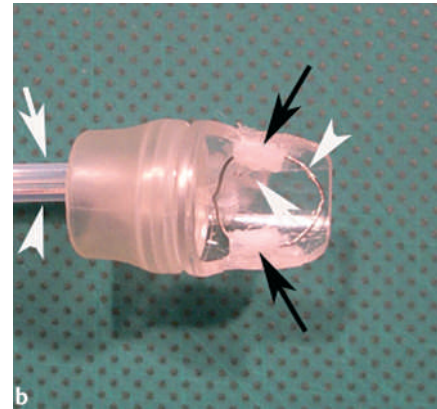
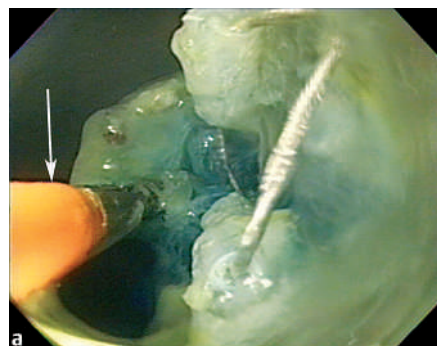


Figure 1 The irrigation hood-knife: **a** side view, **b** view from below. The irrigation tube (white arrow) and snare (arrowhead) are



glued to the exterior surface over the hole, and the snare is attached using short tubes (black arrows) on the inside of the cap.



b Schematic representation of the endoscopic submucosal dissection procedure using the hood-knife.

Figure 2 **a** Endoscopic submucosal dissection using the hood-knife; a grasping forceps (arrow) pushes the lesion away from the muscle layer, and the hood-knife is slid with coagulation current along the muscle layer.

References

- ¹ Ono H, Kondo H, Gotoda Tet al. Endoscopic mucosal resection for treatment of early gastric cancer. *Gut* 2001; 48: 225–229
- ² Ohkuwa M, Hosokawa K, Boku Net al. New endoscopic treatment for intramucosal gastric tumors using an insulated-tip diathermic knife. *Endoscopy* 2001; 33: 221–226
- ³ Kume K, Yamasaki M, Yamasaki Tet al. Endoscopic hemostatic treatment under irrigation for upper GI hemorrhage: a comparison of one third and total circumference transparent end hoods. *Gastrointest Endosc* 2004; 59: 712–716
- ⁴ Kume K, Yoshikawa I, Otsuki M. Endoscopic treatment of upper GI hemorrhage with a novel irrigating hood attached to the endoscope. *Gastrointest Endosc* 2003; 57: 732–735
- ⁵ Kume K, Yamasaki M, Kubo Ket al. EMR of upper GI lesions when using a novel soft, irrigation, prelooped hood. *Gastrointest Endosc* 2004; 60: 124–128

Corresponding Author

M. Otsuki, M.D., Ph.D.

Third Dept. of Internal Medicine,
School of Medicine

University of Occupational and
Environmental Health

1–1, Iseigaoka, Yahatanishi-ku
Kitakyushu 807-8555

Japan

Fax: +81-93-692-0107

E-mail: mac-otsk@med.uoeh-u.ac.jp