Ischemic Gastropathy: Leopard Skin in the Stomach

T. C. Lee[1], J. T. Lin[1], C. W. Liang[2], H.-P. Wang[3]

[1] Department of Internal Medicine, National Taiwan University Hospital, Taipei, Taiwan

[2] Department of Pathology, National Taiwan University Hospital, Taipei, Taiwan

[3] Department of Emergency Medicine, National Taiwan University Hospital, Taipei, Taiwan

Corresponding Author

H.-P. Wang, M.D.

Departments of Emergency Medicine
National Taiwan University Hospital
No. 7, Chung-Shan South Road
Taipei
Taiwan
Fax: +886-2-23223150
E-mail: whp@ha.mc.ntu.edu.tw

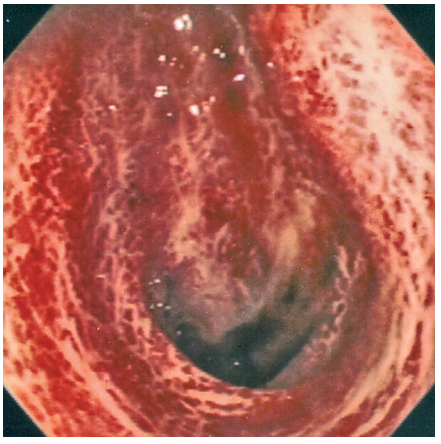

Figure **1** A 73-year-old woman was admitted to the emergency department for a cardiac arrest that occurred outside the hospital. After resuscitation, upper gastrointestinal endoscopy was performed because of gastrointestinal bleeding. The endoscopic view of the gastric antrum showed numerous reddish patches of subepithelial hemorrhage, mimicking the appearance of leopard skin.

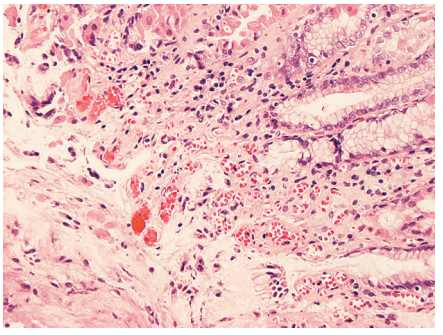

Figure **2** Pathological examination of the biopsy specimen revealed ischemic gastropathy. Note the cytoplasmic vacuolization and hyalinization of the degenerative epithelial cells. The paucity of inflammatory cells distinguished the ischemia from infection (hematoxylin & eosin stain; original magnification × 100).

This document was downloaded for personal use only. Unauthorized distribution is strictly prohibited.